



## Radiographic Evaluation of Osteogenesis Time in the Wing Bones of Myna (*Acridotheres tristis*)

Hashem Mansouri<sup>1</sup>, Saman Ahani<sup>2</sup>, Siamak Alizadeh<sup>3\*</sup>

<sup>1</sup>Graduate of Veterinary Medicine, Faculty of Veterinary Medicine, Kazerun Branch, Islamic Azad University, Kazerun, Iran

<sup>2</sup>Graduate of Veterinary Medicine, Faculty of Veterinary Medicine, Karaj Branch, Islamic Azad University, Karaj, Iran

<sup>3</sup>Department of Clinical Sciences, Faculty of Veterinary Medicine, Urmia Branch, Islamic Azad University, Urmia, Iran

Received: 17/Sep/2022

Revised: 27/Oct/2022

Accepted: 04/Nov/2022

### Abstract

**Background and aim:** The aim of this study was to evaluate the time of osteogenesis and development pectoral girdle elements, wing and the ossification centers of these regions in post-hatching time in common myna (*Acridotheres tristis*) with by using radiographic method.

**Materials and Methods:** This descriptive study is done on myna after hatching. Fourteen myna (7 male and 7 female) were reared in similar and standard conditions and radiography was done once every 7 days to up 90 days of wing bones. The assigned technique including processing the radiographic image with normal radiography film.

**Results:** Differentiation of the wing in myna starts with the appearance of centers of undeveloped cartilages in humerus diaphysis, radius, and ulna at the end of the first week, and also carpal regions in the beginning of the third week. The growth sequence in humerus and radius, ulna and carpus, metacarpus, and digits are observed in various stages. Maximum growth is related to the maximum cartilaginous activity and ossification stages. Humerus keeps its growth connection constant with the length of the whole wing skeleton, although its growth scale lessens from the end of the third week. In adult specimens the formula of the digits of the fore limb is usually 2:2:1 but it sometimes decreases to 1:2:1.

**Conclusion:** Based on this study, osteogenesis time in the wing bones of myna is 70 days after hatching and some of the many contrasts that were mentioned about other birds can be evaluated and compared and also, there was no significant difference between male and female myna birds in relation to osteogenesis time.

**Keywords:** Myna, Osteogenesis time, Radiography, Wing bones

**Cite this article as:** Hashem Mansouri, Saman Ahani, Siamak Alizadeh. Radiographic Evaluation of osteogenesis time in the wing bones of Myna (*Acridotheres tristis*). J Altern Vet Med. 2022; 5(14): 808-816.

### \* Corresponding Author

Department of Clinical Sciences, Faculty of Veterinary Medicine, Urmia Branch,  
Islamic Azad University, Urmia, Iran.

E-mail: [s\\_alizadeh01@yahoo.com](mailto:s_alizadeh01@yahoo.com), Orcid: <https://orcid.org/0000-0003-1112-7026>

## Introduction

Numerous studies are done about the forming of the ossification centers in birds before and after hatching (Maddin *et al.*, 2016; Alvarez *et al.*, 2022; Adamopoulos *et al.*, 2021). There are studies about common myna (*Acridotheres tristis*) before hatching and embryonic period but there is no fundamental investigation on the time and place of the ossification centers after hatching and there is little information about the wing skeleton in myna, which is rapidly changing to a proper bird for many research studies like toxicology and teratology (Grarock *et al.*, 2014; Grarock *et al.*, 2012; Prasad & Christi, 2014).

The anatomy of the wing of the birds and the patterns related to it are widely studied and there have been many attempts for the analysis of the involved elements in controlling the differentiation of it (John *et al.*, 2017; Kadhim *et al.*, 2013). Most of these studies, apart from some exceptions, are mostly about domestic poultry (*Gallus domesticus*) (Pohlmann *et al.*, 2017). As there is a lot of information about the development of skeleton in *Gallus domesticus*, we can consider them to compare with the results of this study on myna (Butler, 2015). Such a comparison between two species that are categorized under different order of galliformes is of great importance. The development of long bones in poultry from the histogenesis process of all the wing skeleton part to the differentiation of mesenchymal cells to chondroblasts and osteoblasts are described with a lot of details (Oznurlu *et al.*, 2016). Lansdown's study has surveyed the differentiation of mesenchymal cells to chondroblasts and osteoblasts and the development method of cartilage and bone structure in humerus and wing skeleton considering the age of the myna (*Acridotheres tristis*) embryo (Lansdown, 1969).

Hogg's study that was done on *Gallus domesticus* showed the time of appearance of ossification centers after hatching in different parts of the wing skeleton (Hogg, 1980; Barbut, 2016). The aim of this study was to determine the age of physical maturity and to evaluate the formation process of ossification centers after hatching in the myna wing skeleton using radiological methods and since there is no basic study on the time of the formation of ossification centers in myna and there is little information about the wing skeleton, this fundamental study was conducted in this field.

## Materials and Methods

This descriptive study is done on myna after hatching. Fourteen myna (*Acridotheres tristis*) (7 male and 7 female) were kept from day one to the end of the studies under the same conditions and were reared under the standard conditions related to food, temperature, humidity and light. The techniques employed include processing the radiographic stereotype with normal radiography film. The radiography machine was Dean 44 X-Ray machine, Hitachi Medical Corporation, Tokyo, Japan, KVp 40-110 and mAs 0.1-200 and focal-film distance 100 cm. The applied KVp and mAs were considered as 40 and 3.5, respectively. For radiography of the specimens the lateral and ventrodorsal position were used. Preparing the radiographs was on the specified times which means radiography was done twice on the first week (first and seventh days) and then once at the end of second, third, fourth, fifth, sixth, seventh, eighth, and ninth week and after the ninth week until the full maturity stage and completion of skeletogenesis radiography of specimens was done every two weeks. Study of the centers on the specimens continues until 90 days after hatching. Animal Research Ethics Committee of Veterinary Faculty of Islamic Azad University approved all experimental procedures (No: 0506215279).

## Results

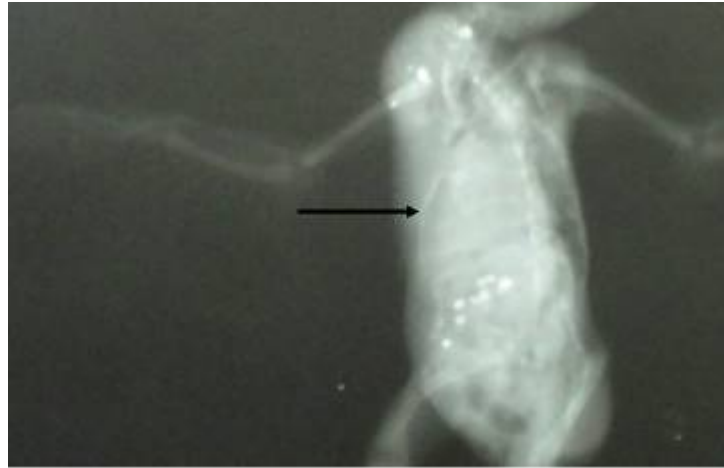
### The time of ossification in pectoral girdle and sternum

Scapula, Clavicle, Coracoid and Humerus: on the first day after hatching this bone was not observed in any specimen because it was cartilaginous and was observed in all specimens after day seven.

Sternum: It was not observed until the seventh days in any specimen. After day 14 it was observed in all specimens (Figure 1). The ossification starting time of pectoral girdle is shown in table 1.

### Ossification time of wing bones

Head of humerus: It was not observed in any of the specimens until day 35. It was observed in day 42 in more than 90% and after day 49 in all specimens (Figure 2). Dorsal tubercle of humerus: It was not observed in any of the specimens until day 49.



**Figure 1.** Ventrodorsal radiograph of myna. Sternum observed in all specimens (arrow).14 days.

Area	Days after hatching												
	1	7	14	21	28	35	42	49	56	63	70	77	84
Scapula	-	+	+	+	+	+	+	+	+	+	+	+	+
Clavicle	-	+	+	+	+	+	+	+	+	+	+	+	+
Coracoid	-	-	+	+	+	+	+	+	+	+	+	+	+
Sternum	-	-	+	+	+	+	+	+	+	+	+	+	+

**Table 1.** Time of pectoral girdle ossifying.

It was observed in day 56 in more than 90% and after day 56 in all specimens. Ventral tubercle of humerus: It was not observed in any of the specimens until day 42. It was observed in day 49 in 80%, in day 56 in 95% and after day 63 in all specimens. Diaphysis of humerus: On the first day after hatching this bone was not observed in any specimen because it was cartilaginous and was observed in all specimens after day seven. Ventral epicondyle of humerus: It was not observed in any of the specimens until day 42. It was observed in day 49 in 60%, in day 56 in 85%, in day 63 in 95%, and after day 70 in all specimens.

Dorsal epicondyle of humerus: It was not observed in any of the specimens until day 42. It was observed in day 49 in 60%, in day 56 in 85%, in day 63 in 95%, and after day 70 in all specimens (Figure 3).

Radius: On the first day after hatching this bone was not observed in any specimen because it was cartilaginous and was observed in all specimens after day seven.

Ulna: On the first day after hatching this bone was not observed in any specimen because it was

cartilaginous and was observed in all specimens after day seven.

Radial carpal bone: It was not observed until the seventh day in any specimen. After day 14 it was observed in more than 95% and after day 21 in all specimens.

Ulnar carpal bone: It was not observed until the seventh day in any specimen. After day 14 it was observed in more than 95% and after day 28 in all specimens (Figure 4).

Metacarp I: It was not observed in any of the specimens until day 21. It was observed in day 28 in 50%, in day 35 in 80%, in day 42 in 95%, and after day 49 in all specimens.

Metacarp II: On the first day after hatching this bone was not observed in any specimen because it was cartilaginous and was observed in all specimens after day seven.

Metacarp III: On the first day after hatching this bone was not observed in any specimen because it was cartilaginous and was observed in all specimens after day seven (Figure 5).

Proximal and distal phalanx of digit II: On the first day after hatching these bones were not observed in any specimen because they were cartilaginous and

after day 7 they were observed as joined together. After day 21 they were separable.

Proximal and distal phalanx of digit III: On the first day after hatching these bones were not observed in any specimen because they were cartilaginous and after day 7 they were observed as joined together. After day 21 they were separable.

Phalanx of digit IV: On the first day after hatching this bone was not observed in any specimen because it was cartilaginous and after day 7 it was observed as

joined to proximal of digit III. After day 21 these two were separable. The ossification starting time of wing bones is shown in table 2.

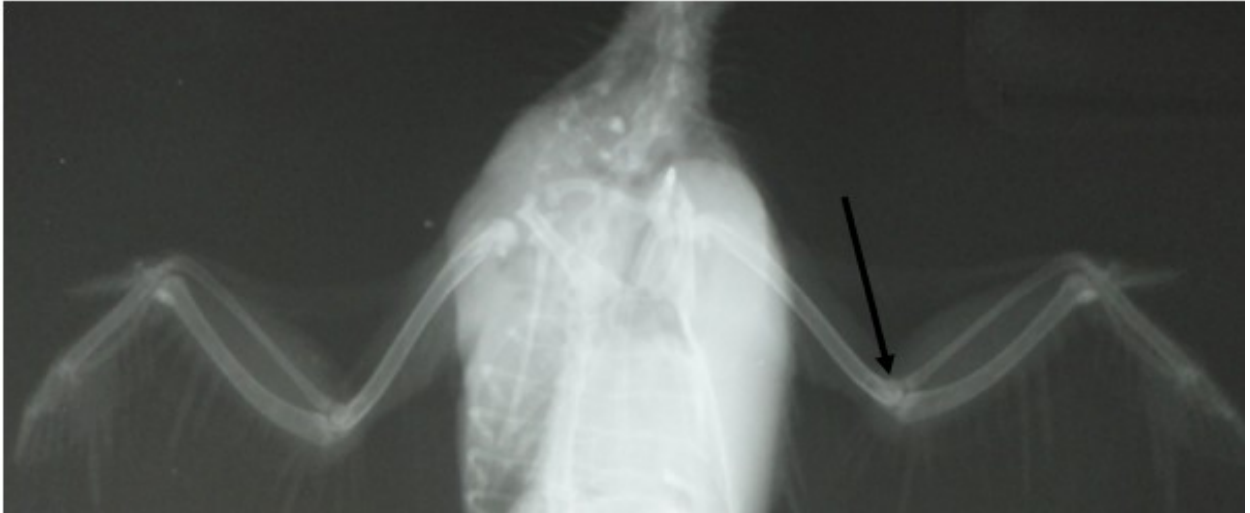
According to this study seems, time which could be as the completion of the ossification process and the formation of all parts pectoral limb girdle and wing is 70 days after hatching (Figure 6).

Area	Days after hatching												
	1	7	14	21	28	35	42	49	56	63	70	77	84
Head of humerus	-	-	-	-	-	+	+	+	+	+	+	+	+
Dorsal tubercle of humerus	-	-	-	-	-	-	-	-	-	+	+	+	+
Ventral tubercle of humerus	-	-	-	-	-	-	-	-	-	+	+	+	+
Diaphysis of humerus	-	+	+	+	+	+	+	+	+	+	+	+	+
Ventral epicondyle of humerus	-	-	-	-	-	-	-	-	-	-	+	+	+
Dorsal epicondyle of humerus	-	-	-	-	-	-	-	-	-	-	+	+	+
Radius	-	+	+	+	+	+	+	+	+	+	+	+	+
Ulna	-	+	+	+	+	+	+	+	+	+	+	+	+
Radial carpal bone	-	-	-	+	+	+	+	+	+	+	+	+	+
Ulnar carpal bone	-	-	-	+	+	+	+	+	+	+	+	+	+
Metacarpus I	-	-	-	-	-	-	-	+	+	+	+	+	+
Metacarpus II	-	+	+	+	+	+	+	+	+	+	+	+	+
Metacarpus III	-	+	+	+	+	+	+	+	+	+	+	+	+
Proximal phalanx of digit II	-	+	+	+	+	+	+	+	+	+	+	+	+
Distal phalanx of digit II	-	+	+	+	+	+	+	+	+	+	+	+	+
Proximal phalanx of digit III	-	+	+	+	+	+	+	+	+	+	+	+	+
Distal phalanx of digit III	-	+	+	+	+	+	+	+	+	+	+	+	+
Phalanx of digit IV	-	+	+	+	+	+	+	+	+	+	+	+	+

Table 2. Time of wing skeleton ossifying.

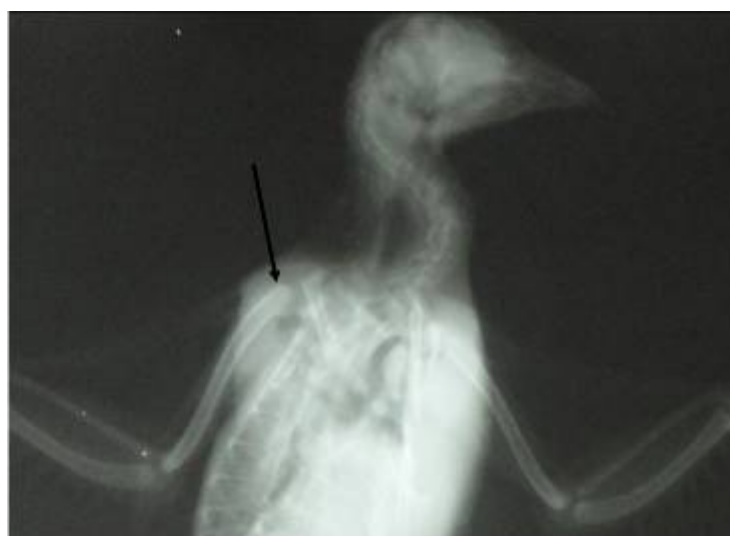

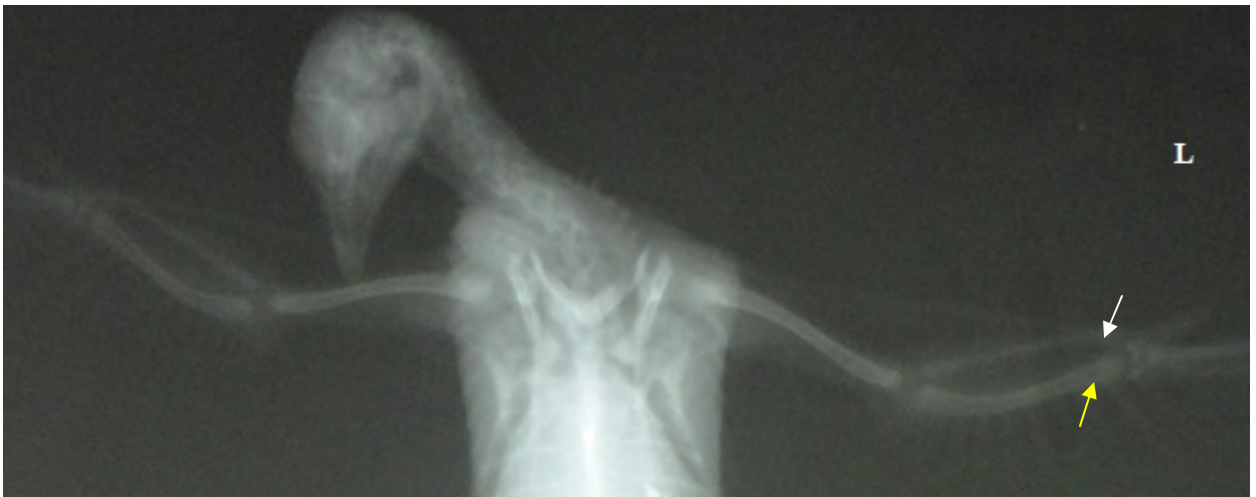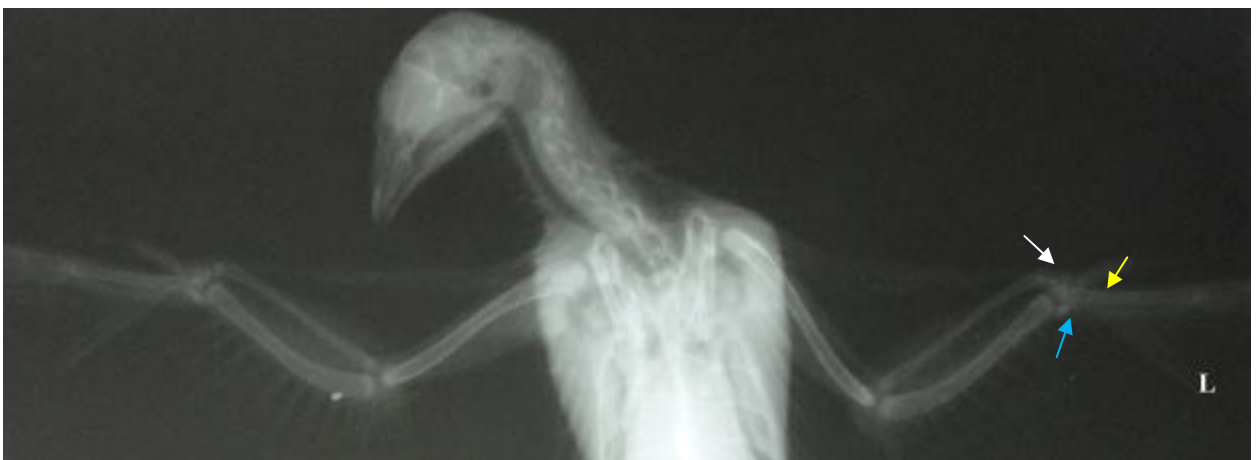
Figure 2. Ventrrodorsal radiograph of myna. The arrow indicates head of humerus. 42 days.



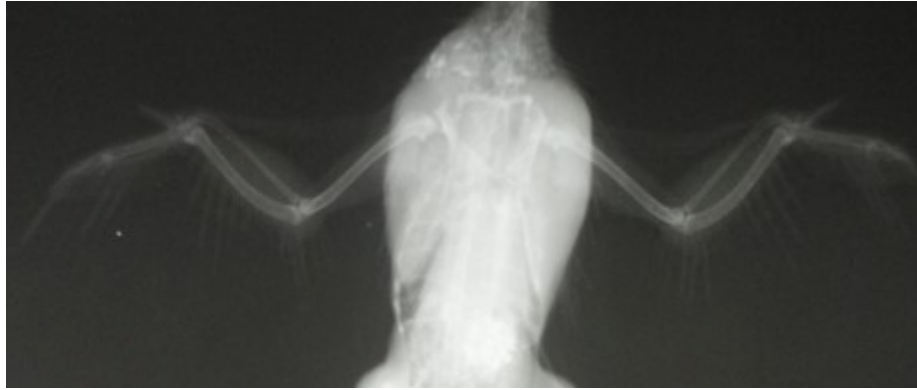
**Figure 3.** Ventrodorsal radiograph of myna. The arrow indicates dorsal epicondyle of humerus. 63 days.



**Figure 4.** Radial carpal bone (white arrow) and ulnar carpal bone (yellow arrow) in VD view of myna. 28 days. L: left.



**Figure 5.** Metacarpal bone: Metacarp I (white arrow), Metacarp II (yellow arrow), Metacarp III (blue arrow) in VD view of myna. 28 days. L: left.



**Figure 6.** The completion of the ossification process in pectoral girdle and limb.70 days.

### Discussion

Because of the widespread of the information in the field of skeleton development in chick we try to compare the development of wing skeleton in myna with *Gallus domesticus* in this study. In adult birds the differences observed in the formula were interesting as it illuminated the contrasts in past studies. Several studies have been performed in respect of skeletal development in the birds such as *Gallus domesticus* but there is not any published evidence regarding skeletal development in myna hence, we try to compare the development of wing skeleton in this bird with *Gallus domesticus* in this study.

Galiano and Lapointe cite a study of osteogenesis bone process on the endosteal bone of pigeons (*Columbia livia domestica*) surfaces by histology, autoradiography, microradiography, and electron microscopy indicated that medullary bone growth was associated with a rapid and dramatic increase in total plasma calcium (Galiano & Lapointe, 2019). In another study was accomplished by John et al., on the ossification centers of the pectoral girdle and wing skeleton of the myna, different osteogenesis times identified in some bones such as the humerus, radius, ulna, carpal and metacarpal bones. This study is consistent with our study, except for the timing of phalanx bones (John et al., 2017). Crosta et al., investigated the time of ossification centers of the myna vertebrae, ribs, and sternum and announced that the sternum osteogenesis time was immediately after hatching, whereas in our study, this was on the 14<sup>th</sup> day after hatching (Crosta et al., 2018), which was different from our study. In another study, Garrock et al., reported the first onset of primary extraction centers in myna on the ninth day of incubation. This

study showed different growth patterns between the long and short bones of the wings and legs (Garrock et al., 2014). Sanaei reported that the timing of osteogenesis of pigeon bones and compared these times with the process of osteogenesis of myna bones, and showed that the process of bone osteogenesis in these two birds was closely related (Sanaei, 2011). The general formula in digit ossification in birds is 1:2:1 (Maxwell & Larsson, 2009; O'Connor et al., 2011). But the formula observed in this study was usually 2:2:1 that was observed in further studies of past researchers about chicken (Welten, 2005). It seems that only Bellairs et al., uses this formula specifically for *Gallus domesticus* and it was confirmed in few birds studied in this investigation (Bellairs et al., 1960).

On the other hand, the formula 2:3:2 is also discussed for *Gallus domesticus* that was not seen in the specimens of this study and that it may be mentioned for the inferior row of phalanges that exists as an extra and in embryo but it is synthesized with the proximal row later. For adult birds the formula 2:3:2 is also mentioned. Maybe the fuse time of carpus and manus is after hatching that it is in contrast with the findings of past researchers (Alizadeh et al., 2014).

According to Pourlis and Antonopoulos about 1 or 2 months after hatching the chicken metacarpus ossifies which is at the end of the first week for metacarpus III and IV and end of the seventh week for metacarpus II in myna in all specimens (Pourlis & Antonopoulos, 2011). Also, according to Mitgutsch et al., about 1 or 2 months after hatching the chicken metacarpus ossifies which is at the end of the 7<sup>th</sup> day for metacarpus III and IV and the end of the seventh week for metacarpus II in myna in all specimens. It

seems that less attention is paid for the development of the digits in birds, however, it can be said that the first center of ossification in digits area of wing skeleton in myna is about the end of the first week (Mitgutsch *et al.*, 2011). It is probable that the development of skeletal in distal portions of myna wing happens around the end of the first week with special mention of development in metacarpus, and digit area. Such a speed can have little result in the development of the carpus area.

The formation process of pectoral limb girdle and wing bones in myna (*Acridotheres tristis*) and chicken have little differences but the growth pattern is similar in both. In this study, the ossification of the long bones of the wing was begun after 7<sup>th</sup> day and the ossification was finished at the end of 63<sup>th</sup> day. The growth plate was not observed in the pectoral limb girdle and wing bones. According to this study seems, time which could be as the completion of the ossification process and the formation of all parts pectoral limb girdle and wing is 70 days after hatching (Figure 6).

### Conclusion

The formation process of pectoral limb and wing bones skeleton elements in common myna (*Acridotheres tristis*) and chicken have little differences but the growth pattern is identical in both. Ossification of the long bones in wing area beginning at the end of the first week and at the end of the ninth week all the elements in these bones are formed. The obvious point was that there are no secondary ossification centers in pectoral girdle and limb. The best time to mention as the completion of the ossification process and the formation of all skeleton elements in pectoral girdle and limb is 70 days after hatching.

### Acknowledgments

This study was supported by Faculty of Veterinary Medicine, Urmia Branch, Islamic Azad University, Urmia, Iran.

### Conflict of Interest

The authors declared no conflict of interest.

### Ethical Statement

This study does not present any ethical concerns.

### References

- Adamopoulos K., Koutsouris D., Zaravinos A. and Lambrou GI. Gravitational influence on human living systems and the evolution of species on earth. *Molecules*, 2021; 26(9): 2784.
- Alizadeh S., Veshkini A. and Gilanpour H. Study of the ossification centers and skeletal development of pectoral limb in quail after hatching. *Adv Environ Biol*, 2014; 2216-2223.
- Alvarez F., Arena M., Auteri D., Binaglia M., Castoldi AF. and Chiusolo A. Conclusion on pesticides peer review, 2022.
- Barbut S. Poultry products processing: an industry guide: CRC press, 2016.
- Bellairs ADA. and Jenkin CR. The skeleton of birds. In *Biology and Comparative Physiology of Birds*, vol. 1 (ed. A. J. Marshall). New York and London Academic Press, 1960; PP: 241-300.
- Butler DJ. Plan for the eradication of myna birds from kiribati, 2015; 31.
- Crosta L., Melillo A. and Schnitzer P. Basic radiography. *BSAVA Manual of Avian Practice*. BSAVA Library, 2018; 269-85.
- Galiano E. and Lapointe M. Mechanical, chemical, structural, and radiological changes in pigeon bone, associated with the dietary intake of nickel recovery slag. *J Env Sci Pollut Res*, 2019; 5(2): 348-51.
- Garock K., Tidemann CR., Wood J. and Lindenmayer DB. Is it benign or is it a pariah? Empirical evidence for the impact of the common myna (*Acridotheres tristis*) on Australian birds. *PLoS One*, 2012; 7(7): 40622.
- Garock K., Tidemann CR., Wood JT. and Lindenmayer DB. Are invasive species drivers of native species decline or passengers of habitat modification? A case study of the impact of the common myna (*Acridotheres tristis*) on Australian bird species. *Austral Ecol*, 2014; 39(1): 106-14.
- Hogg D. A re-investigation of the ossification centers in the avian skeleton at and after hatching. *J Anat*, 1980; 130(4): 725-743.

- John M., Khan M., Quadir A., Choudhury A., Baba M. and Dar F. Sternal morphometry of common myna (*Acridotheres tristis*), Himalayan bulbul (*Pyconotus leucogenys*) and house sparrow (*Passer domesticus*). *Appl Biol Res*, 2017; 19(1): 237-40.
- Kadhim KK., Hameed AT. and Abass TA. Histomorphological and histochemical observations of the Common Myna (*Acridotheres tristis*) tongue. *Int Sch Res Notices*, 2013; 980465.
- Lansdown AG. An investigation of the development of the wing skeleton in the myna (*Coturnix c. japonica*). *J Anat*, 1969; 105(1): 103-114.
- Maddin HC., Piekarski N., Sefton EM. and Hanken J. Homology of the cranial vault in birds: new insights based on embryonic fate-mapping and character analysis. *R Soc Open Sci*, 2016; 3: 250-265.
- Maxwell EE. and Larsson HC. Comparative ossification sequence and skeletal development of the postcranium of palaeognathous birds (Aves: Palaeognathae). *Zool J Linn Soc*, 2009; 157: 169-196.
- O'Connor JK., Chiappe LM. and Bell A. Pre-modern birds: avian divergences in the Mesozoic. *Living dinosaurs: the evolutionary history of modern birds*, 2011; PP: 39-114.
- Oznurlu Y., Sur E., Ozaydin T., Celik I. and Uluisik D. Histological and histochemical evaluations on the effects of high incubation temperature on the embryonic development of tibial growth plate in broiler chickens. *Microsc Res Tech*, 2016; 79: 106-110.
- Pohlmann A., Starick E., Harder T., Grund C., Höper D. and Globig A. Outbreaks among wild birds and domestic poultry caused by reassorted influenza A (H5N8) clade 2.3. 4.4 viruses, Germany, 2016. *Emerg Infect Dis*, 2017; 23: 633.
- Pourlis A. and Antonopoulos J. The ossification of the pectoral girdle and wing skeleton of the myna (*Acridotheres tristis*). *Anat Histol Embryol*, 2011; 40: 219-225.
- Prasad RR. and Christi K. Physical method of control on common myna (*Acridotheres tristis*) in Sigatoka-Fiji Islands. *Int J Eng Sci*, 2014; 1813-2319.
- Sanaei MR. Evaluation of osteogenic potential of demineralized bone matrix in Pigeon (*Columba Livia Gmelin*). *Universiti Putra Malaysia*, 2011.
- Mitgutsch C, Wimmer C, Sánchez-Villagra MR, Hahnloser R, Schneider RA. Timing of ossification in duck, quail, and zebra finch: intraspecific variation, heterochronies, and life history evolution. *Zoolog Sci*, 2011; 28(7): 491-500.
- Welten MC., Verbeek FJ., Meijer AH. and Richardson MK. Gene expression and digit homology in the chicken embryo wing. *Evol Dev*, 2005; 7: 18-28.





## ارزیابی زمان استئوژنز استخوان‌های بال مینا (*Acridotheres tristis*) با روش رادیوگرافی

هاشم منصوری<sup>۱</sup>، سامان آهنی<sup>۲</sup>، سیامک علیزاده<sup>۳\*</sup>

<sup>۱</sup>دانش آموخته دامپزشکی، دانشکده دامپزشکی، واحد کازرون، دانشگاه آزاد اسلامی، کازرون، ایران

<sup>۲</sup>دانش آموخته دامپزشکی، دانشکده دامپزشکی، واحد کرج، دانشگاه آزاد اسلامی، کرج، ایران

<sup>۳</sup>گروه علوم بالینی، دانشکده دامپزشکی، واحد ارومیه، دانشگاه آزاد اسلامی، ارومیه، ایران

تاریخ دریافت: ۱۴۰۱/۰۶/۲۶ اصلاح نهایی: ۱۴۰۱/۰۸/۰۵ تاریخ پذیرش: ۱۴۰۱/۰۸/۱۳

### چکیده

**زمینه و هدف:** هدف از این مطالعه ارزیابی زمان استئوژنز و توسعه استخوان‌های کمر بند سینه‌ای، بال و مراکز استخوان‌سازی این نواحی در زمان پس از هچینگ در مینای معمولی (*Acridotheres tristis*) با استفاده از روش رادیوگرافی بود.

**مواد و روش‌ها:** این مطالعه توصیفی بر روی مینا پس از جوجه ریزی انجام شد. ۱۴ مینا (۷ نر و ۷ ماده) در شرایط همسان و استاندارد پرورش یافتند و هر ۷ روز یکبار تا ۹۰ روزگی رادیوگرافی از استخوان‌های بال انجام شد. تکنیک به کار رفته شامل تهیه کلیشه‌های رادیوگرافی با فیلم نرمال رادیوگرافی بود.

**یافته‌ها:** تمایز اسکلت بال در مینا با ظاهر شدن مراکز از غضروف‌های نابالغ در دیاپیز استخوان بازو، زندزیرین و زندزیرین در پایان هفته اول و نیز نواحی میج دست در شروع هفته سوم آغاز گردید. توالی رشد در استخوان بازو، زندزیرین، زندزیرین، میج دست، قلم‌های دست و انگشتان در طی مراحل مختلفی دیده شد. حداکثر رشد به میزان فعالیت غضروفی و مراحل استخوانی شدن مرتبط بود. استخوان بازو ارتباط رشد خود را با طول تمام بال و اسکلت بال ثابت نگاه می‌دارد اگرچه از پایان هفته سوم میزان رشد آن تقلیل یافت. در نمونه‌های بالغ فرمول بندهای انگشتان ناحیه حرکتی قدامی به طور معمول ۲:۲:۱ بود اما گاهی نیز به فرمول ۱:۲:۱ کاهش می‌یافت.

**نتیجه‌گیری:** بر اساس نتایج این مطالعه زمان استئوژنز استخوان‌های بال مینا در روز ۷۰ بعد از هچینگ اتفاق می‌افتد و مغایرت‌های فراوانی که در گذشته در مورد این پرنده ذکر شده بوده را می‌توان مورد ارزیابی و مقایسه قرار داد همچنین در رابطه با زمان استئوژنز تفاوت معنی‌داری در بین پرنده‌های مینای نر و ماده مشاهده نشد.

**واژه‌های کلیدی:** مینا، زمان استئوژنز، رادیولوژی، استخوان‌های بال

هاشم منصوری، سامان آهنی، سیامک علیزاده. ارزیابی زمان استئوژنز استخوان‌های بال مینا (*Acridotheres tristis*) با روش رادیوگرافی. مجله طب دامپزشکی جایگزین.

۱۴۰۱؛ ۵ (۱۴): ۸۰۸-۸۱۶

\* نویسنده مسئول: گروه علوم بالینی، دانشکده دامپزشکی، واحد ارومیه، دانشگاه آزاد اسلامی، ارومیه، ایران.