



Ultrasonographic Findings of Renal Lymphosarcoma in German Shepherd Dogs

Saman Ahani¹, Foad Sadi^{2*}

¹Doctor of Veterinary Medicine, Karaj Branch, Islamic Azad University, Karaj, Iran

²Department of Clinical Sciences, Mahabad Branch, Islamic Azad University, Mahabad, Iran

Received: 24/Jun/2023

Revised: 23/Sep/2023

Accepted: 12/Oct/2023

Abstract

Background and aim: Lymphosarcoma is a common form of neoplasia in dogs and usually affects both kidneys. In the current retrospective study, ultrasonographic findings of lymphosarcoma in five German Shepherd dogs and the role of fine needle aspiration were evaluated.

Materials and Methods: Five German Shepherd dogs (three Females and two males) with renal failure symptoms underwent ultrasonographic examination. The levels of cytosolic Thymidine kinase (TK1) and Lactate dehydrogenase (LDH) were also measured in all cases and were compared with those of five healthy German Shepherd dogs. In order to confirm the diagnosis, Renal Fine Needle Aspiration (FNA) was applied and the results were reported and compared with previous studies.

Results: In this study, pelvic dilatation was observed in all dogs. In four cases, corticomedullary junctions were not well-demarcated. Also, renal enlargement and deformity were reported in four and three cases respectively. Hypoechoic lesions were seen in three cases. Due to the severity of both clinical and ultrasonographic signs of four dogs, renal fine needle aspiration was performed and lymphosarcoma was confirmed at the initial examination. However, because of less severe manifestation of one case, FNA was not performed initially. With deterioration of clinicopathologic signs, however, this case was reexamined after 30 days and lymphosarcoma was confirmed through FNA.

Conclusion: The findings indicated that the ultrasonographic features of renal lymphosarcoma in German Shepherd dogs may be minimal in its preliminary stages, so it is advisable that further examination be performed at intervals shorter than 30 days. Furthermore, in order to confirm the suspicion, ultrasound-guided FNA is invaluable.

Keywords: *Lymphosarcoma, Kidney, Dog, Ultrasonography, Biopsy*

Cite this article as: Saman Ahani, Foad Sadi. Ultrasonographic findings of renal lymphosarcoma in German Shepherd dogs. J Altern Vet Med. 2023; 6(18): 1067-1073.

* Corresponding Author

Department of Clinical Sciences, Mahabad Branch, Islamic Azad University, Mahabad, Iran.

E-mail: foadsadi@yahoo.com, Orcid: <https://orcid.org/0000-0001-4717-3332>



Introduction

Lymphosarcoma is one of the most commonly encountered malignancies in different breeds of dogs and affects lymphocytes (a type of blood cell) and lymphoid tissues (Jaroensong *et al.*, 2022). Lymphoid tissue is normally present in different organs - including lymph nodes, spleen, liver, gastrointestinal tract, and bone marrow (Marsilio *et al.*, 2019). Depending on the site primarily affected, lymphosarcoma could be further subcategorized into different groups. In many cases, the kidneys are the primary sites of involvement (Mandara *et al.*, 2022). Dogs with lymphosarcoma usually manifest signs of renal failure such as polyuria, polydipsia, loss of appetite, and vomiting. In order to make a definite diagnosis, biopsy or cytology samples, using percutaneous renal fine needle aspiration (FNA), are usually sufficient; however, depending on the site where the tumor is lodged, sometimes the procedure becomes more invasive and a surgical biopsy may be needed to extract adequate amount of tissue to confirm the diagnosis (Sumping *et al.*, 2020). An examination of a canine patient suspected of lymphosarcoma often encompasses a complete blood count (CBC), a biochemistry profile and urinalysis. An x-ray study for checking thoracic lymph node enlargement, effusions, and signs of metastases as well as abdominal ultrasonography are also routinely applied (Tanaka *et al.*, 2022). Through an abdominal ultrasonography the examiner can study the liver, spleen, abdominal lymph nodes and parts of intestinal wall (Burt *et al.*, 2018; Łobaczewski *et al.*, 2022). Studying other abdominal organs could help the sonographer to rule out other organs infiltration, and could assure the examiner of the absence of the other nodal involvement. Even though the role of ultrasonography is of great value in determining malignancies, the performance of renal FNA is necessary to confirm suspicion (Marsilio *et al.*, 2019). Hence, along with more conventional studies, renal FNA, under the guidance of ultrasonography, is of great value.

Tumor markers are measured for different purposes when malignancies are suspected. These markers are released into blood stream and they help the examiner realize the type, extent, and prognosis of neoplasia (Negm *et al.*, 2022; Matharoo *et al.*, 2008). Two markers which are usually evaluated in cases of sarcoma in canine patients are Thymidine Kinase and Lactate Dehydrogenase. Thymidine kinase (TK) is known as a cytoplasmic enzyme involved in phosphorylation of deoxythymidine to deoxythymidine-monophosphate as a major part of pyrimidine synthesis. TK comprises cytosolic (TK1) and mitochondrial (TK2) forms. TK1 is directly related to the cell proliferation activity. Thus, its

activity increases in malignancies (Mella *et al.*, 2020). In canine patients, measuring TK has been assigned to diagnose and to stage lymphoma and lymphosarcoma prior to manifestation of clinically detectable symptoms (Taylor *et al.*, 2013). Lactate dehydrogenase (LDH) is also a cytoplasmic cellular enzyme and its exact metabolic role is not still clearly known. However, this enzyme could be an indicator of disturbances of cellular integrity in cases of pathological condition (Klein *et al.*, 2020).

The purpose of this retrospective study was to provide information regarding the ultrasonographic findings in canine renal lymphosarcoma using ultrasound-guided fine needle aspiration technique. At the time of the present study, little published information was found in this regard.

Materials and Methods

In this retrospective study, five German Shepherd dogs (3 females and 2 males) with an average age of nine years and symptoms of renal failure, including PU/PD, vomiting, and also azotemia, were examined with ultrasound. The ultrasound machine used in this study was EUB-8500- Hitachi, Tokyo, Japan. According to the size of the patients a linear probe with a frequency ranging from 5 to 9 MHz was applied. All animals in this study were required to have at least one of the following ultrasonographic abnormalities: Parenchymal lesions (unilateral or bilateral), Renal enlargement (unilateral or bilateral), Deformed renal architecture (unilateral or bilateral), Pyelectasia (unilateral or bilateral) and Degree of pyelectasia for each kidney (defined as grade I, up to 0.5 cm in width; grade II, between 0.5 and 1.5 cm; and grade III, more than 1.5 cm), Loss of corticomedullary distinction (unilateral or bilateral), Hypoechoic nodules (defined as round well-defined lesions less than 0.5 cm in diameter), Hypoechoic masses (defined as well-defined lesions greater than 0.5 cm), Hypoechoic areas (defined as hypoechoic lesions with unsharp demarcation), Hyperechoic lesions, and Perirenal and/or subcapsular lesions (Taylor *et al.*, 2014).

After confirmation of both clinical and ultrasonographic signs, 5-7 ml of jugular blood was sampled from each case. Also, the same amount of blood was acquired from five healthy German Shepherd dogs in order to define normal values of cytosolic Thymidine kinase (TK1) and Lactate dehydrogenase (LDH) levels and to compare with those of neoplastic dogs. All dogs were fasted for 12 hours prior to blood sampling. The serum was acquired using a centrifuge machine for 30 minutes immediately after sampling. The TK1 activity was measured by OwjAzmaPlast Co., Tehran, Iran, based on Elisa technique. Serum LDH activity was detected

using Spectrophotometric method, Spekol, 1500 - Pars Azmoon Co, Tehran, Iran.

In order to acquire cytologic specimens, dogs were sedated under the supervision of clinicians. This followed by aseptic preparation of the skin after closely clipping the hair of the region. The footprint of transducer and coupling gel used for this procedure were sterile. A 22-gauge was inserted percutaneously under real-time ultrasound guidance. The path of needle insertion was through the least tissue resistance directing at the kidney cortex. The needle is then moved to and fro with a gentle negative pressure. Next, on a microscopic slide, the needle contents were ejected and were prepared using standard histological preparation technique (McAloney *et al.*, 2018).

The statistical analysis was performed using SPSS version 22, Test and T-test (Independent Samples Test). $P < 0.05$ was assigned as mode significance.

Results

Abdominal ultrasonography revealed renal lesions in four cases - three of which bilaterally and one unilaterally. Renal deformity was also seen in three cases; it was bilateral in two cases and unilateral in one case. Four animals represented renomegaly; in three dogs both kidneys were enlarged. With regards to echogenicity, three cases showed hypoechoic lesions, including hypoechoic nodules, masses, and areas. In two cases, hypoechoic lesions were bilateral and in one case the lesion was seen in one kidney (Fig.1). Other abdominal ultrasound findings included

enlarged lymph nodes - including mesenteric, splenic, medial iliac, paraaortic, renal, and hepatic lymph nodes. The thickness of gall bladder and small intestinal wall was increased. The external layer of gall bladder wall was hypoechoic and the internal layer was hyperechoic. Mild ascites, and mild retroperitoneal fluid were found. Pancreatic and perirenal fat appeared respectively hypoechoic and hyperechoic.

In two cases, grade I pyelectasia, mild renomegaly and local loss of corticomedullary distinction was seen. In one case, grade I and II pyelectasia, as well as a focal loss of corticomedullary junction was observed. Another case presented grade I pyelectasia and loss of corticomedullary distinction and hyperechoic areas in medulla. Case five merely showed a mild bilateral renal enlargement, compatible with nonspecific nephropathy in the dog. However, the persistence of erythrocytosis and azotemia in this dog, led to a further examination thirty days later. In the second renal examination, marked bilateral renomegaly, general loss of corticomedullary, and grade III pyelectasia was seen (Fig. 2). The renal fine needle aspirates of the left kidney confirmed lymphosarcoma in this case.

Compared with healthy dogs, significant increase in TK1 and LDH level was observed in the group with malignancy; in affected animals, the levels of LDH and TK1 were reported as high as approximately 32 and 10 times of normal animals respectively (Table 1).

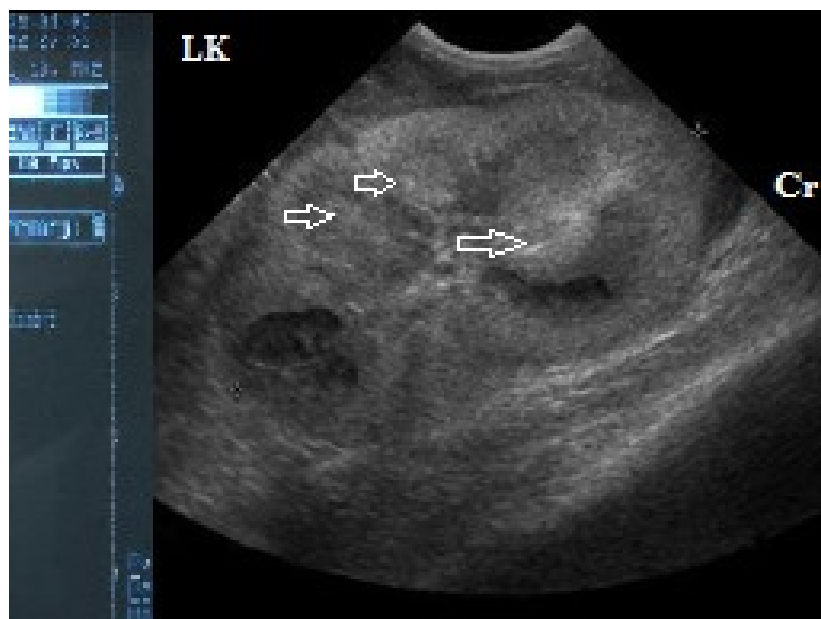


Figure 1. A sagittal sonogram of the left kidney in a German Shepherd dog with renal lymphosarcoma. Hypoechoic nodules are observed in renal parenchymal tissue (arrows). Lk: Left kidney, Cr: Cranial.

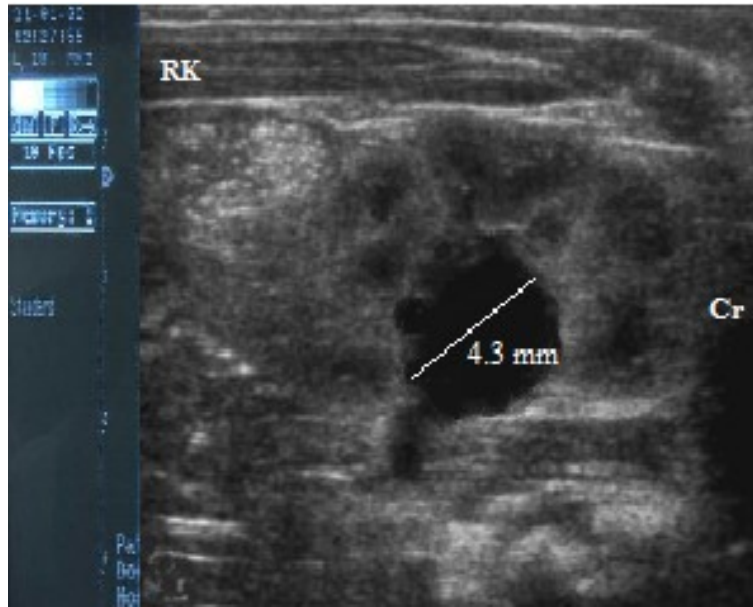


Figure 2. Transverse ultrasound plane of the right kidney in a German Shepherd dog with renal lymphosarcoma. The line illustrates grade III renal pelvic dilatation (Pyelectasia). RK: Right kidney, Cr: Cranial.

Parameters	Lymphosarcoma Group	Normal Group	p Value
TK1 (U/l)	12.08±1.05	†1.16 ± 0.03	P≤0.000
LDH (U/l)	3241.64 ± 68.82	†98.25 ± 9.59	P≤0.000

Table 1: Mean Serum TK1 and LDH levels in lymphosarcoma and normal groups. Figures are expressed as Mean ± SD. † as superscript denotes significant difference in comparison with normal group. (P< 0.01).

Discussion

In this study, all dogs had symptoms and signs such as lethargy, vomiting, diarrhea, and azotemia; Lascelles et al, (2018) showed a significant correlation between the mentioned findings and renal malignancies. Hypoechoic nodules have been commonly seen with histocytic sarcoma tumors (Locke et al., 2016), but in the present study hypoechoic nodules was also seen in lymphosarcoma. Hemangiocarcinoma and carcinoma may cause unilateral hypoechoic renal nodules or masses (Monaghan et al., 2018), while in this study two cases showed these features bilaterally. In humans, renal lymphoma lesions are usually bilateral and this is the opposite of carcinomas which is often unilateral (Moch et al., 2016; Komohara et al., 2014); the former is relatively compatible with two cases in this study. Pelvic dilatation, renal enlargement, and loss of corticomedullary distinction were observed in cases in this study. These ultrasonographic findings were similar to those reported in previous reports of renal lymphoma in dogs (Griffin et al., 2021; Williams et al., 2021).

A significant correlation has been reported between increased kidney size and renal lymphoma in dogs. It is stated that renal neoplasia, depending on the stage of development, can cause mild to severe renal enlargement (Apostoloulou et al., 2021). Owing to the variability of renal size in different breeds of dogs, in this study, mild enlargement of kidney in one case was considered negligible, and no fine needle aspiration (FNA) was performed at the first examination. However, after thirty days with deterioration of clinical findings, the same case was examined and diagnosed with lymphosarcoma through FNA. One probability is that in this case an early stage of disease had been developed but was not recognized on initial presentation based on the current measuring standards. Therefore, precise standards for each breed seem to be necessary in order to prevent subtle changes in size to be overlooked. Also, repeating ultrasound examination and FNA could be useful in dogs presented with initially mild or nonspecific renal conditions in intervals more frequent than 30 days.

Four dogs were presented with pyelectasia. Among different causes of grade I pyelectasia, fluid

therapy is considered to be the most prevalent factor; since administered fluid increases the glomerular filtration rate, its excessive amount could dilate the renal pelvis. This ultrasonographic finding is nonspecific and caution is needed when dealing with this sign (Walter *et al.*, 2016). In this study fluid therapy had been administered in four cases; however, this medication is not a probable cause for pyelectasia since grade II and III of pyelectasia were also observed in two cases - which are considered anomalous. Pyelectasia is frequently reported in dogs with renal lymphoma (Walter *et al.*, 2016). The findings of this study may indicate that pyelectasia could also be a reliable ultrasonographic finding in dogs with lymphosarcoma. In veterinary medicine, however, data relating the severity of pyelectasia and specific abnormalities are limited; besides, standards for measuring the pelvic dilation are not sufficient which render this method of diagnosis unreliable at current time. In the current study, an attempt was made to examine a suggested scoring system considering the width of renal pelvic size.

As no lymphatic tissue is found in parenchyma of a normal kidney, pathologists have suggested that the source of renal lymphosarcoma is the perirenal fat or chronic inflammations within which lymphocytes accumulate in the region, and subsequently neoplastic transformations follow the process (Puccini *et al.*, 2020).

Renomegaly, without contour distortion, is the most common renal sign in humans with Burkitt's lymphosarcoma in both primary and multicentric forms. This anomaly is due to diffuse infiltration of neoplastic cells (Puccini *et al.*, 2020). Four cases in this study presented with renomegaly. In two of them, signs of deformity were also detectable which could be related to the different stages of malignancy. In the veterinary medicine, the role of fine-needle aspiration is well-recognized for the evaluation of many types of neoplasia (Puccini *et al.*, 2020). Findings of the current study supported the merits of this technique for suspected cancers, and showed that FNA is needed to be applied even in the presence of mild changes. In this study, percutaneous biopsy sampling and histopathology provided definitive diagnoses, and no detectable iatrogenic complications occurred following this procedure.

Conclusion

According to the results of this study, ultrasonographic findings of renal lymphosarcoma in German Shepherd dogs may not be significant initially, so frequent examination and renal fine needle aspirates should be applied to confirm the suspicion.

Conflict of Interest

None declared.

References

- Apostoloulou E., Vlemmas I., pardali D., Adamama-Moraitou K., Poutahidis T. and Brellou G. Bilateral renal large B cell lymphoma in dog. *Vet Sci*, 2021; 8(11): 258-263.
- Burt JR., Torosdagli N., Khosravan N., RaviPrakash H., Mortazi A. and Tissavirasingham F. Deep learning beyond cats and dogs: recent advances in diagnosing breast cancer with deep neural networks. *Brit J Radiol*, 2018; 91(10): 201-220.
- Griffin S. Canine abdominal ultrasonography: What's normal-What's abnormal-Abdominal lymph nodes, peritoneal cavity and aorta. *J Vet Med Surg*, 2021; 23(9): 835-849.
- Jaroensong T., Piamwaree J. and Sattasathuchana P. Effects of chemotherapy on hematological parameters and CD4+/CD8+ ratio in dogs with mediastinal lymphoma and seropositive to canine leukemia virus. *Animals*, 2022; 12(3): 223-233.
- Klein R., Nagy O., Tothova C. and Chovanova F. Cincical and diagnostic significance of Lactate dehydrogenase and its isoenzymes in animals. *Vet Med Int*, 2020; 5(1): 134-145.
- Komohara Y., Jinushi M. and Takeya M. Clinical significance of macrophage heterogeneity in human malignant tumors. *Cancer Sci*, 2014; 10(5): 1-8.
- Lascelles B., Monnet E., Liptak J., Johnson J. and Dernell W. Surgical treatment of right-sided renal lymphoma with invasion of the caudal vena cava. *J Small Anim Pract*, 2018; 44(3): 135-148.
- Łobaczewski A., Czopowicz M., Moroz A., Mickiewicz M., Sapierzyński R. and Tarka S. Integrated basic heart and lung ultrasound examination for the differentiation between bacterial pneumonia and lung neoplasm in dogs: a new diagnostic algorithm. *Animals*, 2022; 12(9): 1154-1163.
- Locke JE. and Barber LG. Comparative aspects and clinical outcomes of canine renal hemangiosarcoma. *J Vet Intern Med*, 2016; 20(4): 962-967.
- Mandara MT., Domini A. and Giglia G. Canine lymphoma of the nervous system: Immunophenotype and anatomical patterns in 24 cases. *Front Vet Sci*, 2022;9 (1): 1-10.

- Marsilio S., Pilla R., Sarawichitr B., Chow B., Hill SL. and Ackermann MR. Characterization of the fecal microbiome in dogs with inflammatory bowel disease or alimentary small cell lymphoma. *Sci Rep*, 2019; 9(1): 1-11.
- Marsilio S., Pilla R., Sarawichitr B., Chow B., Hill SL. and Ackermann MR. Characterization of the fecal microbiome in dogs with inflammatory bowel disease or alimentary small cell lymphoma. *Sci Rep*, 2019; 9(1): 1-11.
- Matharoo-Ball B., Miles AK., Creaser CS., Ball G. and Rees R. Serum biomarker profiling in cancer studies: a question of standardisation. *Vet Comp Oncol*, 2008; 6(1): 224-247.
- McAloney C., Sharkey L., Feeney D., Seelig D., Avery A. and Jessen C. Evaluation of the diagnostic utility of cytologic examination of renal fine-needle aspirates from dogs and the use of ultrasonographic features to inform cytologic diagnosis. *Vet Clin North Am Exot Anim Pract*, 2018; 25(10): 1247-1256.
- Mella SL., Cardy TJ., Volk HA. and De Decker S. Clinical reasoning in canine spinal disease: Useful combination of clinical information. *J Vet Med Surg*, 2020; 22(6): 521-530.
- Moch H., Cubilla AL., Humphrey PA., Reuter VE. and Ulbright TM. The 2016 WHO classification of tumors of the urinary system and male genital organs—part A: renal, penile, and testicular tumours. *Eur. Urol*, 2016; 70(2): 93-105.
- Monaghan K., Nolan B. and Labato M. Canine acute kidney injury: Pathophysiology, etiology and etiology-specific management considerations. *J Feline Med Surg*, 2012;14(11):775-84.
- Negm RS., Verma M. and Srivastava S. The promise of biomarkers in cancer screening and detection. *Trends Mol. Med*, 2002; 8(2): 288-293.
- Puccini Leoni F., Pelligra T., Citi S., Marchetti V., Gori E. and Puccinelli C. Ultrasonographic monitoring in 38 dogs with clinically suspected acute pancreatitis. *Vet Sci*, 2020; 7(4): 180-188.
- Sumping J., Maddox T., Killick D. and Mortier J. Diagnostic accuracy of ultrasonography to detect hepatic and splenic lymphomatous infiltration in cats and dogs. *J Small Anim Pract*, 2020; 63(2): 113-119.
- Tanaka S., Suzuki R., Hirata M., Kagawa Y. and Koyama H. Unusual diagnosis of canine cardiac lymphoma using cardiac needle biopsy. *BMC Vet Res*, 2022; 18(1): 1-6.
- Taylor AJ., Lara-Garcia A. and Benigni L. Ultrasonographic characteristics of canine renal lymphoma. *Vet Radiol Ultrasound*, 2014; 55(1): 441-446.
- Taylor SS., Dodkin S., Papasouliotis K., Evans H., Graham PA. and Belshaw Z. Serum thymidine kinase activity in clinically healthy and diseased dogs: A potential biomarker for lymphoma. *J Feline Med Surg*, 2013; 15(2): 142-147.
- Walter P., Feeney D., Johnston G. and O'Leary T. Ultrasonographic evaluation of renal parenchymal diseases in dogs: 32 cases. *J Am Vet Med Assoc*, 2016; 191(8): 999-1007.
- Williams AG., Hohenhaus AE. and Lamb KE. Incidence and treatment of canine renal lymphoma: 27 cases. *J Feline Med Surg*, 2021; 23 (10): 936-944.



یافته‌های اولتراسونوگرافی لنفوسارکوم کلیه در سگ‌های نژاد ژرمن شپرد

سامان آهنی^۱، فواد سعدی^{۲*}

^۱ دکترای دامپزشکی، واحد کرج، دانشگاه آزاد اسلامی، کرج، ایران

^۲ گروه علوم بالینی، واحد مهاباد، دانشگاه آزاد اسلامی، مهاباد، ایران

تاریخ دریافت: ۱۴۰۲/۰۲/۱۳ اصلاح نهایی: ۱۴۰۲/۰۴/۱۰ تاریخ پذیرش: ۱۴۰۲/۰۴/۲۸

چکیده

زمینه و هدف: لنفوسارکوم به عنوان یکی از تومورهای شایع در سگ‌ها شناخته می‌شود. این نئوپلازی معمولاً کلیه‌ها را به صورت دو طرفه درگیر می‌کند. در این مطالعه گذشته‌نگر، نشانه‌ها و ویژگی‌های اولتراسونوگرافی تومور لنفوسارکوم و همچنین نقش بیوپسی با سوزن نازک مورد ارزیابی قرار گرفت.

مواد و روش‌ها: در این مطالعه پنج سگ ژرمن شپرد (۳ ماده و ۲ نر) با نشانه‌های بالینی درگیری کلیوی به روش سونوگرافی مورد بررسی قرار گرفت. پس از مشاهده نشانه‌های این بیماری مقادیر سرمی تیمیدین کیناز و لاکتات دهیدروژناز نیز در این نمونه‌ها اخذ و با سطوح سرمی این مواد در پنج سگ ژرمن شپرد سالم مقایسه شد. به منظور تشخیص قطعی لنفوسارکوم از کلیه سگ‌های بیمار نمونه بافتی تهیه شد و نتایج بدست آمده مورد مقایسه و تحلیل قرار گرفت.

یافته‌ها: در ارزیابی اولتراسونوگرافی، اتساع لگنچه در همه نمونه‌ها مشاهده گردید. در چهار مورد از این بیماران بخش قشری کلیه از بخش مرکزی آن قابل تمایز نبود. بزرگ شدگی و تغییر شکل کلیه نیز به ترتیب در چهار و سه مورد رویت شد. همچنین در سه مورد کاهش موضعی اکوژنیسته کلیه‌ها مشاهده گردید. اخذ بیوپسی کلیه به روش آسپیراسیون با سوزن نازک در چهار مورد صورت گرفت و در تمام آن‌ها ابتلا به لنفوسارکوما تایید شد. بدلیل کم بودن نشانه‌های بالینی و پیش‌بالینی یکی از نمونه‌ها بررسی بافت‌شناسی در معاینه اولیه صورت نگرفت. اما پس از گذشت ۳۰ روز به دلیل افزایش نشانه‌های بدخیمی در این بیمار نمونه بیوپسی به کمک روش سونوگرافی اخذ و ابتلا به لنفوسارکوم تایید شد.

نتیجه‌گیری: طبق یافته‌های بدست آمده علائم اولتراسونوگرافی مراحل اولیه لنفوسارکوم کلیه در سگ‌های ژرمن شپرد ممکن است چشمگیر نباشد. لذا لازم است در هنگام برخورد با حداقل نشانه‌های سونوگرافی در فواصل کمتر از ۳۰ روز معاینات دیگری انجام شود. همچنین انجام بیوپسی به وسیله آسپیراسیون با سوزن نازک در تشخیص این بسیار بیماری با ارزش می‌باشد.

واژه‌های کلیدی: لنفوسارکوم، کلیه، سگ، اولتراسونوگرافی، بیوپسی

سامان آهنی، فواد سعدی. یافته‌های اولتراسونوگرافی لنفوسارکوم کلیه در سگ‌های نژاد ژرمن شپرد. مجله طب دامپزشکی جایگزین. ۱۴۰۲؛ ۶(۱۸): ۱۰۶۷-۱۰۷۳.

* نویسنده مسئول: گروه علوم بالینی، واحد مهاباد، دانشگاه آزاد اسلامی، مهاباد، ایران.