



The Prevalence and Severity of Foot Pad Dermatitis in Broiler Flocks of Kazerun and Nurabad City, Southwest of Iran

Amir Ashkan Mahjoor*, Mohsen Ghahramani

Department of Pathobiology, Kazerun Branch, Islamic Azad University, Kazerun, Iran

Received: 25/Jun/2024

Revised: 31/Mar/2024

Accepted: 20/Apr/2024

Abstract

Background and aim: Footpad dermatitis (FPD) is a multifactorial condition of inflammation and necrotic lesions on the plantar surface of the footpads of poultry. This study was designed to investigate the prevalence and severity of FPD in broiler flocks of Kazerun and Nurabad city in southwest of Iran.

Materials and Methods: Twenty-nine flocks from eleven farms of broiler chicken farms with flock sizes between 10000 and 22000 were studied in Kazerun and Nurabad city from December 2020 to May 2022 to investigate the prevalence of foot pad dermatitis. The lesions of FPD were scored by macroscopic and microscopic evaluation.

Results: From 4000 chicken inspected in this survey, 897 (%22.42) broilers showed different stages of alterations in the food pad. Type I was detected in 429, Type II was seen in 454 broilers and Type III FPD was detected in 12 broilers.

Conclusion: In this study, the rate of FPD was relatively low, which could be related to proper management, especially proper bedding management, in the studied beef herds.

Keywords: *Foot pad dermatitis, Broiler, Prevalence*

Cite this article as: Amir Ashkan Mahjoor, Mohsen Ghahramani. The prevalence and severity of foot pad dermatitis in broiler flocks of kazerun and Nurabad city, southwest of Iran. J Altern Vet Med. 2024; 7(22): 1333-1342.

* **Corresponding Author**

Department of Pathobiology, Kazerun branch, Islamic Azad University, Kazerun, Iran.

E-mail: amir.mahjoor@gmail.com, Orcid: <https://orcid.org/0000-0002-8351-4933>



Introduction

Economic benefits of increasing body weight in the poultry breeding industry have caused the need for enhanced growth rate that has resulted in different growth of body components such as rapid muscular growth. However, this growth is not accompanied by skeletal development (Yousaf *et al.*, 2021; Shepherd & Fairchild, 2010). Lameness in broilers can reduce bird's activity and cause a variety of issues such as hock burns and chest dirtiness, reduces birds' comfort and affects their functioning including movement and intake of feed and water (Biesek *et al.*, 2023; Yousaf *et al.*, 2021).

Leg diseases are caused by the lack of appropriate diet, good management, ideal lighting and temperature and proper ventilation in combination with inherent weight-bearing features. Infectious, developmental, metabolic and degenerative diseases can also cause leg weakness (Yousaf *et al.*, 2021; Swiatkiewicz *et al.*, 2017; Martrenchar *et al.*, 2002).

Footpad dermatitis (FPD) is a condition that causes inflammation and necrotic lesions on the plantar surface of the footpads in fast-growing broiler chickens and turkeys (Swiatkiewicz *et al.*, 2017; Shepherd & Fairchild, 2010). FPD lesions vary from hyperkeratosis to severe erosions and ulceration and may appear in the first few days of life, but more severe lesions are mostly seen during the fattening period (Freihold *et al.*, 2019). This condition not only causes downgrades and elimination of saleable chicken paws but also negatively affects the performance indices, leg meat yield and increases carcass condemnations (Pagazaurtundua & Warriss, 2006). Furthermore, Footpad dermatitis is a welfare concern for the birds and the presence of severe ulcerations in the foot pads could serve as a gateway for systemic pathogen invasions (Abraham *et al.*, 2021; Zampiga *et al.*, 2019).

Field observations has suggested that birds as young as seven days may show early signs of foot pad inflammation but significant lesions are usually associated in commercial flocks with birds at older ages (Wu & Hocking, 2011).

There are many factors influencing the occurrence and severity of FPD. Among others the type of litter, stocking density, strain crosses, sex and age of the birds, ventilation, housing conditions, lighting program, season or thinning of flocks are considered. However, poor quality litter and wet litter is the most

important cause of FPD (Zampiga *et al.*, 2019; Swiatkiewicz *et al.*, 2017).

Kazerun and Noorabad, are located in the southwest of Fars province on the slopes of Zagros mountains chain in the height of 920 meters above the sea level and have a hot semi-arid climate. They are known as important centers for broiler production and produce an estimated 8000 and 4000 tons of chicken meat annually, respectively (Agricultural statistics of Fars province, 2020)

As chicken paw prices have increased due to demand for high-quality paws to export and local demand in Iran, the aim of the present experiment was to evaluate the prevalence and severity of FPD in Kazerun and Noorabad province and study of macroscopic a microscopic features of this foot alteration in chicken flocks to score the condition in this area.

Materials and Methods

To determine the prevalence and macroscopic and microscopic character of foot pad dermatitis, this study was done in Kazerun and Noorabad province from December 2020 to May 2022. All farms had fairly good fan ventilation system with a standard stocking density. Water and standard diet were provided ad libitum throughout the rearing period in these farms. Litter was supplied in the form of multiple layers of rice shell or saw dust.

Twenty-nine flocks from eleven farms of chicken broiler farms with flock sizes between 10000 and 22000 were involved in this survey. The farms were visited once a week during the rearing phase and one percent of the flock were examined per visit. The foot pads were inspected every week from the first week until slaughter. Every macroscopic score was determined as type I to type III according to the scoring method adapted by Michel *et al.*, (2012). Other chicken's feet that died during the week were also scored (Michel *et al.*, 2012).

If foot pad alterations were covered with litter and feces, they were gently washed with a wet cloth before scoring. The foot pads of both feet were scored. Only the central plantar was scored. If both feet had lesions, the one with the most severe condition was considered. Affected feet were photographed with a digital camera and their type of severity was recorded.

Type I FPD consisted of mild lesions characterized by scale enlargement and erythema this type was histologically identified with hyperplasia and hyperkeratosis of the epidermis, superficial dermal congestion and oedema. Type II had moderate, superficial lesions characterized by hypertrophic and hyperkeratotic scales covered with yellowish to brownish exudate and histologically by a prominent pustular and crust-forming dermatitis. Type III lesions were characterized by a thick dark adherent crust, and histologically by extensive ulceration.

Based on the severity and extent of these three types of lesions a 5-point scale was devised, Score 1 indicated no or type I lesion, scores 2 and 3 indicated 50% or more than 50% of footpad with type II lesion, respectively and scores 4 and 5 indicated less than 50% or more than 50% involvement of footpads with type III lesion, respectively. (Michel *et al.*, 2012).

Results were noted on sheets designed for this study. Feet from the chickens that died during the survey were placed in 10% buffered formalin. Samples from 8 of the flocks in the slaughterhouse were also collected and were sent to pathology laboratory.

In order to observe all of the cutaneous tissue, each foot was cut from the epidermis of the footpad cushion.

The feet were fixed in 10% buffered formalin and were sent to histology (histopathology) lab. The specimens were dehydrated through increasing concentrations of alcohol, cleared with xylene and embedded in paraffin. Sections were cut at 5 μ m, mounted on slide and dried overnight. After dewaxing and rehydration, stained with H&A method and were studied by light microscopy.

Results

From 4000 chicken inspected in this survey, 897 (%22.42) broilers showed different stages of alteration in the food pad. Type I FPD was detected in

429 (%10.72), Type II was seen in 454 (%11.35) broilers and Type III FPD was detected in 12 (%0.3) broilers.

First signs of FPD were seen in week two and the number of the affected broilers were surged true the study.

The foot pads that were classified as Type I showed mild lesions and discoloration with mild hyperkeratosis of the foot pad. Histologically a moderate hyperplasia with hydropic degeneration in the epidermis accompanied with superficial congestion and edema and mild inflammatory cell infiltration was noted. Basal layer of the epidermis remained intact and hyperplasia of the epidermis was occasionally seen (Figure1)

In macroscopic view type II lesions had high-grade hyperkeratosis that sometimes were covered with brownish scab that could be peeled off that usually left an erosion like lesion (Figure 2). In microscopic view thickening and poor keratinization in the stratum corneum, hyperplasia and hyperkeratosis of the epidermis, infiltration of inflammatory cells in the epidermis and congestion of the superficial dermis accompanied by increased infiltration of inflammatory cells in the dermis adjacent to the lesions was noted.

Type III lesions had different levels of ulceration in the foot pad. The skin around the lesion had a reddened edematous appearance (Figure 3). In microscopic view necrotic tissue was abundant on the superficial surface of the lesion merging with a mass of inflammatory cells consisting mainly of heterophils in acute lesions. At the margin of the epidermis and the necrotic plug, heterophils and sometimes bacteria could be seen. Keratin vacuolar cells were often present throughout the epidermis (Figure 4). Epidermis had ulceration and was all or partly replaced by a necrotic eosinophilic mass containing basophilic nuclear debris. Subepithelial and perivascular heterophil infiltration was also noted (Figure 5).

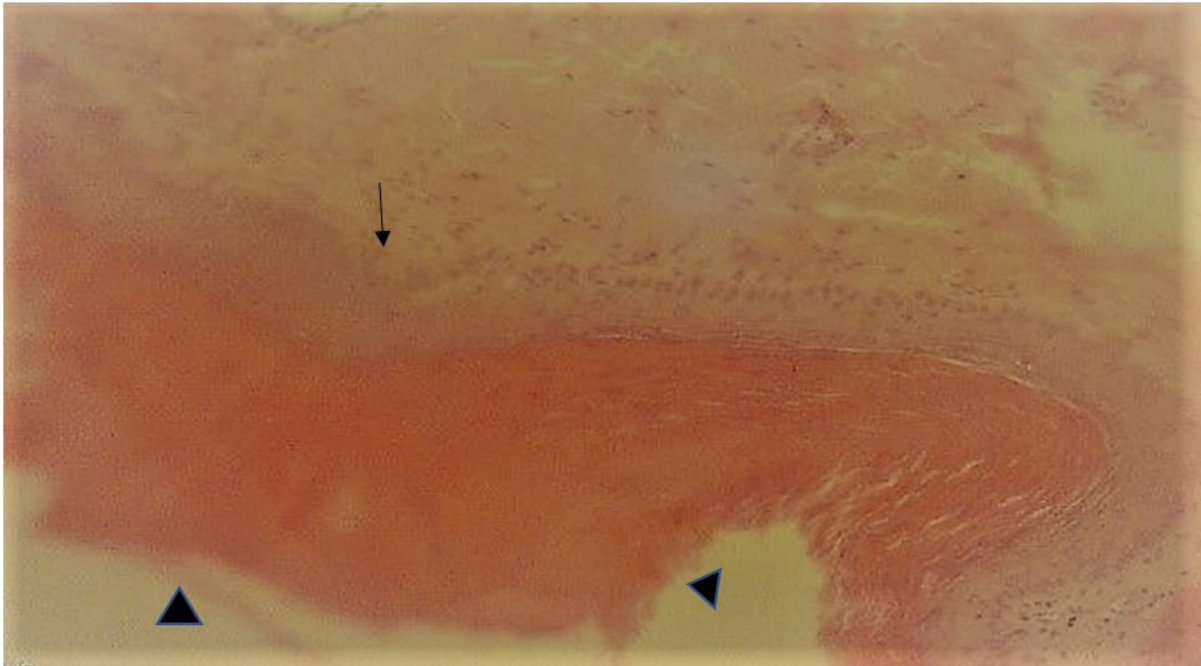


Figure 1. Note the poor keratinization and thickening of the stratum corneum (arrowheads) with mild infiltration of inflammatory cells.



Figure 2. Foot pad dermatitis: hypertrophic and hyperkeratotic scales covered with yellowish exudate, the dirt over the lesion was removed before photography.



Figure 3: Food pad dermatitis score 3: More than 50 percent of the central plantar is affected. Loss of epidermis and a large adherent crust.

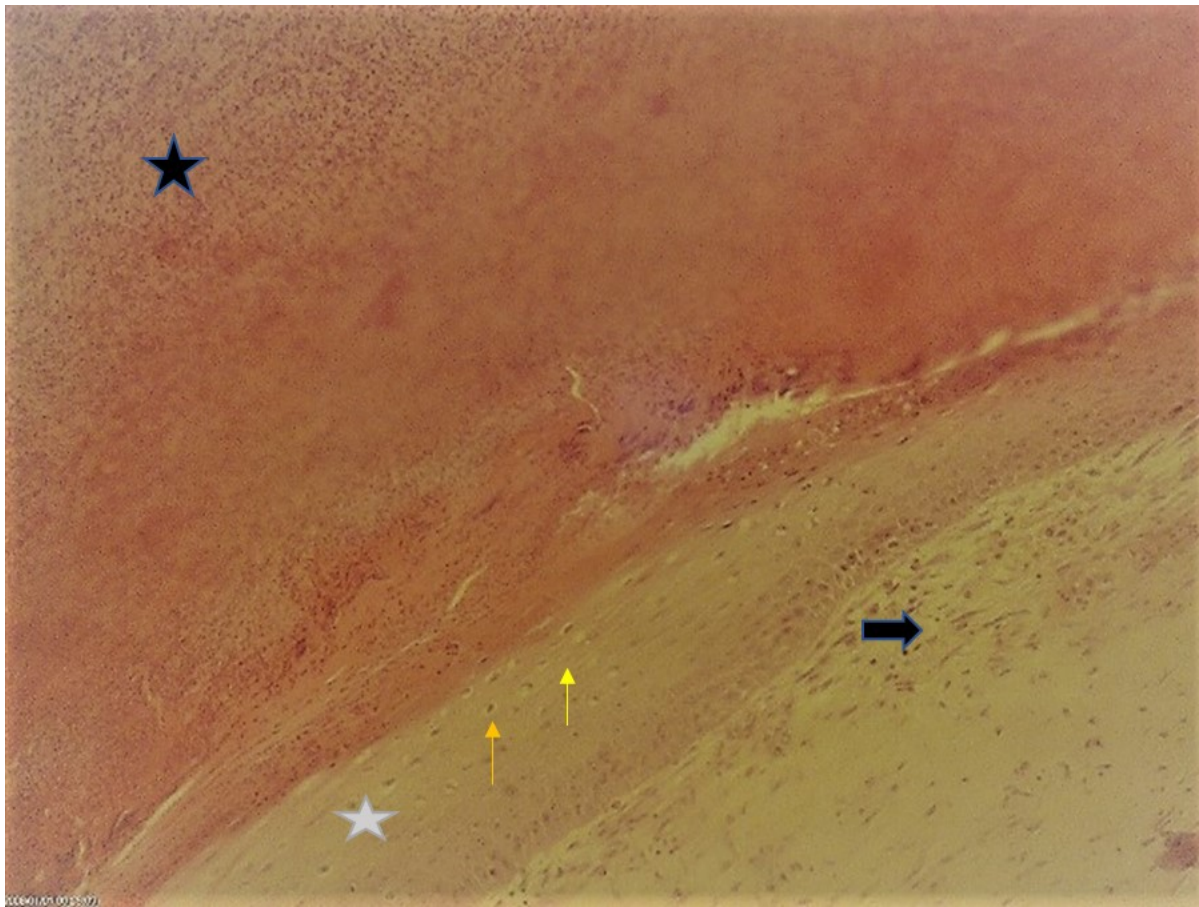


Figure 4: Extensive hyperkeratosis with heterophilic pustule formation (black star) that is covered by a dense mass of necrotic tissue), Epidermal hyperplasia (Gray star) Vacuolar keratinocyte cells (yellow arrows) and underlying granulation tissue in the dermis (black arrow).

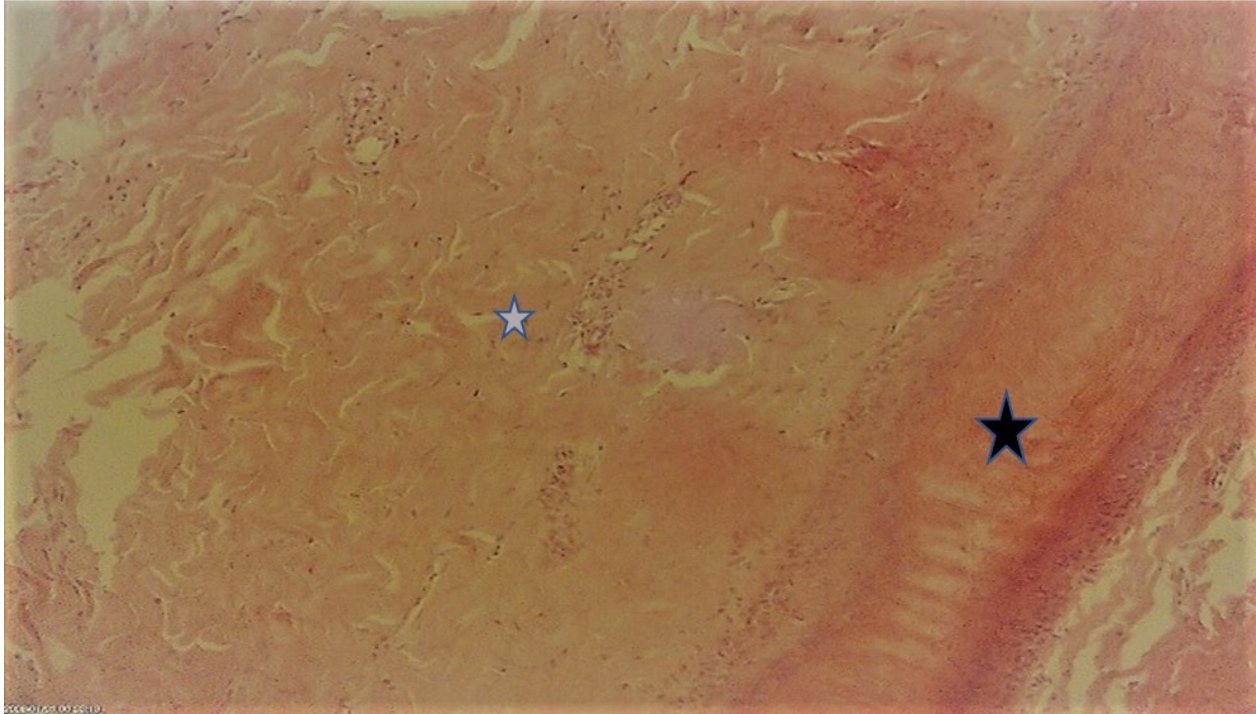


Figure 5: Epidermis is replaced mostly by necrotic material (Black star). Diffuse dermal edema and fibrosis in the dermis and extensive hyperkeratosis is also noted. The ulcerated area is covered by a dense mass of necrotic tissue (Gray star).

Discussion

Foot pad dermatitis (FPD) that is also known by other names, such as pododermatitis and contact dermatitis is one of the most frequent occurring medical conditions in poultry and characterizes an inflammatory to necrotic lesions ranging from superficial to deep lesions on the plantar surface of the footpads and toe (Kittelsen *et al.*, 2023; Bergman *et al.*, 2013; Shepherd & Fairchild, 2010). The prevalence and severity of foot pad dermatitis (FPD) are influenced by a wide range of circumstances which may affect litter quality and consequently the foot pad health (Lingens *et al.*, 2023).

Twenty two percent of the chickens investigated in our research had FPD. De Jong *et al.* reported that %65 of the chickens in their study had FPD lesions (38% severe and 26% mild lesions) in the Netherlands (De Jong *et al.*, 2012). Allain *et al.* have reported a %83 incidence of FPD in France that %70.8 of these had severe lesions (Allain *et al.*, 2009). Ekstrand *et al.* have reported a 38% incidence of FPD (%32 mild and %6 severe lesions) in Sweden (Ekstrand *et al.*, 1998). Sanotra *et al.* have reported a %42 incidence of FPD in Denmark (Sanotra *et al.*, 2003). Hashimoto *et al.* reported a FPD incidence from 31.9% (81/254) to 99.5% (1/222) in different

flocks in Japan (Hashimoto *et al.*, 2021). Allahbakhshi *et al.* have reported a 29.2 incidence of foot pad dermatitis in 10 flocks in Sharekord, Iran (Allahbakhshi *et al.*, 2016). The differences between our study and other studies could be due to rearing conditions and different scoring systems.

Mayne have suggested that continually standing in wet litter will cause the footpad to soften and become more prone to damage, predisposing the bird to developing FPD. Drying out the litter and moving birds from wet litter to dry litter was observed to reverse the severity of FPD (Mayne, 2005).

Ekstrand *et al.* have suggested that adding extra litter during the rearing period results in significantly lower prevalence of lesions compared with flocks where no extra litter had been added (Ekstrand *et al.*, 1998). Meluzzi *et al.* found that broilers raised on deeper litter had a lower occurrence of FPD than those raised on a thin layer (Meluzzi *et al.*, 2008). Broilers raised on sawdust and rice shell litter show good results in terms of the incidence of contact foot-pad dermatitis (Xavier *et al.*, 2010). The low price of rice shell and sawdust as the main litter component after the first week of rearing in our study research area combined with and high price of chicken litter as fertilizer is the cause of the farmers to constantly add

this material to the litter. This fact combined with good ventilation of the farms and proper stocking and drinker management makes the litter deeper and drier that may be the reason of lower incidence of FPD in Kazerun and Noorabad area. In addition, the region has experienced drought for several years at the time of the study that had increased water thrift.

Martrenchar et al. noted that if the condition of the litter be suitable, it is possible to have flocks with a low prevalence of foot-pad dermatitis in chicken broilers (Martrenchar *et al.*, 2003), Mayne et al. have suggested histopathologic alterations of the foot pads occur at an early age in turkey flocks and can turn out to fully developed lesions (Mayne *et al.*, 2006). The farms in our study used commercial Cardboard sheets that decompose through the first week of rearing that can be another probable reason of low prevalence of severe FPD lesions in this area.

Prevalence and severity of foot pad alterations seem to be age-related (Bergman *et al.*, 2013). Ekstrand et al. have reported that foot-pad score is significantly associated with week of slaughter and decreases over time (Ekstrand *et al.*, 1998). Because of the low price of chicken meat and shortage of chicken food and issues related to the chicken meat market, the chicken was sent to slaughter in a lower age in the period of this study that can cause a stop in FPD formation.

De Jong et al. have noted that flocks that had been treated with antibiotics tended to have less FPD than flocks without antibiotics treatment (De Jong *et al.*, 2012). Thøfner et al. found correlation between the incidence of footpad lesions and systemic bacterial infections in broiler breeder birds (Thøfner *et al.*, 2019). Antibiotic consumption is higher in Iran broiler farms than more of the developed countries (Mohammadzadeh *et al.*, 2022). That can be another probable reason of lower FPD rate in the present research

Kaukonen et al. has reported a %64 incidence of FPD severe lesions in Italy (Kaukonen *et al.*, 2012). The severe form of FPD percent in our study is lower than that what is reported by De Jong et al. (De Jong *et al.*, 2012). Guler et al. have suggested that severe cases of FPD seen in in deep litter systems is due to the poor litter quality (Guler *et al.*, 2021). De Jong et al. have suggested that Severity of FPD is reduced in warm and dry seasons and is elevated in cooler months (De Jong *et al.*, 2012). This may result from

elevated litter humidity. Kazerun and Noorabad province are located in warm and dry condition that reduces the moistures of the litter.

Our macroscopic and microscopic features are same to those noted by Mahmoud *et al.*, Riber *et al.*, Michel *et al.*, Mayne *et al.* and Shepherd and Fairchild (Mahmoud *et al.*, 2021; Riber *et al.*, 2020; Michel *et al.*, 2011; Mayne *et al.*, 2006; Shepherd & Fairchild, 2010).

Acute inflammation with a denser cellular infiltration and thickening of the stratum corneum, which were referred to as horned pegs by Whitehead was also seen in our study that is not reported by other researchers (Whitehead, 1990).

The deep ulcers and chronic abscessation and fibrosis of underlying synovial structures reported by Greene et al. is not seen in our study that may be related to this fact that the flocks in our study were slaughtered in a lesser age (Greene *et al.*, 1985).

Conclusion

Foot pad dermatitis in our study had a lower incidence compared to other similar researches in Iran and abroad that can be due to better litter management in our studied broiler flocks. Despite this, more research is required regarding the incidence of foot lesions in Iranian broiler flocks.

Conflict Interest

Non.

References

- Abraham ME., Weimer SL., Scoles K., Vargas JL., Johnson TA., Robison C., et al. Orange corn diets associated with lower severity of footpad dermatitis in broilers. *Poult Sci*, 2021; 100(5): 101054.
- Agricultural statistics of Fars province, Fars Province Program and Budget Organization. Vice President of Statistics and Information, 2020; Page 73.
- Allahbakhshi K., Fathi hafshejani E. and Gholami Ahangaran M. The study of incidence of foot pad dermatitis in broiler chickens in Shahrekord. *Research in Veterinary Magazine*, 2016; 9(1): 41-49.
- Allain V., Mirabito L., Arnould C., Colas M., Le Bouquin S., Lupo C., et al. Skin lesions in broiler

- chickens measured at the slaughterhouse: relationships between lesions and between their prevalence and rearing factors. *Br Poult Sci*, 2009; 50(4): 407-17.
- Bergmann S., Ziegler N., Bartels T., Hübel J., Schumacher C., Rauch E., et al. Prevalence and severity of foot pad alterations in German turkey poults during the early rearing phase. *Poult Sci*, 2013;92(5): 1171-6.
- Biesek J., Banaszak M., Grabowicz M. and Wlazlak S. Chopped straw and coffee husks affect bedding chemical composition and the performance and foot pad condition of broiler chickens. *Sci Rep*, 2023; 23; 13(1): 6600.
- De Jong IC., Van Harn J., Gunnink H., Hindle VA. and Lourens A. Footpad dermatitis in Dutch broiler flocks: prevalence and factors of influence. *Poult Sci*, 2012; 91(7):1569-74.
- Ekstrand C., Carpenter TE., Andersson I. and Algers B. Prevalence and control of foot-pad dermatitis in broilers in Sweden. *Br Poult Sci*, 1998; 39(3): 318-24.
- Freihold D., Bartels T., Bergmann S., Berk J., Deerberg F., Dressel A., et al. Investigation of the prevalence and severity of foot pad dermatitis at the slaughterhouse in fattening turkeys reared in organic production systems in Germany. *Poult Sci*, 2019; 1; 98(4): 1559-1567.
- Greene JA., McCracken RM. and Evans RT. A contact dermatitis of broilers -clinical and pathological findings. *Avian Pathol*, 1985; 14(1): 23-38.
- Guler S., Petek M., Çavusoghlo E. and Topal HE. The histological characteristics of footpad dermatitis in a fast-growing broiler chickens raised on different floor housing systems. *Erciyes Üniv Vet Fak Derg*, 2021; 18(2): 96-101.
- Hashimoto S., Yamazaki K., Obi T. and Takase K. Footpad dermatitis in broiler chickens in Japan. *J Vet Med Sci*, 2011; 73(3): 293-7.
- Kaukonen E., Norring M. and Valros A. Effect of litter quality on foot pad dermatitis, hock burns and breast blisters in broiler breeders during the production period. *Avian Pathol*, 2016; 45(6): 667-673.
- Kittelsen KE., Vasdal G., Moe RO., Steinhoff FS. and Tahamtani FM. Health effects of feed dilution and roughage in Ross 308 broiler breeder cockerels. *Poult Sci*, 2023; 102(10): 102985.
- Lingens JB., Visscher C., Sürle C., Grone R., von Felde A., Wilke V., et al. Effect of replacing whole wheat with broken rye as a sustainable grain in diets of fattening turkeys on growth performance., litter quality., and foot pad health. *Front Vet Sci*, 2023; 11; 10: 1142500.
- Mahmoud UT., Darwish MHA., Ali FAZ., Amen OA., Mahmoud MAM., Ahmed OB., et al. Zinc oxide nanoparticles prevent multidrug resistant *Staphylococcus*-induced footpad dermatitis in broilers. *Avian Pathol*, 2021; 29: 1-13.
- Martrenchar A., Boilletot E., Huonnic D. and Pol F. Risk factors for foot-pad dermatitis in chicken and turkey broilers in France. *Prev Vet Med*, 2002; 22; 52(3-4): 213-26.
- Mayne RK. A review of the aetiology and possible causative factors of foot pad dermatitis in growing turkeys and broilers. *Worlds Poult Sci J*, 2005; 61(2): 256-67.
- Mayne RK., Hocking PM. and Else RW. Foot pad dermatitis develops at an early age in commercial turkeys. *Br Poult Sci*, 2006; 47(1): 36-42.
- Meluzzi A., Fabbri C., Folegatti E. and Sirri F. Effect of less intensive rearing conditions on litter characteristics, growth performance, carcass injuries and meat quality of broilers. *Br Poult Sci*, 2008; 49(5): 509-15.
- Michel V., Prampart E., Mirabito L., Allain V., Arnould C., Huonnic D., et al. Histologically-validated footpad dermatitis scoring system for use in chicken processing plants. *Br Poult Sci*, 2012; 53(3): 275-81.

- Mohammadzadeh M., Montaseri M., Hosseinzadeh S., Majlesi M., Berizi E., Zare M., et al. Antibiotic residues in poultry tissues in Iran: A systematic review and meta-analysis. *Environ Res*, 2022; 204(Pt B): 112038.
- Pagazaurtundua A. and Warriss PD. Levels of foot pad dermatitis in broiler chickens reared in 5 different systems. *Br Poult Sci*, 2006; 47(5): 529-32.
- Riber AB., Rangstrup-Christensen L., Hansen MS., Hinrichsen LK. and Herskin MS. Characterisation of footpad lesions in organic and conventional broilers. *Animal*, 2020; 14(1): 119-128.
- Sanotra GS., Berg C. and Lund JD. A comparison between leg problems in Danish and Swedish broiler production. *Animal Welfare*, 2003; 12(4): 677-83.
- Shepherd EM. and Fairchild BD. Footpad dermatitis in poultry. *Poult Sci*, 2010; 89(10): 2043-53.
- Swiatkiewicz S., Arczewska-Wlosek A. and Jozefiak D. The nutrition of poultry as a factor affecting litter quality and foot pad dermatitis - an updated review. *J Anim Physiol Anim Nutr (Berl)*, 2017; 101(5): e14-e20.
- Thøfner ICN., Poulsen LL., Bisgaard M., Christensen H., Olsen RH. and Christensen JP. Correlation between footpad lesions and systemic bacterial infections in broiler breeders. *Vet Res*, 2019; 22; 50(1): 38.
- Whitehead CC. Biotin in animal nutrition., animal nutrition and health., vitamins and fine chemicals division. Roche, Basel, Switzerland 1990; PP: 6-58.
- Wu K. and Hocking PM. Turkeys are equally susceptible to foot pad dermatitis from 1 to 10 weeks of age and foot pad scores were minimized when litter moisture was less than 30%. *Poult Sci*, 2011; 90(6): 1170-8.
- Xavier DB., Broom DM., McManus CM., Torres C. and Bernal FE. Number of flocks on the same litter and carcass condemnations due to cellulitis., arthritis and contact foot-pad dermatitis in broilers. *Br Poult Sci*, 2010; 51(5): 586-91.
- Yousaf A., Tunio S., Kumar L., Rahman SU., Channo A., Soomro AG., et al. A review study on legs lameness and weaknesses assessment methods in commercial broiler farming in Pakistan. *BJSTR*, 2021; 40(2): 32113-20.
- Zampiga M., Meluzzi A., Pignata S. and Sirri F. Occurrence of breast meat abnormalities and foot pad dermatitis in light-size broiler chicken hybrids. *Animals (Basel)*, 2019; 9(10): 706.



بررسی میزان شیوع و شدت ضایعات درماتیت کف پا در گله های مرغ گوشتی شهرستان کازرون و نور آباد، جنوب غرب ایران

امیر اشکان مهجور*، محسن قهرمانی

گروه پاتوبیولوژی، واحد کازرون، دانشگاه آزاداسلامی، کازرون، ایران

تاریخ دریافت: ۱۴۰۲/۱۱/۰۵ اصلاح نهایی: ۱۴۰۳/۰۱/۱۲ تاریخ پذیرش: ۱۴۰۳/۰۲/۰۱

چکیده

زمینه و هدف: درماتیت کف پا یک بیماری التهابی و نکروتیک در کف پای طیور می باشد. این مطالعه برای تعیین میزان وقوع این بیماری درمزارع پرورش مرغ گوشتی شهرستان های نور آباد و کازرون طراحی شد.

مواد و روش ها: این مطالعه بر روی بیست و نه گله مرغ گوشتی از یازده مزرعه با اندازه گله ده هزار تا بیست و دو هزار مرغ بین آذر ۱۳۹۹ و اردیبهشت ۱۴۰۱ در شهرستان های کازرون و نورآباد انجام شد و شدت درماتیت کف پا بر اساس مطالعات میکروسکوپی و ماکروسکوپی انجام شد.

یافته ها: از ۴۰۰۰ مرغ گوشتی بررسی شده در این مطالعه ۸۹۷ مورد (۲۲/۴۲٪) مبتلا به درماتیت کف پا بودند که در این میان تیپ ۱ در ۴۲۹ (۱۰/۷۲٪) مورد، تیپ ۲ در ۳۴۳ (۱۱/۳۵٪) و تیپ ۳ در ۱۲ (۰/۰۳٪) مورد مشاهده شد.

نتیجه گیری: در این مطالعه میزان درماتیت کف پا به نسبت پائین مشاهده شد که می تواند مرتبط با مدیریت مناسب به خصوص مدیریت مناسب بستر در گله های گوشتی مورد مطالعه باشد.

واژه های کلیدی: درماتیت کف پا، مرغ گوشتی، میزان شیوع

امیر اشکان مهجور، محسن قهرمانی. بررسی میزان شیوع و شدت ضایعات درماتیت کف پا در گله های مرغ گوشتی شهرستان کازرون و نور آباد، جنوب غرب ایران. مجله طب دامپزشکی جایگزین. ۱۴۰۳؛ ۷(۲۲): ۱۳۳۳-۱۳۴۲.

* نویسنده مسئول: گروه پاتوبیولوژی، واحد کازرون، دانشگاه آزاداسلامی، کازرون، ایران.