

# Ultrasonographic Measurements of Intraocular Structures in Healthy Najdi Goat

Sadi Foad

Department of Clinical Sciences, Mahabad Branch, Islamic Azad University, Mahabad, Iran.

\* **Corresponding Author:** Foad Sadi, Department of Clinical Sciences, Islamic Azad University, Mahabad Branch, Mahabad, Iran, Email : [Foadsadi@yahoo.com](mailto:Foadsadi@yahoo.com)

(Received: June 18, 2020 ;Accepted: August 26,2020)

## Abstract

The aim of this study was to determine intraocular anatomical parameters of the Najdi goat in normal state using ultrasonographic images. Since intra ocular parameters undergo changes by inflammation induced by different eye diseases, Knowledge of the dimensions of ocular components and their normal range is essential for better understanding of clinical vision disorders. Ocular echobiometric inspection was carried out on 12-18 months old healthy Najdi breed goats. Ultrasonographic images were obtained by a 10MHz linear probe in the sagittal plane. The ocular echobiometric measurement revealed the following: axial globe length (AGL)  $19.8\pm 0.3$ mm, anterior chamber depth (ACD)  $1.82\pm 0.16$ mm, vitreous chamber depth (VCD)  $9.45\pm 0.15$ mm, sclera retinal rim thickness (SRT)  $1.25\pm 0.07$ mm, lens thickness (LT)  $7.45\pm 0.25$ mm and corneal thickness (CT)  $0.45\pm 0.01$ mm. The estimated dimensions of the normal ocular components obtained in this study are presented in a table to be used by veterinarians in the diagnosis of goat ocular diseases.

**Keywords:** *Ocular, Najdi goat, ultrasonographic, echobiometric.*

## Introduction

Goat species is an important component of animal genetic resources. Together with sheep, they are commonly called small ruminants, partly because of their size (2006; Sandra, 2010). Goats provide meat, milk and skins; they also contribute to socioeconomic, cultural and recreational needs of mankind. In the last decade, the demand for goat meat and cheese has increased in the USA, because population demographics have shifted toward those that traditionally consume goat products (Boyazoglu et al., 2005; Devendra et al., 2006; Sandra, 2010).

Goat breeds are usually classified by their geographical origin, their region and productivity, or their height at the withers (Glowatzki et al.,2008; Morand – Fehret al.,2004). Najdi goat breed is relatively small and has a good milk production (Gall, 1996). This breed, which is also called Tali, is one of the main dairy breeds kept in the hot and humid area south of Iran (Gall, 1996).

Various disorders and parasitic infections are serious constraints affecting goat production worldwide. Corneal edema is a general clinical sign of goat corneal ulceration, keratitis and many systemic diseases, and prevents the direct visualization of intraocular structures by ophthalmoscopy (Gregory et al., 2003; Waldrige and Colitz, 2002). Knowledge of the dimensions of ocular components is required for better understanding of many research and clinical vision disorders (Osuobeni and Hamidzada, 1999).

Echobiometric evaluation of the eye was one of the early uses of ultrasound in human ophthalmology (Coleman, 1999). It is a useful tool for the assessment of Ocular anomalies and diseases such as phthisis bulbi, microphthalmia, pseudo exophthalmia, scleral ectasia, and congenital glaucoma (Mason, 1981; McMullen and Gilger, 2006). knowledge of the echobiometric appearance and normal dimensions of the eye can serve as a basis for sonographic examinations when eye disease causes alterations in the ocular dimensions and appearance (Go` rig et al., 2006).

Although Najdi breed is one of the native Iranian goat, there is no data on **its** ocular echobiometric appearance **and** intraocular structures. In this study , we investigate the Najdi goat eye ball structures by ultrasonography and measure different components in the normal state. The obtained information can be used as a reference in the diagnosis of goat eye diseases.

## Materials and methods

Ocular echo biometric examinations were performed on 15 healthy male and female Najdi goats 12-18 months old and weight range of 24-32kg. The measurement was carried out on restrained animals, without use of sedation or topical analgesia. Sonographic examination was accomplished using an ultrasound machine (Edan D6, Edan Instrument, Inc, China) and a 10 MHz linear transducer. The probe was placed in a sagittal plane and coupling gel was applied directly to the upper eyelid. Similar to performing cadaster, the ocular dimensions were measured through upper eyelid, and the images were saved. Ocular distances were measured from the standard views using caliber of the ultrasound machine. Optimal B-scan images along the central optic axis enabled recording of six intraocular dimensions: (1) axial globe length (AGL) was measured from the anterior corneal surface to the retina; (2) anterior chamber depth (ACD) was measured as the distance between echoes from the posterior corneal surface to the anterior lens surface; (3) vitreous chamber depth (VCD) was the distance between echoes from the posterior lens surface to the retina; (4) scleroretinal rim thickness (SRT); (5) lens thickness (LT) was the distance between echoes from the anterior to posterior lens surfaces; and (6) corneal thickness (CT) was measured as the distance between the echoes from the anterior to posterior corneal surfaces (Fig. 1).

### Statistical analysis was performed using SPSS software

The mean and standard deviation for each set of measurements were calculated, and ocular dimensions and data were presented as mean  $\pm$  standard deviation.

## Results

The sonographic images of goat eye revealed that the aqueous humor (the fluid filled vitreous body) appears as an anechoic region, and the internal appearance of the lens (the area trapped between anterior and posterior lens capsule) also looks anechoic. The anterior chamber (the area restricted between the hind part of cornea and anterior lens capsule) appeared as a single anechoic area (Fig. 1). In general, the study revealed that the cornea, anterior and posterior lens capsule can be considered the hyper echoic parts in the goat eye. The scleroretinal rim appeared as a concave echogenic line at the posterior margin of the eye ball. The anterior lens capsule looked as a convex echogenic line, while the posterior lens capsule appeared as a concave echogenic line, and the lens itself (restricted between them) seemed as an anechoic area (Fig. 2).

The echo biometric measurements on the right and left eyes of the Najdi goat are shown in Table 1. Table 1 also shows total mean and standard deviation of the right and left eye measurements in male and female goats. No Significant Differences was found between the right and left eye measurements ( $P>0.05$ ). There was also no Significant Differences between male and female Najdi goats.

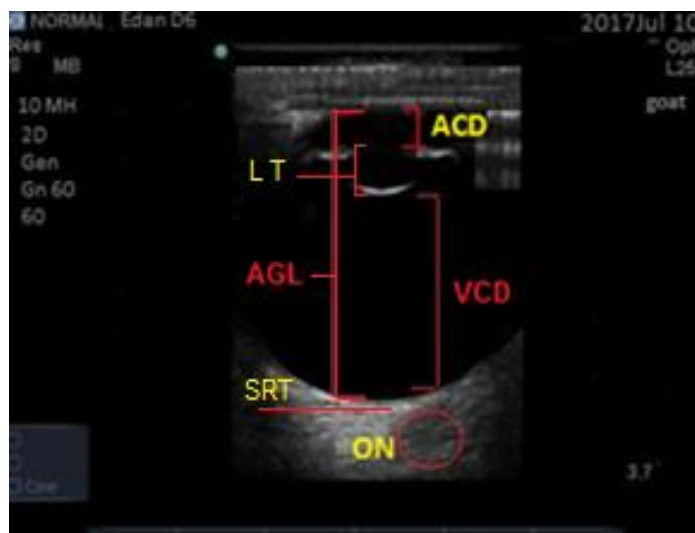


Figure 1. Sagittal B-mode ultra-sonogram of goat eye showing: Axial globe length (AGL), Anterior chamber depth (ACD), lens thickness (LT), Vitreous chamber depth (VCD), Scleroretinal rim and Optic nerve region (ON).

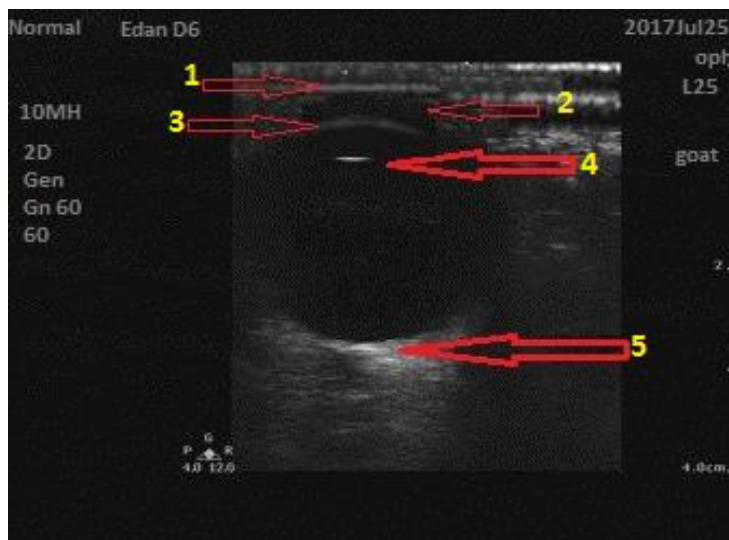


Figure 2. Sagittal B-mode ultra-sonogram of goat eye showing: 1-Cornea, 2-Anterior chamber, 3-Anterior lens capsule (ALC), 4-Posterior lens capsule (PLC) and 5- Scleroretinal rim.

**Table 1. Measurement of goat ocular components (Mean  $\pm$  SD) per mm.**

<b>Parameter</b>	<b>Right (mm)</b>	<b>left (mm)</b>	<b>Mean <math>\pm</math> SD (mm)</b>
Axial global length (AGL)	19.6 $\pm$ 0.4(male) 19.0 $\pm$ 0.4(female)	20.0 $\pm$ 0.6(male) 19.6 $\pm$ 0.2(female)	19.8 $\pm$ 0.5(male) 19.3 $\pm$ 0.3(female)
Anterior chamber depth (ACD)	1.80 $\pm$ 0.14(male) 1.70 $\pm$ 0.12(female)	1.84 $\pm$ 0.18(male) 1.76 $\pm$ 0.16(female)	1.82 $\pm$ 0.16(male) 1.73 $\pm$ 0.14(female)
Vitreous chamber depth (VCD)	9.50 $\pm$ 0.14(male) 9.40 $\pm$ 0.12(female)	9.40 $\pm$ 0.16(male) 9.20 $\pm$ 0.14(female)	9.45 $\pm$ 0.15(male) 9.30 $\pm$ 0.13(female)
Sclero-retinal rim thickness (SRT)	1.20 $\pm$ 0.05(male) 1.10 $\pm$ 0.6(female)	1.30 $\pm$ 0.08(male) 1.20 $\pm$ 0.10(female)	1.25 $\pm$ 0.07(male) 1.15 $\pm$ 0.08(female)
Lens thickness (LT)	7.40 $\pm$ 0.22(male) 7.20 $\pm$ 0.12(female)	7.51 $\pm$ 0.27(male) 7.30 $\pm$ 0.18(female)	7.45 $\pm$ 0.25(male) 7.25 $\pm$ 0.15(female)
Cornel thickness (CT)	0.43 $\pm$ 0.00(male) 0.40 $\pm$ 0.01 (female)	0.47 $\pm$ 0.02(male) 0.44 $\pm$ 0.03 (female)	0.45 $\pm$ 0.01(male) 0.42 $\pm$ 0.02 (female)

## Discussion

The most common clinical use of ocular ultrasound are the evaluation of the retinal detachment in eyes with cataract, the presence of intraocular lesions including lens displacement, intravitreal hemorrhage and intraocular foreign bodies (Hillyer, 1993; Miller, 1991; Wilkie and Gilger, 1998). The sonographic images give an exquisite index to evaluate the ocular and orbit (Kassab, 2012; Nautrap, 2000). Ultrasonographic scanning of the present study revealed that some areas of goat ocular have no echoes and are said to be anechoic, and the anechoic nature of some globe parts of the caprine eye are similar to that in bovine and ovine (Alexandre et al., 2009; Goërig et al., 2006; Scotty et al., 2004). Our study also showed that the echo texture nature of the aqueous humor goat eye is fine, regular and homogeneous, which is similar to those described in horse, dogs, bovine and ovine. In addition, the anterior chamber appeared as a homogenous and anechoic region, since it is filled with an aqueous fluid. This result is in agreement with findings of Mason (1981), Kassab (2012) and Scotty et al. (2004).

Ultrasonography investigations of the eyeball structures have also been performed in the Sannen goat (Alexandre et al., 2009) and the results are similar to those of the present study. Our findings showed that dimensions of anterior chamber, lens, vitreous chamber and axial globe length in adult goats do not differ among the genders, and ultrasonographically, intraocular chambers and structures resemble those observed in other animal species. Obviously, the knowing the normal ocular dimensions can facilitate the use of ultrasonography in the evaluation of ocular disease in adult goats.

The hyper echoic parts represented by the cornea, scleroretinal rim and lens capsule (anterior and posterior capsule) investigated in this study were similar to that observed in ovine, buffalo and bovine, but in different measurements due to their size differences. This hyper echogenicity was the result of their compact nature, because the hyper echoic organs reflect more echoes to transducer and appear as white dots aggregated in small lines in shapes depending on the molecular nature of the tissue (Mason, 1981; Assadnassab and Fartashvand, 2011; Kassab, 2012).

In a study of intraocular structures of thirty adult Boer/Alpine cross breed goats measured by ultrasonography, it was found that some of the eye structures of this breed are smaller than those in Najdi goat breed (Alexandre et al., 2010). Another word, their dimensions were in both minimum and maximum ranges, whereas our results were similar to the minimum group. This difference is due to physical and racial differences between Najdi and Boer/Alpine cross breed races (Alexandre et al., 2010). <sup>Conversely,</sup> The results of this study are very similar to those of Iraqi goat study, which is probably due to the physical similarity of the Najdi goat and the Iraqi goat breeds (Sammer and Abid, 2016).

Our ultrasonographic examination of the axial globe length, vitreous body depth, corneal thickness, scleroretinal rim thickness and lens thickness revealed

that there are many similarities between goat ocular dimensions and those described in cattle, dogs, buffalo and horses, with some variations in the shape and dimensions (Alexandre et al., 2010; Assadnassab and Fartashvand, 2011; Go´rig et al., 2006; Mason, 1981; Nautrap, 2000). Generally, no difference was found between the Najdi goat and other goat breeds in the ultrasonographic appearance of ocular structures.

## Conclusion

The ultrasonographic appearance of goat eye showed a great similarity to other domestic animal species and revealed differences in eyeball dimensions due to physical deviations. It was also found that the dimensions of right and left eyeball structures were approximately identical in both male and female Najdi goats. The results of this study can provide an ultrasonographic guide (echobiometry measurements) of the healthy goat eye obtained by a widely available and valuable diagnostic tool i.e. ultrasonographic machine, which provides a well standard line of acquaintance for the study of pathologic conditions affecting the goat ocular components.

## References

- Alexandre PR., Miguel LS., Juliana PR., Samule FS., Isabelle AMA. and Jose´ LL. Ultrasonographic and echobiometric findings in the eyes of Saanen goats of different ages. *Veterinary Ophthalmology*, 2009 ; 12(5):313-317.
- Alexandre PR., Miguel LS., Juliana PR., Samule FS., Isabelle AMA. and Jose´ LL. Ultrasonographic and echobiometric findings in the eyes of adult goats. *Ciencia Rural*, 2010; 40 (3).
- Assadnassab GR. and Fartashvand M. Ultrasonography of vitreous chamber in Iranian Holstein cattle. *Advances in Environmental Biology*, 2011; 5 (7):1854-1856.
- Boyazoglu J., Hatziminaoglu I. and Morand – Fehr P. The role of the goat in society: past, present and perspectives for the future . *Small Rumin, Res.* 2005; 60:13 – 24 .
- Coleman DJ. Ultrasonic measurements of eye dimensions. *Ophthalmic Clinic*, 1999; (4): 225-236.



- Devendra C., Listening to farmers: participatory approaches for developing goat production. Symp. on Agric. Biotechnology and Environment, Daegu, Korea, 2006; pp: 1-19.
- Gall ch. Goat breeds of world. 1996; 4:78.
- Goering C., Varghese T. and Stiles T. Evaluation of acoustic wave propagation velocities in the ocular lens and vitreous tissues of pigs, dogs, and rabbits, A.J.V. R. 2006; 67: 288-295.
- Gregory L., Cardoso MV. and Birgel EH. Outbreak of contagious keratoconjunctivitis caused by *Mycoplasma conjunctivae* in adult caprines, bred in Sao Paulo state, Brazilian Archives of the Biological Institute, 2003; 70: 179-181.
- Hillyer MH. Ocular ultrasonography in the horse. In: Raw, ME and Parkinson, TJ (Eds.), The veterinary annual. (33rd Edn.), Oxford, Blackwell Scientific Publications, 1993; PP: 131-137.
- Kassab A. Ultrasonographic and macroscopic anatomy of the enucleated eyes of the buffalo (*Bos bubalis*) and the onehumped camel (*Camelus dromedarius*) of different ages. Anat. Histology Embryology, 2012; 41:7-11.
- Mason I.L. Breeds. In: C. Gall (Editor) Goat Production, chapter 3, Academic press, London, England, 1981.
- McMullen RJ. and Gilger BC. Keratometry, biometry and prediction of intraocular lens power in the equine eye, Veterinary Ophthalmology 2006; 9: 357-360.
- Miller WW. Diagnostic ultrasound in equine ophthalmology. Proc. Am. Assoc. Equine Pract, 1991; 36:559-565.
- Morand – Fehr P., Boutonnet JP., Devendra C., Dubeuf JP., Haenlein GFW., Holst P., Mowlem L and Capote J. Strategy for goat farming in the 21st century. Small Ruminant Research, 2004; 51:175 – 184.
- Nautrap CP., Tobias R. and Cartee RB. An Atlas and Textbook of Diagnostic Ultrasonography of The Dog and Cat. 1st ed., Manson Publishing, Hannover, 2000; 75-85.
- Osuobeni EP. and Hamidzada WA. Ultrasonographic determination of the dimensions of ocular components in enucleated eyes of the one-humped camel (*Camelus dromedarius*), Research in Veterinary Science, 1999; 67:123-127.
- Sammer A. and Abid A. Journal of Ultrasonographic anatomy of the eye goat. AL-Qadisiya Veterinary Medicine Sciences, 2016; 15(1): 168-172.
- Sandra GS. Goat science and production, 2010; 1: 1-20, 2:21-36.

Scotty NC., Cutler TJ. and Brooks DE. Diagnostic ultrasonography of equine lens and posterior segment abnormalities. *Veterinary Ophthalmology*, 2004; 7:127-139.

Waldridge BM. and Colitz CMH. Diseases of the eye. In: *Sheep and Goat Medicine*, 1st ed. (ed. Pugh DG) W.B. Saunders Company, Philadelphia, 2002; PA: 317-339.

Wilkie DA. and Gilger BC. Equine diagnostic ocular ultrasonography. In: Rantanen, NW and Mckinnon, AO (Eds.), *Equine diagnostic ultrasonography*, (1st Edn.), Baltimore, Williams and Wilkins. 1998; PP: 637-643.