

Clinical, Gross and Histopathological Studies on Natural Ascites Syndrome in Broiler Chickens

Mahjoor, A.A. ^{1*}, Hadipoor, M.M. ²

^{1*}Department of Pathobiology, Kazerun Branch, Islamic Azad University, Kazerun, Iran

²Department of Clinical science, Kazerun Branch, Islamic Azad University, Kazerun, Iran

*Corresponding Autor: Amir Ashkan Mahjoor, Department of Pathobiology, Kazerun Branch, Islamic Azad University, Kazerun, Iran. Email: amir.mahjoor@gmail.com

(Received: February 7, 2020; Accepted: April 13, 2020)

Abstract

This study was conducted to determine the pathology of ascites syndrome in Kazeoon and Shiraz province south of Iran. One hundred broiler chickens from 10 different farms showing clinical signs of ascites syndrome were compared with normal broilers from same farms. Postmortem examination revealed presence of fluid in the abdominal cavity, enlargement of right ventricle of the heart and swelling of the liver and kidney. Histopathology revealed congestion and edema in the liver, congestion and myofibril degeneration in the heart, congestion and edema of the parenchyma accompanied with atelectasis and extensive dilatation in tertiary bronchus with cartilaginous mass and primary stages of ossification in the lung, heavy mononuclear cell infiltration in the spleen and necrosis, congestion, heavy infiltration of mononuclear cell in the intestine were the main features observed in ascetic broilers.

Key words: *Broiler chickens, Clinical, Gross, Histopathological, Natural ascites syndrome*

Introduction

Pulmonary arterial hypertension, also known as Ascites syndrome (AS), remains a clinically challenging disease with a large impact on both humans and broiler chickens (Yang *et al.*, 2016). Ascites is a significant cause of mortality in many flocks of broiler chickens and the incidence appears to be increasing (Yang *et al.*, 2002). The syndrome is a metabolic disorder frequently found in fast growing broilers including abdominal distention and standing fluid collection in chicken abdomen. (Liu, 2016). An imbalance between oxygen supply and the oxygen required to sustain rapid growth rates and high food efficiencies causes ascites in broiler chickens (Baghbanzadeh and Decuypere, 2008). General agreement exists regarding the etiology of ascites hypoxia triggers peripheral vasodilatation, increased cardiac output and pulmonary arterial pressure, and right ventricular hypertrophy (Yang *et al.*, 2016). Increased

work-load by the right ventricle as a result of pulmonary hypertension leads to pressure-induced cirrhosis of the liver, and transudation of fluid into the abdominal cavity (Khodakaram Tafti and Karima, 2000). Because of the relationship to oxygen demand, ascites is affected and/or precipitated by factors such as growth rate, altitude (hypoxia) and environmental temperature (Baghbanzadeh and Decuypere, 2008). In this study we proposed to describe gross and histopathological changes accompanied with naturally causing ascites in Shiraz and Kazeroon province south of Iran.

Material and methods

In order to find naturally occurring ascites, poultry farms were monitored in Kazeoon and Shiraz province south of Iran. Ten farms were diagnosed with ascites in the study period. Farm mortality rate and overall condition of the selected farms were recorded and cases diagnosed with ascites were separated from other carcasses. Broilers with abdominal fluid accumulation and systemic cyanosis of the comb, wattle and skin were considered as ascetic cases (Rehman *et al.*, 1999). One hindered cases from 10 different farms (10 case each) with ascetic condition were selected. Meanwhile, Twenty-five birds with same age and strain from same farms without clinical signs were served as control group. Throughout necropsy was performed on selected cases. Internal organs were examined for macroscopic changes, photographed and samples were collected and preserved in 10% neutralized buffered formalin. Histological sections were processed routinely and five-micron sections were provided and stained with hematoxylin and eosin and were studied by light microscope.

Results

Gross pathology

Broilers with ascites showed distended abdomen and congestion of the breast and thigh muscles accompanied by skin and comb cyanosis. Subcutaneous hemorrhage on the thigh and breast muscles were seen in 26 cases.

Abdominal cavity off all birds contained clear to yellow-straw to green color fluid with or without gelatinous clots (Figure 1). Enlargement of the heart and right ventricle hypertrophy were the prominent change in affected birds heart. Pericardial effusion containing yellow fibrinous clots was observed in most cases. The livers were hemorrhagic and swollen with a

shiny-smooth surface and were covered with a thick yellow layer of gelatinous fibrin. Fibrosis of the capsule was noted too. Kidneys were swollen and congested with small hemorrhagic spots on their surface. Intestinal mucosa showed diffuse or focal hemorrhage and edema. Lungs were edematous and congested and were covered with gelatinous fluid in some cases. The spleen of affected birds was swollen and congested too.

Histopathology

The liver showed congestion, edema and malformation and necrosis of the hepatocytes with proliferation of fibrosis in the sinusoidal space. Infiltration of mono nuclear cells in liver parenchyma and hepatic triad and marked edema around lymphatic vessels was seen too. Thickening and fibrosis of the liver capsule was noted in all cases. In kidney congestion, tubular cell vacuolation and necrosis of the tubules with lymphocytic aggregation was observed.

In the heart hydro-pericardium and severe edema of the pericardium (Figure 2) was noted that in some cases different stage of fibrosis was in progress. Congestion of blood vessels with myofibril degeneration and presence of RBC and heterophils between the myofibrils was other features noted (Figure 3).

In the Lung congestion and edema of the parenchyma, atelectasis with extensive dilatation in tertiary bronchus was observed. Eosinophilic material was seen in most of the airways especially in tertiary bronchi and parabronchus. Mild infiltration of heterophils in interlobular space and alveolar septa was seen in most cases. Blood capillaries of the lung showed congestion with hypertrophy of smooth muscles. Cartilaginous mass and primary stages of ossification with marked edema around blood and lymphatic vessels were other changes found in affected bird lungs (Figure 5).

In spleen heavy mononuclear cell infiltration in parenchyma and capsule accompanied with mild disappearance of white pulp was the major finding (Figure 4).

The intestines showed necrosis, congestion and heavy infiltration of mononuclear cell in the parenchyma. Dilatation of lymphatic vessels in the top of the villous heads and edema in adventitia was recorded in intestines too. Aggregation of the villus heads were the prominent feature in intestines.

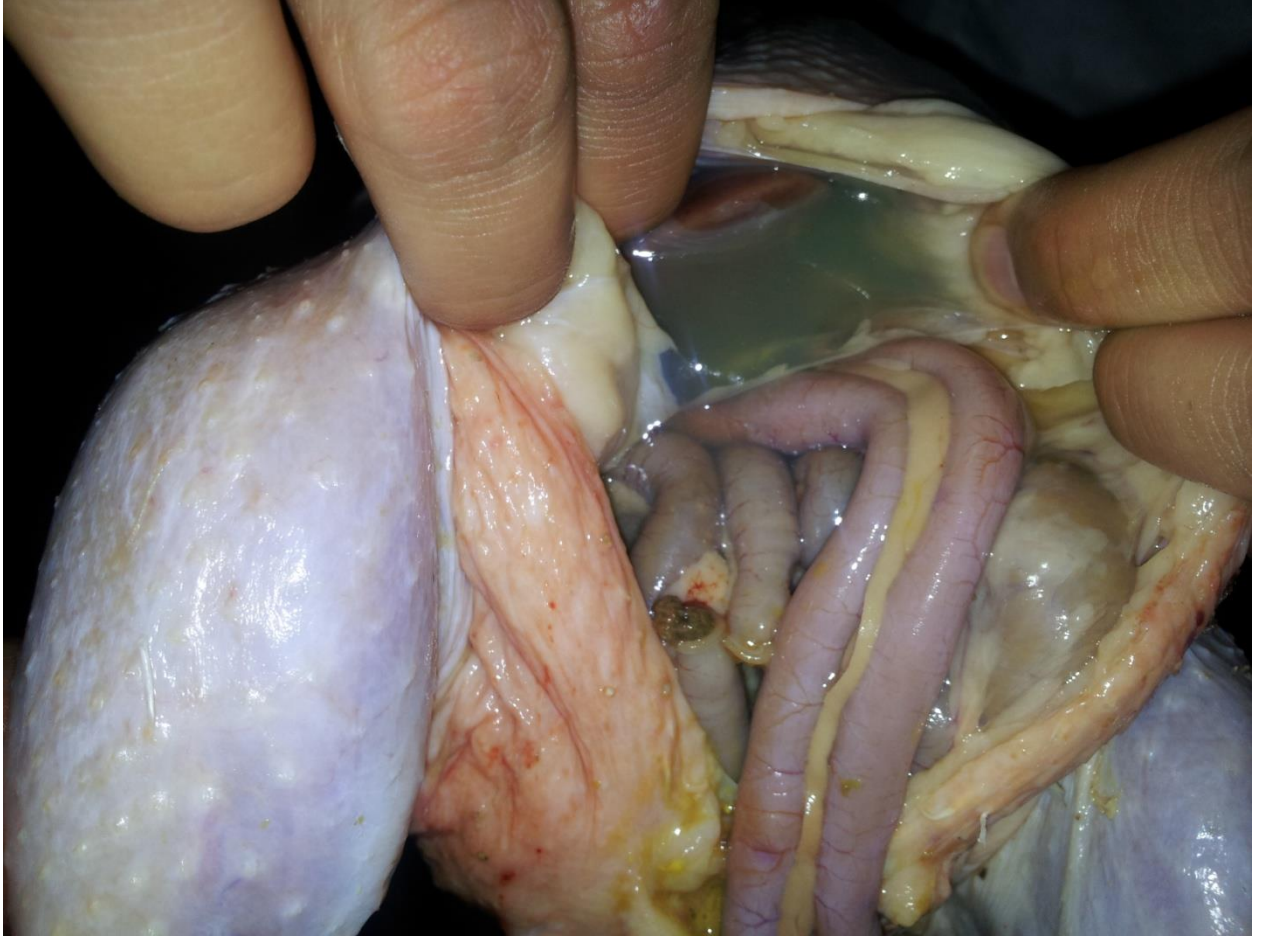

Figure1: Accumulation of fluid in the peritoneal cavity.

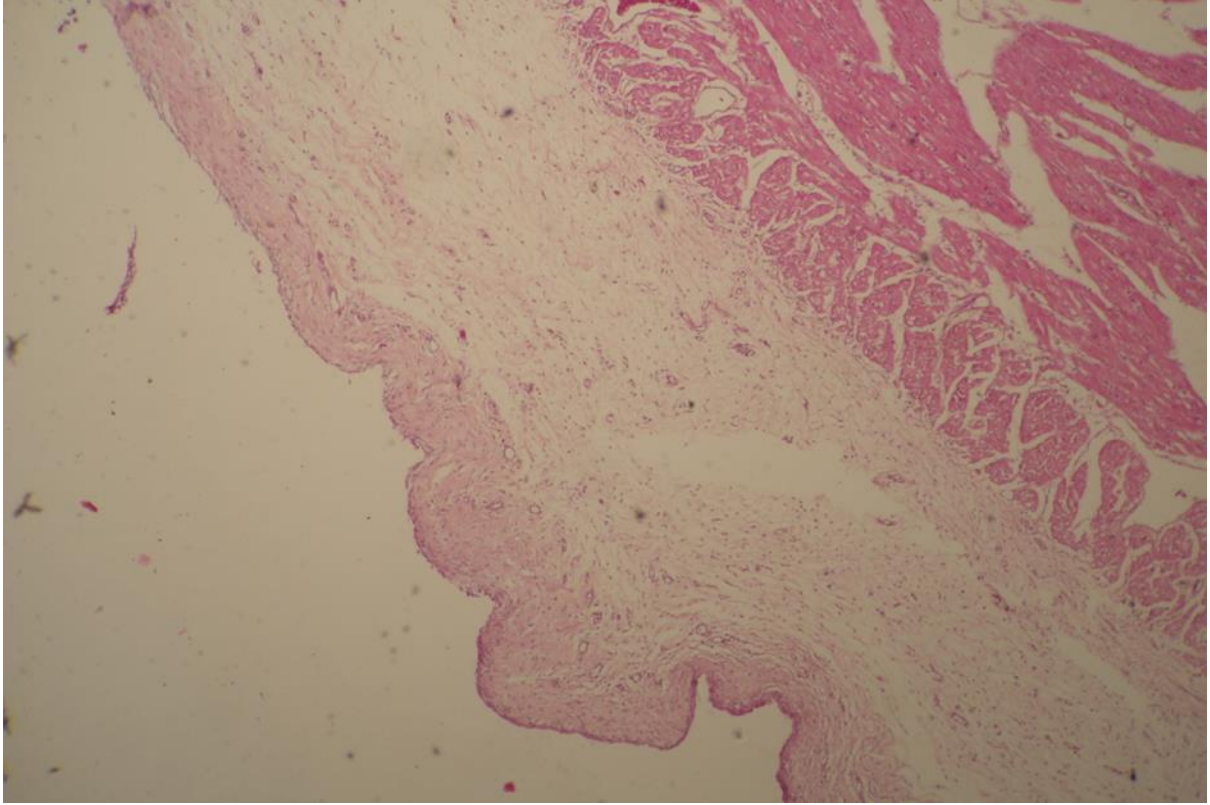
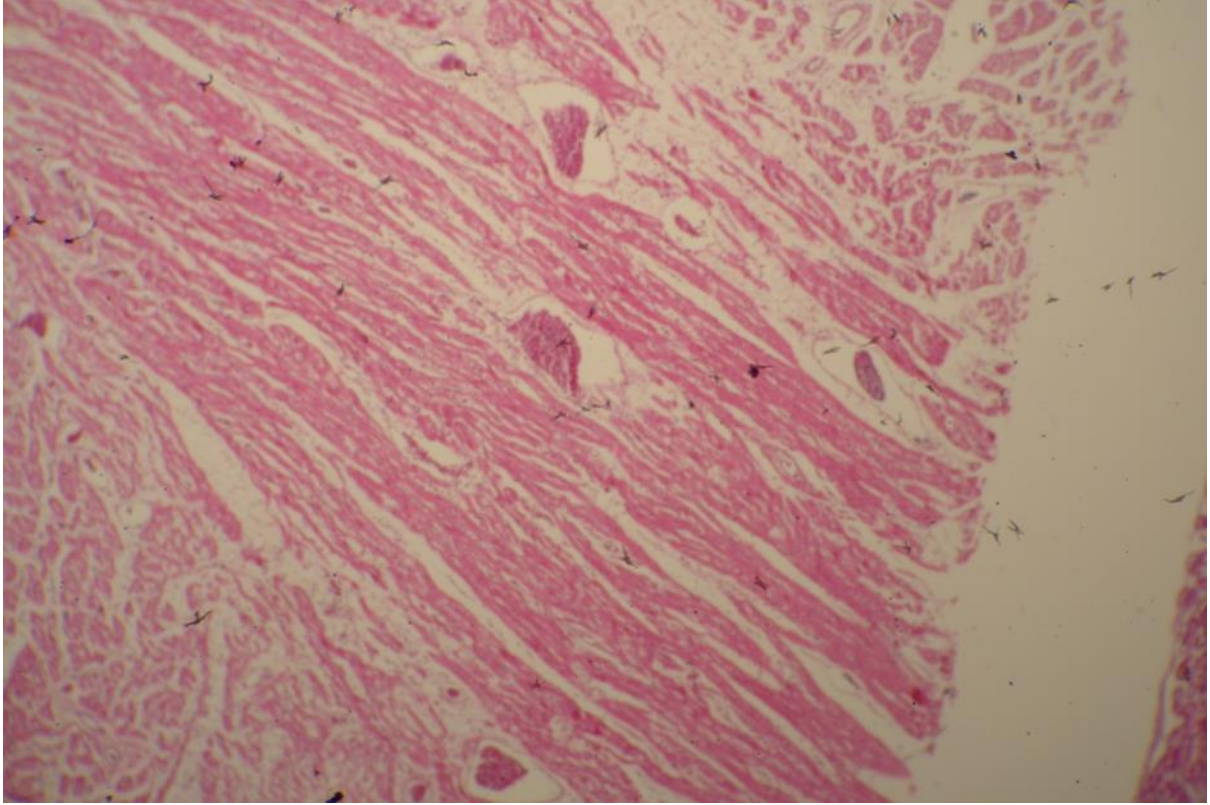


Figure 2: Edema of the pericardium and early stage of fibrosis in the heart. H&E X120.



Figur 3 : Congestion and edema in the heart. H&E X120

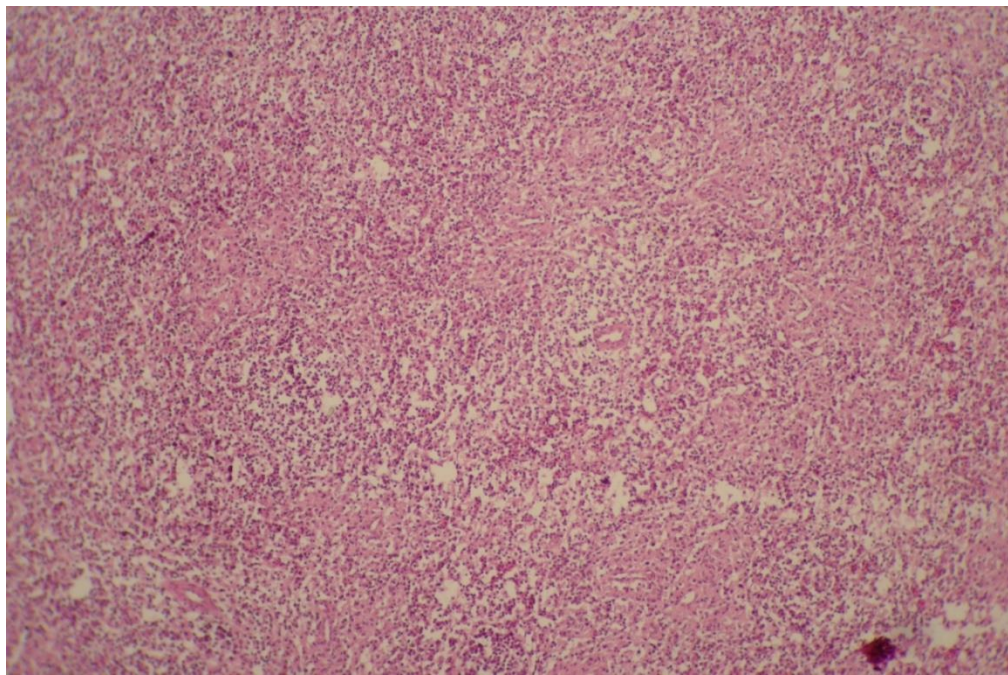


Figure4: Spleen-Depletion of lymphocytes and disappearance of white pulp. H&E X200

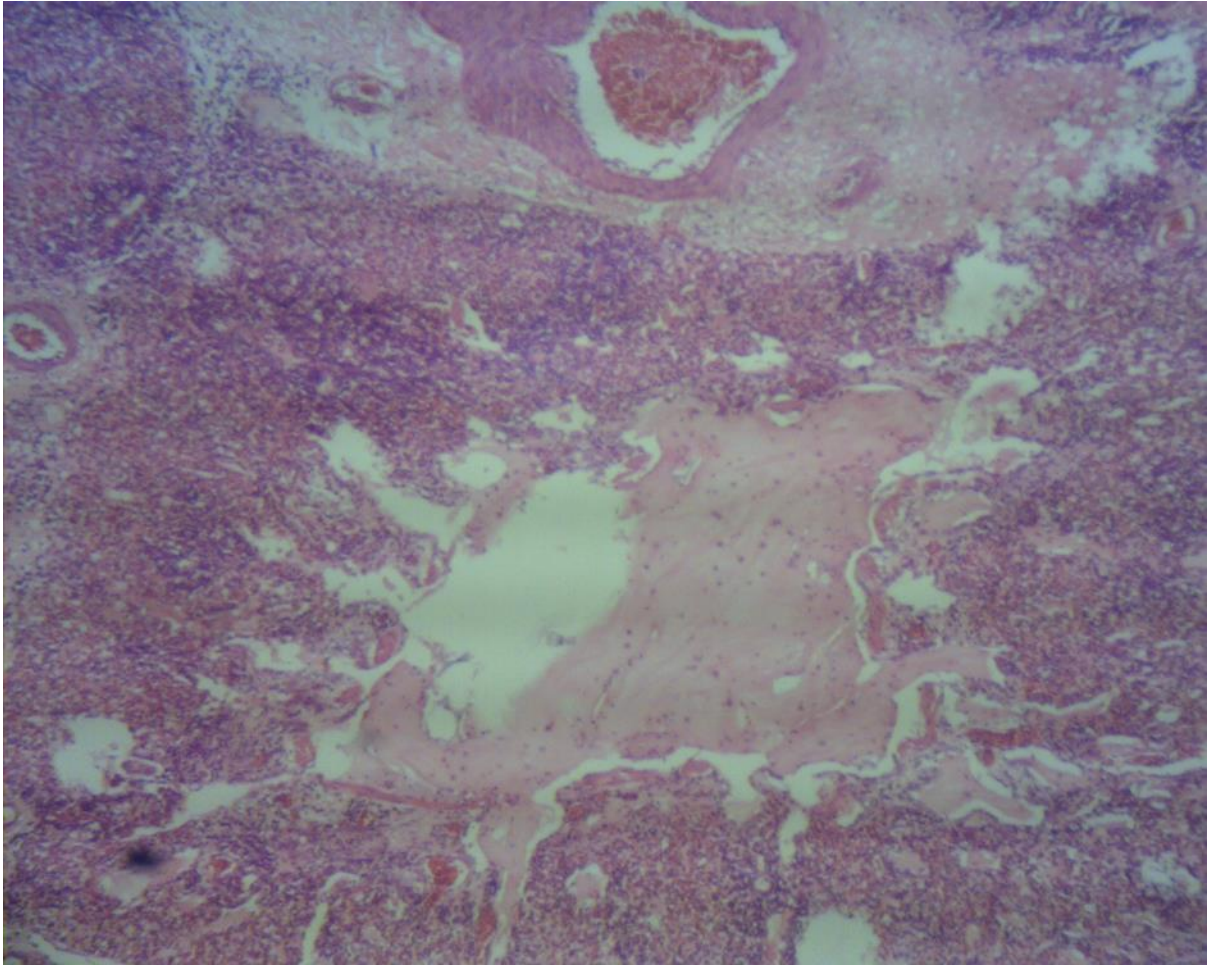


Figure5: Lung: Ossification center. Congestion and edema is seen in the parenchyma.

Discussion

Ascites is a significant cause of mortality in many flocks of growing broiler chickens and the incidence appears to be increasing. Approximately 4% of all broilers die from pulmonary hypertension syndrome (Khodakaram Tafti and Karima 2000; Sijun *et al.*, 2002).

Accumulation of non-inflammatory fluid in the cavity is reported after pulmonary hypertension in broilers. Primary pulmonary hypertension can result from high energy diet and genetic potential for rapid growth (Wideman *et al.*, 2013), that is common in broiler rearing in the study provinces.

Clinical signs noted in ascetic broilers in this study were nonspecific. Same results were noted by other researchers but diarrhea noted by Rehman *et al.*, (1999) was not seen in our study.

Dumpling of the liver surface reported by Rehman (1999) was not seen in our study. The Liver capsule thickening characterized by mesothelial cell proliferation with vascularization reported by Sakumi et al.,1999 was not seen in our study either. Smooth surface was also noted by Khodakaram Tafti and Karima (2000) and Julian (1988). Same picture of other liver histopathology found in this study was reported by other researchers (Nakamura *et al.*,1999,;Wilson *et al.*,1988). Kidney changes seen in this study was resemble of changes reported by other researchers. Julian (1988) noted that Chronic hepatic edema is likely responsible for fibrosis of the liver capsule and dilation of capsular lymphatics

Sarango and Ridell(1985) have reported a positive correlation between cartilaginous nodules in the lungs of ascetic birds and growth rate(Itoh *et al.*, 1997). Ascites is a problem in fast growing broiler chicks and with high growth rate. In the region due to economic reasons, farmers try to send chickens to market as soon as possible with the highest weight that puts a lot of pressure on heart and circulatory system of the broilers.

Julian (1983S) suggested that cartilaginous center in the lung is related to single embryonic cells of cartilage that entered the circulation from the leg bones and became trapped in the lungs and subsequently developed in lungs. Ossification centers in the lung has not been recorded by most researchers and they only noted cartilaginous centers. The only articles found by the authors that had mentioned ossification in the lung in ascites, is provided by Maxwell 1988. and Borst *et al.*, (1976) that suggested that the ossification center can be due to areas of ectopic primary bone formation.

Renal tubular necrosis may be the result of ischemia caused by decreased cardiac output (Wideman et al.,2013). As the chickens in the farms had a fast death process mineralization of renal tubules cited by other researchers was not seen our study.

Unlike what was reported by Rehnem et al., (1999) there were no food stuffed in the intestine in our study that can be due to this fact that most veterinarians in Iran recommend fasting as a cure for ascites. Dilatation of lymph vessels on the top of the intestine vilus seems to be related with fast development of the disease and sudden death.

Peripheral myositis with proliferation of connective tissue reported by Anjum (1998) and degeneration of myoocarium noted by Maxwell *et al.*, (1986) were not found in our study that can be due to rapid death of most cases. Julian(1998) in an experimental study on ascites did not observe any inflammatory reactions and concluded that inflammatory does not have any role in

ascites. Other findings in our study resembles those reported by other researchers (Gesek *et al.*, 2016; Sijun *et al.*,2012)

Changes in spleen were similar to other studies.

The results of present study demonstrate pathological changes in ascetic broilers that agree closely with those reported earlier.

Conclusion

Edema in the liver, congestion and myofibril degeneration in the heart, congestion and edema of the parenchyma accompanied with atelectasis and extensive dilatation in tertiary bronchus with cartilaginous mass and primary stages of ossification in the lung, heavy mononuclear cell infiltration in the spleen and necrosis, congestion, heavy infiltration of mononuclear cell in the intestine are the main features in ascetic broilers.

References

- Anjum R., Javed M.T. and Khan A. Pathophysiology of ascities syndrome in broiler chicken during winter under local conditions 1998; Pakistan veterinary journal, 1998; 18 (2):.68-73.
- Baghbanzadeh A, and Decuypere E. Ascites syndrome in broilers: physiological and nutritional perspectives. Avian Pathology, 2008 ;37(2):117-26.
- Gesek M., Otrrocka-Domagala I., Sokół R., Pazdzior-Czapula K., Lambert B.D., Wisniewska A.M., Żechowicz M., Mikiewicz M. and Korzeniowska P.Histopathological studies of the heart in three lines of broiler chickens. Poultry Science,2016;57(2):219-26.
- Itoh N., Moritsu Y., Taniyama H. and Ichikawa S. Correlation between heart muscle damage and high-nutrient feed in broiler chickens. Journal of Veterinary Medicine Science, 1997;59(3):209-11.
- Khodakaram Tafti A. and Karima M.R.. Morphological studies on natural ascites syndrome in broiler chickens. Veterinary archive, 2000; 70: 239-250
- Liu W.A. Trial Diagnosis of Ascites Syndrome in Broiler Chickens. Pak Journal of Biological Science, 2016; 19(8-9):352-359.

- Nakamura K., Ibaraki Y. and Mitarai Z. Comparative pathology of heart and liver lesions of broiler chickens that died of ascites, heart failure, and others. *Avian Disease*, 1999; 43(3):526-32.
- Rehman H., Khan A. and Khan M.C. Clinical, gross and histopathological observations in spontaneous cases of ascites syndrome in broiler chickens reared at low altitude, 1999; 19(3):115-118.
- Sakumi A., Yamaguchi M., Tottori J., Uchida K. and Tateyama S. Liver capsule thickening characterized by mesothelial cell proliferation with vascularization in broilers ascites syndrome. *Avian Pathology*, 1996 ; 25(1):147-53.
- Sijun Y., Dingzong G. and Bao Y. An Histopathology of the lymphatic system in ascetic broilers. *Veterinary Medicine – Czech*, 2002; 47(9):264-269.
- Wideman R. F., Rhoads D.D., Erf G.F. and Anthony N.B. Pulmonary arterial hypertension (ascites syndrome) in broilers: a review. *Poultry Sci*, 2013; 92(1):64-83.
- Wilson J.B., Julian R, J. and Barker I.K. Lesions of right heart failure and ascites in broiler chickens. *Avian Disease*, 1988; 32(2):246-61.
- Yang F., Cao H., Xiao Q., Guo X., Zhuang Y., Zhang C. and Wang T. Transcriptome Analysis and Gene Identification in the Pulmonary Artery of Broilers with Ascites Syndrome. *PloS One*, 2016; 11(6).