

## Pathological findings of slaughtered sheep kidneys in Noorabad abattoir, Iran

Mahjoor, A.A.<sup>1\*</sup>, Hosseinzadeh H.<sup>2</sup>

1-Department of pathology, Kazerun Branch, Islamic Azad University, Kazerun, Iran

2. DVM, Department of pathology, Kazerun Branch, Islamic Azad University, Kazerun, Iran.

**\*Corresponding author:** A.A. Mahjoor, Department of pathology, Kazerun Branch, Islamic Azad University, Kazerun, Iran, *E-mail:* [amir.mahjoor@gmail.com](mailto:amir.mahjoor@gmail.com)

(Received: January 8, 2018; Accepted: August 14, 2018)

### Abstract

This study was carried out to determine type and prevalence of kidney lesions in sheep in Noorabad city, south of Iran. A total number of 500 clinically normal sheep of different age, sex and breeds referred to Noorabad abattoir were selected. After slaughter the kidneys of these sheep were inspected and renal samples were taken for histopathological study. Twenty-nine out of the studied kidneys had Renal lesions including Interstitial Nephritis in 12 cases, Hemorrhage and Hyperemia in 4 cases, Abscess in 4 cases cysts, Acute tubular necrosis in 3 cases, Glomerulonephritis in 2 cases, Medullary crest necrosis, and Cloisonné kidney were observed in one case. The prevalence of renal lesions in female and male cattle didn't have any significant difference.

**Key words:** *Sheep, interstitial nephritis, Acute tubular necrosis,, glomerulonephritis, Medullary crest necrosis, Cloisonné kidney.*

### Introduction

Sheep rearing is one of the major sources of sustainable life of rural areas in Iran and has a great economic value in terms of meat, wool and other its byproducts. Generally, kidneys excrete the end products of tissue metabolism and maintain fluid, electrolytes and acid-base balance via varying the volume of water and concentration of solutes in urine (Kojouri *et al.*, 2014).

Kidney disorders are common in sheep. These disorders are not easily detectable in animals until some complication occurs (Majid *et al.*, 2017). However, most renal lesions are subclinical and they might have remarkably higher frequencies than expected. Such lesions could result in the poor production of the involved animals (Kojouri *et al.*, 2014). These diseases have an important economic impact on animal productivity, reduced growth, and drug costs. Additionally, kidneys are considered as an edible organ in Iran and their condemnation due to misinformation results in economic losses.

Examination of kidneys at slaughter is the only way to understand pathology behind kidney disorders and prompt diagnosis (Mahouz *et al.*, 2015). This abattoir survey on sheep kidney lesions in Noorabad slaughterhouse can be a good model of renal disorders and clinical diseases of kidney in the sheep farms and could enhance prevention and treatment protocols of sheep urinary diseases.

## Materials and methods

This survey was carried out in Noorabad city, Fars province, south of Iran in autumn and winter 2017 and spring 2018. The study was conducted by collecting 1000 kidney samples of 500 sheep. After slaughtering, animals were thoroughly examined for gross lesions presence on the kidneys. The kidneys were carefully inspected and their appearance and size of abnormalities were recorded. In the second phase, longitudinal sections were made on the kidneys for identification of lesions in sub-capsular, cortical, and medullary sections. Renal crest, medullary pyramids, and renal pelvis were carefully examined for determination of necrosis, hemorrhage and calculus presence. In case any macroscopic features of the lesions were found, they were recorded on special sheets designed for this study. General condition and sex of each animal were recorded too. Samples of the lesions were collected in %10 formalin buffer and were referred to histopathology lab. The formalin fixed pieces of tissues were processed by paraffin embedding technique. The tissues were properly trimmed, washed in running tap water, dehydrated in graded ethyl alcohol, cleared in xylene and embedded in paraffin wax. Sections of 45-7  $\mu$  thickness were cut using microtome and stained with standard haematoxylin and eosin stain. The data was analyzed statistically using Chisquare test with 95% confidence levels ( $p < 0.05$ ) (Nourmohammadzadeh *et al.*, 2010).

## Results

Results indicated that prevalence of renal lesions in slaughtered sheep kidneys were 0/029 (29 out of 1000). The prevalence of renal lesions in female and male sheep were 0/018, and 0/011 respectively, which was notable statistically significant difference ( $p < 0.05$ ). Type and prevalence of sheep renal lesions found in this study are presented in table 1.

**Table 1.** Type and frequency rate of microscopic acquired disorders of sheep kidneys based on sex

Disorder	Total frequency	Frequency in males	Frequency in female	Relative frequency
Interstitial nephritis	12	3	9	•/•٢
Hemorrhage and hyperemia	4	3	1	•/•٤
Abscess	4	1	3	•/•٤
Acute tubular necrosis	3	1	2	•/•٣
Renal cysts	2	1	1	•/•٢
glomerulonephritis	2	1	1	•/•٢
Medullary crest necrosis	1	0	0	•/•١
Cloisonné kidney	1	1	1	•/•١

Grossly, kidneys with interstitial nephritis were slightly enlarged with pale grey color. Histologically, kidneys showed infiltration of lymphocyte and plasma cell in their interstitial tissue with degenerative changes in the proximal and distal convoluted tubules. On gross examination, kidney hemorrhages in sheep varied from petechial to ecchymosis form. Histopathological examination of kidney showed different size sub capsular and interstitial hemorrhages and mononuclear cell infiltration that caused atrophy of glomeruleis. Gross examination of kidneys with acute tubular nephritis revealed slightly enlarged and pale kidneys with a smooth capsular surface. On microscopic examination, kidneys showed degeneration and in kidneys with acute tubular necrosis coagulative necrosis and apoptosis of epithelium: of proximal and distal convoluted tubules with desquamation of cells into lumen; dilated proximal tubules with loss of brush border and presence of hyaline casts in distal and collecting ducts were noted. Kidneys affected with Glomerulonephritis were enlarged and pale their capsule peeled off easily and presence of red dot on the cortex was noted. Histologically glomerular lesions were of various types, proliferative, membranous and membrano-proliferative types. Glomerular tufts were increased in size with hyperplasia of endothelial and mesangial cells leading to hypercellularity of glomerulus and narrowing of bowman's space. Proximal convoluted tubules contained hyaline droplets, reflecting protein reabsorption. Degeneration of renal tubules and influx of inflammatory cells in interstitial tissue were also noted. Renal abscess was found in 4

cases as displayed in figure 1. The abscess had different size and usually contained creamy color pus.

## Discussion

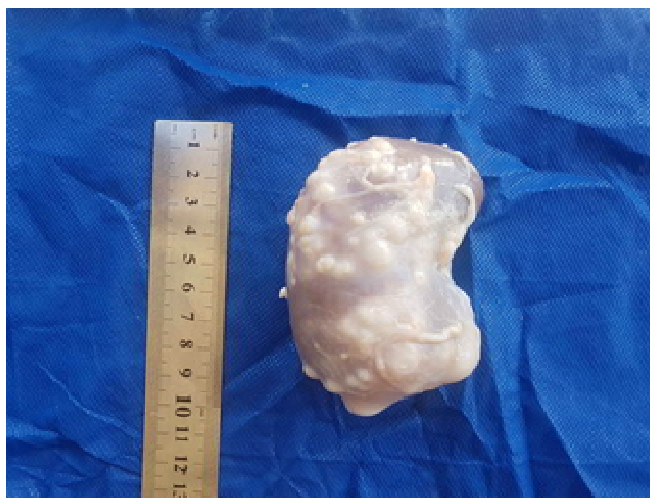There are few surveys on kidney disease in slaughtered food animals most of which were conducted to detect pathogenic bacteria and to trace heavy metals or drug residues (Ansarilari, 2007). Out of 450 sheep studied at Tiaret abattoir by Maouz *et al.* (2015) fifty five (22.66%), sheep had renal lesions including interstitial nephritis, glomerulonephritis, Acute Tubular Necrosis (ATN), epithelionepritis, cysts and amyloidosis. Interstitial nephritis was the most common observed lesion (7.77%) in sheep. Dutta *et al.* (2016) carried out an abattoir survey of sheep kidneys in Jammu and reported lesions in 27 out of 300 kidneys. Prominent gross lesions in these kidneys included haemorrhage, infarction, hydronephrosis, amyloidosis and nephritis. Baghban and Yaripoor (2016) reported a 0.8% (106/13206) rate of kidney condemnation in sheep in Yasuj city, the center of Kohgiluyeh and Boyerahmad. According to histopathological findings, interstitial nephritis was the most renal lesion noted. A survey of the prevalence and type of sheep kidney lesions was carried out on 2000 kidneys in Brujen abattoir by Karimi *et al.* (2001). Sixty (0.3%) kidneys were rejected for gross abnormalities. The most common reason for rejection was interstitial nephritis (60% of rejected kidneys). Other lesions included renal pigmentation (18.33%), urinary cyst (8.33%), hydatid cyst (6.66%), amyloidosis (3.33%) and hemorrhage (3.33%). Ansari-Lari (2007) reported 1.1% of sheep kidneys were condemned in Shiraz abattoir during 1999 to 2004. Jibat *et al.* (2008) reported nephritis as the major pathological lesion in sheep kidneys accounting for 48.4%. Similarly, Woube (2008) observed nephritis as the principal cause for condemnation in sheep. Significant efforts have been made to replace traditional sheep rearing with industrial farms. The lower rate of kidney disorders in this current study compared to similar above-mentioned studies can be due to the efficiency of the industrial sheep rearing systems as well as overall improvement in term of rearing systems and veterinary services. There was no significant difference between male and female sheep in this study. Female animals are predisposed to urinary tract infection because of their short urethra, urethral trauma, possibly hormonal effects and more reproductive system infection (Nikvandmet *al.*, 2014). On the other hand, as Noormohamadzadeh *et al.* (2010) mentioned, it

appears that age is a more important influence on renal pathology than gender. Kojouri *et al.* (2014) noted that nephrosis may occur as a result of high doses administration of aminoglycosides antibiotics (such as gentamycin) and non-steroidal anti-inflammatory drugs like flunixinmeoglumine and phenylbutazone. These kind of drugs are widely used by veterinarians in the area, which can explain the high rate of disorders like interstitial nephritis and ATN in this survey. Interstitial nephritis was the most common lesion found in this study. Interstitial nephritis is rarely recognized as a cause of clinical disease in farm animals although it is a frequent post mortem finding in some species (Mahouz *et al.*, 2015). Interstitial nephritis can be focal or have a diffuse distribution (Tavassoly, ۲۰۰۳). Focal interstitial nephritis is also called white spotted kidney by veterinary inspection staff and is caused by a variety of pathogens, but is mostly related to current or prior *leptospira* spp. infection (Dorjee *et al.*, 2009; Divers, 2002). Considering that leptospirosis is a zoonotic disease and leptospirosis is recognized both clinically and serologically in Fars province (Poujafar *et al.*, 2012), Further studies are required on the role of *leptospira* spp. infection in the sheep and its role in causing interstitial nephritis in this area. Sheep-pox may develop same lesion that is fairly common in Noorabad province. Common causes of ATN include low blood pressure and use of nephrotoxic drugs (Radostitis *et al.*, 2007). Maxie and Newman (2007) also indicated that acute tubular necrosis occurs due to various endotoxemic conditions, such as mastitis or metritis, and in gastrointestinal diseases, such as severe enteritis and grain overload. Glomerulonephritis develops through an immune-mediated mechanism which is either by development of antibodies against glomerular basement membrane or deposition of soluble immune complexes within the glomeruli. Second type of glomerulonephritis occurs with prolonged anti anemia that associates with persistent infections (Maxie & Newman, 2007). There was an association between parasitic infestation and glomerulonephritis as they found that sheep suffered from hydatidosis developed glomerulonephritis (Majid *et al.*, 2017). Renal abscess occurs via the hematogenous route and several pathogens are encountered in the development of lesions such as *Corynebacterium pseudotuberculosis* in small ruminants (Radostitis *et al.*, 2007; Yerham *et al.*, 2006) Renal cysts are a common disorder in sheep kidney. These cysts are usually found in necropsy and are unnoticed in live animals. Polycystic kidneys may cause no clinical signs or lead to progressive

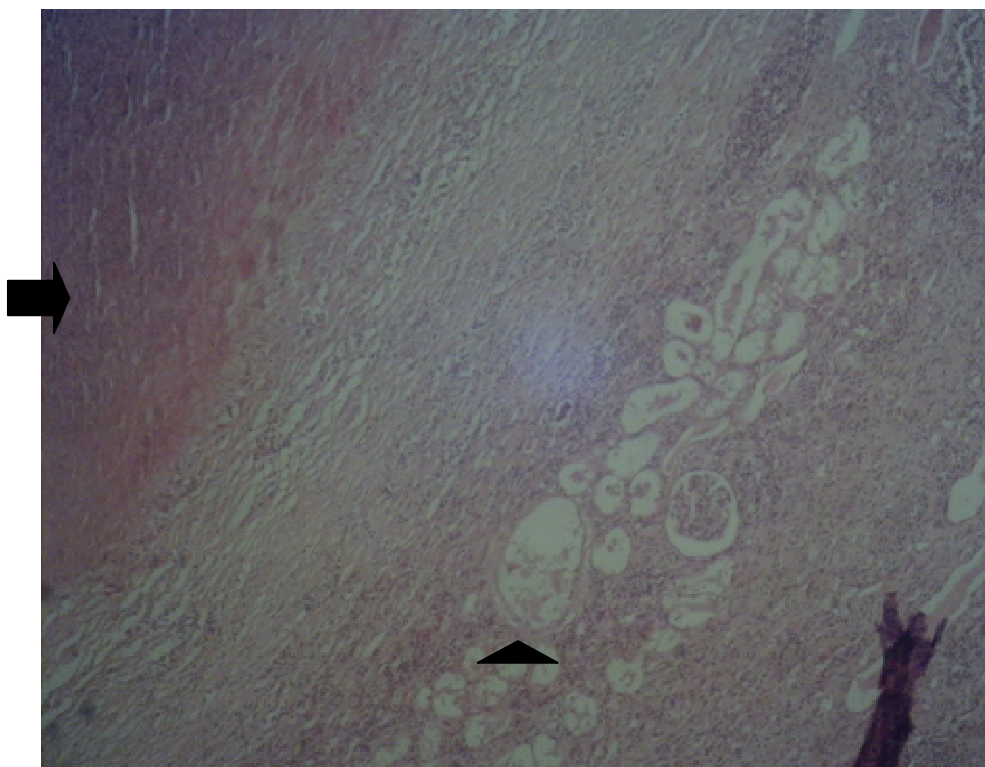
renal failure (Karimi *et al.*,2001). These cysts can be acquired or congenital. Most of the cysts found in this survey were smaller than 4 mm, so they were considered as acquired cyst. The exact cause of Cloisonne kidney remains unknown but intravascular hemolysis is considered to have a role (Khaki 2016). Khaki (2016) reported 0.059% frequency rate of Cloisonné kidney in Tabriz and Rasht. In the case of current study deposition on basement membrane was seen only in proximal and tubule but Oryan *et al.* (1993) and Khaki (2016) reported that this kind of pigmentation was seen in proximal and distal convoluted tubules.

In conclusion, given that this study was conducted on apparently healthy animals, the hypothesis that subclinical losses from renal lesions are not negligible in sheep populations may be correct.

As discussed above, renal insufficiency can be caused by many conditions which their causes are difficult to determine. Thus, abattoir surveys like the present study may play important roles in such areas to find the high frequency lesions and make a solid plan to avoid or prevent exposure to probable etiological agents.

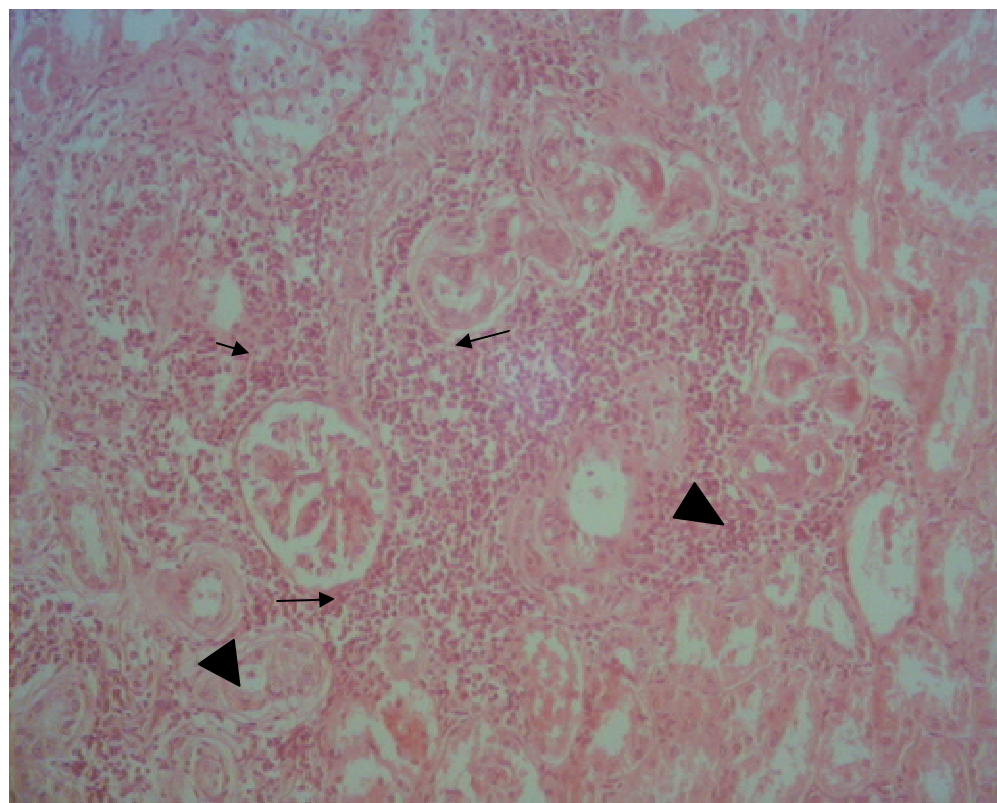


**Figure1.** Diffuse abscess on the kidney surface



**Figure2.** Histopathological picture from kidney in figure1, Couagulative necrosis and fibrosis around it that form the abscess (arrow), Necrosis of glomerulus and dilation of tubules (arrow head) and infiltration of mononuclear cells are also seen (H&E X100).





**Figure 3.** Tubulointerstitial nephritis: Infiltration of mononuclear cells (small arrows) and ATN (arrow heads) (H&E X100)

## References

- Ansari M. Abattoir Survey of Kidney Condemnation in Food Animals in Shiraz, South of Iran (1999-2004). *International Journal of Dairy Science*, 2007; 2: 100-103.
- Baghban F. and Yaripour H. Histopathological lesions of condemned kidneys of sheep and goats slaughtered in Yasuj Abattoir, Iran. *Indian Journal of Veterinary Pathology*, 2016; 40(4) : 356-358.
- Divers TJ. Interstitial nephritis. *Large Animal Internal Medicine*, edited by Smith, B.P. Mosby publication, Philadelphia, 2002; PP:534-548.
- Dorjee S., Heuer C., Jackson R., West DM., Collins-Emerson JM, Midwinter AC. and Ridler AL. Are white-spot lesions in kidneys in sheep associated with leptospirosis. *New Zealand Veterinary Journal*, 2009; 57(1):28-33 .
- Jibat T., Ejeta G., Asfaw Y. and Wudie A. Causes of abattoir condemnation in apparently healthy slaughtered sheep and goats at HELMEX abattoir, DebreZeit, Ethiopia. *Revue de Médecine Vétérinaire*, 2008; 159(5): 305-311.
- Karimi I., Kojouri A. and Rofei MA. Histopathologic survey of sheep rejected kidneys in Brujen abattoir. *Pajouhesh & Sazandegay*; 2001; 73: 142-146.



- Khaki A. Study of cloisonne kidney lesion frequency in slaughtered sheeps of Tabriz and Rashta slaughterhouse. *Veterinary Clinical Pathology*, 2016;10( 38):121-126.
- Kojouri GA., Norani H., Sadeghian S., Imani H. and Raeisi A. Pathological findings of slaughtered cammels in Najaf-Abad,Iran. *Veterinary Research Forum*, 2014; 5 (3) 231 – 235.
- Maxie, GM. and Newman SJ. Urinary system In: Jubb, Kennedy and Palmer's *Pathology of Domestic Animals*, 5 ed, Ontario: Elsevier Saunders,2007: PP: 425-522.
- Mahouz F., Benchaib KhoudjaF. and Chikhaoui, M. Pathological Study on Renal Diseases in Cattle and Sheep. *Journal of Animal and Veterinary Advances*, 2015; 14: 357-360.
- Magid M., Faten F., Mohammed M., Elmady AM. and Mokhtar H.Characterization of Renal Lesions Developed in Some Ruminant Species in Egyptian Slaughter House. *Research Journal of Pharmaceutical, Biological and Chemical Sciences*, 2017;8(3):1837-1840..
- Nikvand, AA. Haji Hajikolaei, MR.Ghadrdanmashhadi, A. and Ghorbanpour M. Bacteriological study of urine and its relationship withhistopathological findings of bladder and kidney in riverbuffalo (*Bubalus bubalis*). *Iranian Journal of Veterinary Medicine*, 2014;8(3):157-161.
- Nourmohammadzadeh, F., Haji Hajikolaei MR., Sasani F. and Alidadi, N. Abattoir study of the prevalence of renal lesions in slaughtered cattle.*International journal of veterinary research*, 2010; 4(3):173-175.
- Oryan A., Razavi, M. and Maleki, M.Observations on Cloisonné Kidney in Sheep. *Newzeland Veterinary Journal*,1993;41(4): 210-214.
- Pourjafafar M., Badei K. and Ghanei M.Bovine leptospirosis in Fars province: Implications for transmission to human beings. *Iranian Journal of Public Health*,2012: 40:16.
- Radostits DM., Gay CC., Hinchcliff KW and Constable P.D. *Veterinary medicine: A textbook of the diseases of cattle sheep, pigs, goat sand horses*, 10 ed. W. Saunders,Philadelphia, PP: 789-790 . 2007
- Tavassoly A. Pathological Study of Renal Lesions in the CondemnedBovine Kidneys in Ziaran Slaughter-house. *Archives of Razi institute*, 2003;55:94-97.
- Woube EG. Causes of abattoir condemnation inapparently healthy slaughtered sheep and goats at HELMEXabattoir, DebreZeit, Ethiopia. *Revue de Médecine Vétérinaire*, 2008;159:..305-311.
- Yeruham I., Elad D., Avidar Y. and Goshen TA. Herd level analysis of urinary tract infection in dairy cattle. *Veterinary journal Journal*, 2006; 171: 172-176.