

An Investigation into the Effects of Aqueous Extract of *Carum Copticum* on Renal Tissue and Uric Acid in Male Wistar Rats

Niyakan, M.¹, Akbarpour, B^{2*}, Khoshvaghti, A.³

¹Msc in Animal Physiology, Department of Biology, Kazerun Branch, Islamic Azad University, Kazerun, Iran;

²Department of Physiology, Faculty of Veterinary Medicine, Kazerun Branch, Islamic Azad University, Kazerun, Iran; ³Department of Clinical Sciences, Faculty of Veterinary Medicine, Kazerun Branch, Islamic Azad University, Kazerun, Iran.

* **Corresponding Author:** B. Akbarpour, Department of Physiology, Faculty of Veterinary Medicine, Kazerun Branch, Islamic Azad University, Kazerun, Iran, *E-mail:* bijanakbarpour@yahoo.com

(Received: June 25, 2017; Accepted: September 2, 2017)

Abstract

Of the nine chemical compounds identified in the *Carum Copticum* extract, thymol, γ -terpinen, and parasaymn are considered as the main compounds utilized as antiemetic, anti-asthma, anti-nausea, and spasmodic, locally used in the treatment of rheumatic pains with therapeutic effects on skin diseases, mental disorders, and genitourinary diseases. The recent scientific studies have confirmed the antiseptic impact and decreasing effects of blood cholesterol in this plant. For the purpose of this study, 72 male Wistar rats were divided into 6 groups as control, sham, and experimental groups (1 to 4). While the control group received no treatment, sham group received 2/0 ml of distilled water and experimental groups (1 to 4) took daily 200, 400, 600 and 800 mg /kg aqueous extract of *C. copticum* as intraperitoneal injection, respectively. After a lapse of 16 and 32 days, rats' blood samples were taken. The kidneys, belonging to rats died during blood sampling after day 16 and the rats remained alive after the day 32, were removed and their uric acid and renal histology were examined. The collected data then were analyzed using SPSS statistical software package. In this study, statistical tests such as one way ANOVA, and post hoc Duncan were carried out. P-value of less than 0.05 was regarded as statistically significant ($p < 0.05$). The findings revealed that the use of aqueous extract of *C. copticum* in a low dose and short and long terms results in a body weight loss and with a moderate and high dose only in long term leads to a body weight loss. Regardless of the dose, the use of such extract in short and long terms increases the kidney function. In all groups, the kidney tissue in short and long terms was completely normal with no damage. As a conclusion, this study demonstrates that the use of *C. copticum* extract, with no adverse effect on renal tissue, causes an increase in kidney function, though the effects of these extracts will be somehow different in details in short and long terms.

Keywords: *Carum Copticum*, uric acid, kidney tissue

Introduction

Carum copticum is a medicinal plant with the scientific name of *Carum copticum* Heirn belonging to *Umbelliferae* family and *Trachyspermum copticum* genus and the Latin name of the species *Ajowan* is also similar to the local pronunciation *Sistani ajqu*. It is an annual, herbaceous and cross-pollinated plant, with fruit used as

medicine containing 2-5 percent essence. In tradition medicine, it is used as anti-asthma, pain killer, calming, antimetic, expectorant, and in treating stomach and liver disorders (Zahin et al., 2010; Sharifi and Shafaghat, 2014). The main components of this plant contain thymol, cymene, α -pinene, dipentene, γ -terpinen, β -pinene, sabinene, myrcene, and carvacrol (Hosseinzadeh and Mehrabi, 2003; Komeili and Sargazi, 2012). The other chemical components are protein and oil, and cations as sodium, potassium, iron, calcium, magnesium, zinc, copper, and cobalt. Among the 9 chemical components recognized in *Ajowan* essence, the main components are known as thymol, γ -terpinen, and parasaymn, and the smell is caused by the seeds of its thymol (Ashrafi-tamai et al., 2013; Jafari, 2004; Bairwa et al., 2012).

Uric acid is an organic compound composed of carbon, oxygen, nitrogen with chemical formula as $C_5H_4N_4O_3$. In humans, the final compound of purines catabolism is uric acid formed through intermediate metabolites as hypoxanthine and xanthine under the influence of xanthine-oxidase. The level of uric acid depends on age and sex. Before maturation, the average level of serum uric acid for men and women is $.63 \text{ Mg /dL}$ but after puberty in women, uric acid level will be decreased due to an increase in the estrogen level. Many other factors including exercise, diet and narcotics may affect the growth of uric acid level. Uric acid is a major contributor to decreasing antioxidant enzymes.

One of the most important biochemical indicator used to evaluate the kidney function is uric acid. In fact, uric acid is regarded as one of the most essential antioxidants in the blood which can decrease the oxidative stress through excretion of free radicals of oxygen (Carl et al., 2008). Kidneys will perform their most important tasks by purifying the plasma and removing the material from the filtrate depending on the body needs. Finally, the kidneys will purify the filter and blood by removing the unwanted substances through the urine, at the same time turning the necessary materials for the body back to the blood. The kidneys are the main ways to dispose the metabolism waste products that are no longer needed for the body. In the case of renal failure, uric acid is among the substances that its level in the blood will be increased (Abdul Hamid et al., 2012).

Urinary organ is one of the most essential organs in the body functioning as secretion and excretion of unnecessary and toxic compositions in the body, preventing the extraction of vital substances (Guyton and Hall, 200). The formation of urine is the result of glomerular filtration, tubular reabsorption and tubular secretion. The kidneys are responsible for the exertion of waste materials produced on the basis of metabolism. Uric acid is the end product of decomposition of hemoglobin and various metabolites from this category (Yman and Balikei, 2010). Renal failure occurs when the clinical symptoms or laboratory abnormalities are displayed as a result of a decrease in kidney function (Guyton and Hall, 200).

Regarding the common use of *Ajowan* and also inadequate studies on its impact on kidney function, the present study is an attempt to detect the absence of adverse effects of long-term use and high doses of this herb on kidney.

Materials and Methods

For the purpose of this study, 72 adult male Wistar rats, weighing approximately 20 ± 200 g were maintained under standard conditions of 12-hr light-dark cycle, with temperature 22 ± 2 °C and relative humidity of 40-60%. The same ration and water were freely available to all animals. After one week getting accustomed to the new conditions, trial on animals began. The present experimental study has been carried out in 1395 at the Research Center, Islamic Azad University, Kazerun branch, Iran, and all ethical considerations and protocols with respect to laboratory animals have been observed. The pure and fresh seeds of *C. copticum* were prepared from a valid herb apothecary in Shiraz.

The seeds were used after being approved by the University of Medical Sciences, Shiraz, Iran, and the College of Agriculture Herbarium. Preparation of extract from *C. copticum* was performed by percolation method using high-pressure (Hejazian et al., 2009).

The rats were randomly divided into 6 groups, 12 in each group as follows: The control group received no treatment. The sham group received 2/0 mm distilled water. Experimental groups 1 to 4 received intraperitoneal daily injection of 200, 400, 600, and 800 mg/kg of aqueous extract of *C. copticum*, respectively, for 32 days. In this study, blood sampling was done at the end of the days 16 and 32. The rats were anesthetized by diethyl ether solution kept in a glass plate. In the first phase of blood sampling from the heart (end of the day 16, to examine the short term effects of the extract), while examining heart beats, the rat was placed on a surface and directly from the skin the blood was taken from the heart (cardiac puncture) through a 5 cc syringe. In this stage, the rats died due to an injury to their hearts were used for renal tissue sampling. In the second phase of sampling (end of the day 32, to assess the long term effects of the extract), after the autopsy of rats, cardiac puncture was performed by syringe and renal tissue sampling was also carried out. Blood samples were kept into serological tubes and in the same day, serum was separated by centrifuging (2500 rpm speed for 6-7 min and at 20°C). Serums were stored and maintained at -20 °C until for the uric acid to be assessed. Rats' kidneys were carefully removed and rinsed in physiological serum. Dissected kidneys were fixed in 10% neutral buffer formalin solution. Finally, the sample tissues were dehydrated and molded, and microtomy sections were prepared. The sections were stained with Haematoxylin and Eosin (H&E) and then examined microscopically for recording the histopathological alterations. A quantitative assessment of uric acid concentration were measured by fully- automatic auto analyzer (Technico R -1000, USA) and Pars Azmoon kits (Iran). All data were specified as mean \pm SD and data analysis were performed using SPSS version 16 calculating statistical tests as one way ANOVA, post hoc Duncan. The level of significance for all tests was considered as $p < 0.05$.

Results

As shown in Tables 1 and 2, different doses of aqueous extract of *Ajowan* in short and long terms resulted in an increase in uric acid level. However, a significant statistical difference was observed only between the average level of uric acid in the experimental groups 1 and 2 compared to the control group.

Table 1: Comparison of mean value and standard deviation of uric acid level on days 16 and 32 in rats treated with aqueous extract of *C. copticum*

U. Acid after 32 days (mg/dl)	U. Acid after 16 days (mg/dl)	Experimental Groups
2.69±0.18	2.69±0.18	Control
2.64± 0.18	2.64± 0.18	Sham
4.15± 0.12*	4.15± 0.12*	Treatment 1
3.80± 0.29*	3.82±0.26 *	Treatment 2
3.79± 0.04	3.89±0.26	Treatment 3
4.70± 0.24	3.89±0.31	Treatment 4

The values are based on (Mean ± SEM). p <0.05 is considered as significant level.

* Asterisk indicates a significant difference from the control group (P<0.05)

Table 2: Existence or non-existence of a significant statistical difference between the mean value of uric acid level in different groups compared to the control group on days 16 and 32

U. Acid after 32 days (mg/dl)	U. Acid after 16 days (mg/dl)	Experimental Groups
1.000	1.000	Control
0.003	0.00	Treatment 1
0.004	0.012	Treatment 2
0.005	0.007	Treatment 3
0.000	0.000	Treatment 4

The values are based on (X ± SEM). p <0.05 is considered as significant level.

* Asterisk at the top of the columns indicates a significant difference from the control group (P<0.05).

No significant differences were observed between uric acid level on day 16 in comparison with day 32 in the experimental groups 1 to 3 (P<0.05). In the experimental group 1, uric acid level in 32 days after rats treatment revealed a significant decrease compared to the uric acid level after 16 days of treatment (P<0.05).

Results related to the study of the experimental effect of aqueous extract of *C. copticum* with different levels on kidney tissue

The histological studies showed that in the control group, the sham group, and in the four experimental groups, on days 16 and 32, the kidney tissue was completely normal with no injury, with the kidney glomeruli and tubule keeping their natural structure. The histological findings suggested that no abnormality had been observed in thirty two-day- use of *C. copticum* extract.

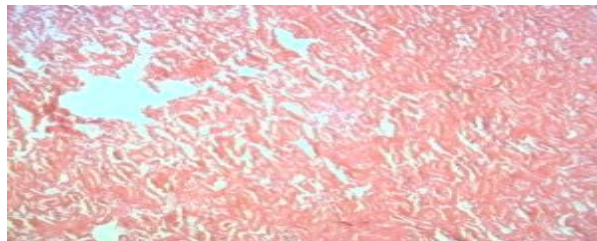


Figure1. Photomicrograph of rat kidney tissue in the control group, day 16 (H&E, 100 ×)

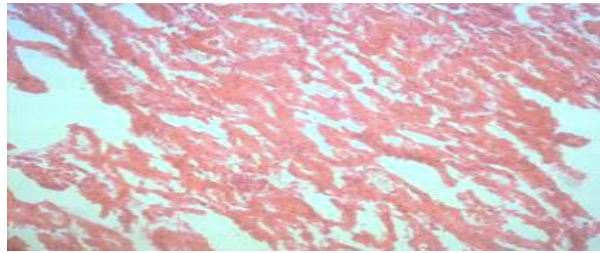


Figure 2. Photomicrograph of rat kidney tissue in the control group, day 32 (H&E, 100 ×)

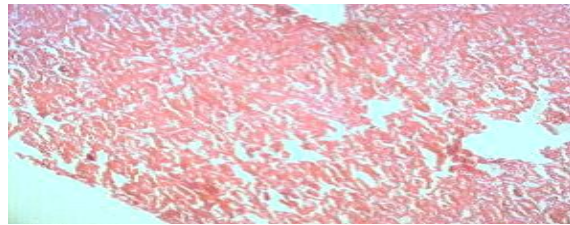


Figure 3. Photomicrograph of rat kidney tissue in the sham group, day 16 (H&E, 100 ×)

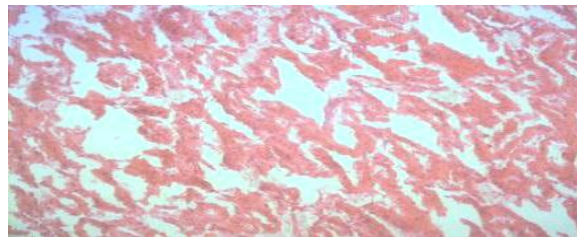


Figure 4. Photomicrograph of rat kidney tissue in the sham group, day 32 (H&E, 100 ×)

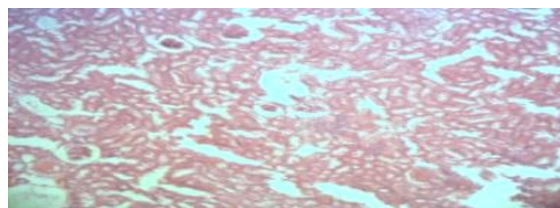


Figure 5. Photomicrograph of rat kidney tissue in the experimental group 1, day 16 (H&E, 100 ×)

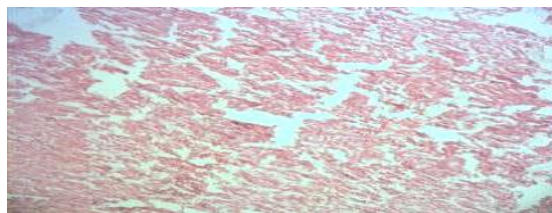


Figure 6. Photomicrograph of rat kidney tissue in the experimental group 1, day 32 (H&E, 100 ×)

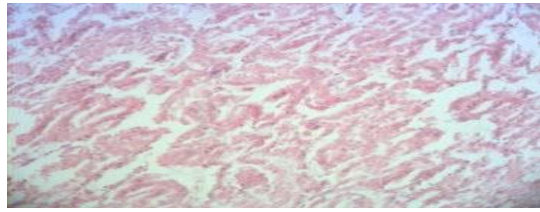


Figure 7. Photomicrograph of rat kidney tissue in the experimental group 2, day 16 (H&E, 100 ×)

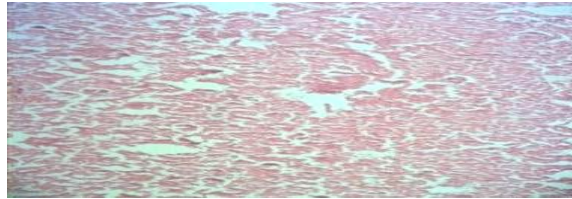


Figure 8. Photomicrograph of rat kidney tissue in the experimental group 2, day 32 (H&E, 100 ×)

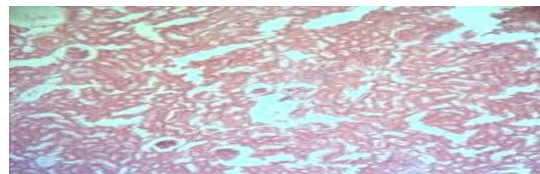


Figure 9. Photomicrograph of rat kidney tissue in the experimental group 3, day 16 (H&E, 100 ×)

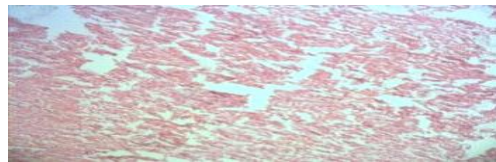


Figure 10. Photomicrograph of rat kidney tissue in the experimental group 3, day 32 (H&E, 100 ×)

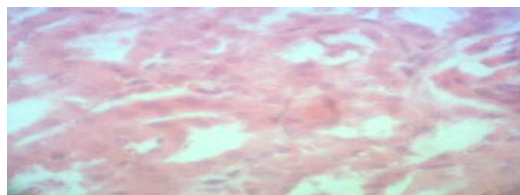


Figure 11. Photomicrograph of rat kidney tissue in the experimental group 4, day 16 (H&E, 400 ×)

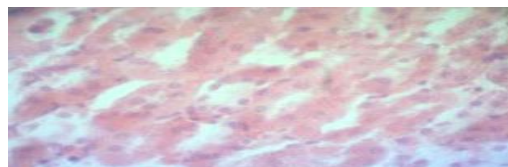


Figure 12. Photomicrograph of rat kidney tissue in the experimental group 4, day 32 (H&E, 400 ×)

Discussion

As the findings revealed in the present study, a statistically significant increase was observed between the mean value of uric acid level on days 16 and 32 in the control group compared to the experimental groups under study ($P < 0.05$). Though the reported significant increase of mean related to uric acid level in the experimental groups in comparison with the control group was an indicator of renal failure, the failure resulted from the use of different doses of *C. copticum* was not enough to damage kidney tissue. In this regard, the histological studies also proved the healthy condition of kidney tissues. Thus it could be concluded that an increase in uric acid level, which was due to the use of *C. copticum*, would be related to the existing dehydration, but not a decrease in the kidney function. To ensure the issue, the measurement of the serum creatinine would be helpful.

In a study, Kanter and his colleagues reported that the black cumin oil extract (*Nigella sativa* L.) protected the kidneys from the damage caused by oxygen free radicals, with a decrease in lipid peroxidation (Kanter et al., 2004). The results of a histological study indicated that the intake of rosemary aqueous extract resulted in a significant decrease in the vascular congestion, and Bowman's capsule space (Changizi-Ashtiyani et al., 2013).

Several mechanisms are responsible for nephrotoxicity, including the production of reactive oxygen species (ROS), especially hydroxyl radicals which causes lipid peroxidation, cell membrane degradation, proteins oxidation, nucleic acids, and tissue degradation; the result is the reduction of glomerular filtration, creating acute nephrotoxicity. The development of oxidative stress causes a decrease in the accumulation of cellular glutathione and an increase in reactive oxygen species, ultimately destroying tubules and creating nephrotoxicity.

The cellular antioxidant enzymes such as superoxide dismutase, catalase, peroxidase, and glutathione protect cells and tissues against harmful radicals. A decrease in the activity of this antioxidant enzymes causes an increase in free radicals thereby it increases the level of lipid peroxidation, tissue degradation and inflammation (Barr, 1990).

Peroxidation of the lipids in cellular membrane leads to membrane perforation. Moreover, lipid peroxidation plays a key role in the production of free radicals and oxidative stress in diabetics (Washington and Hoosier, 2012).

As the findings reveal in the present study, uric acid levels show an increase in all 4 groups and in both short and long term periods. Many medications can change serum uric acid levels through their effect on the tubular duct in the nephrons. The increase of serum uric acid levels can be due to the kidney damage that results from the oxidative activity of the drug (Karimi, 2004). Some studies show that antioxidants play an important protective role against radicals, inhibiting the production of radicals, and preventing the increase of serum levels of uric acid, lipid cholesterol and blood glucose levels (Karimi, 2004).

Treatment with ginger in diabetic rats prevents deficiency or loss of antioxidants concentration and antioxidant enzymes in the kidney tissue. Polyphenol and flavonoid in the hydroalcohol extract of ginger are responsible for the protective and antioxidant activities in the kidney tissue (Ajith et al., 2007).

Lead acetate is a peroxidation agent, and peroxidation damage to the lipids in cellular membrane leads to membrane perforation ultimately causes the destruction of kidney tubular tissue which prevents the proper kidney function through the effect of free radicals on peroxidation of the lipids in cellular membrane and atrophic renal

tissue which results in an increase in the concentration of renal excretion factors in blood serum. Nephrotoxicity usually appears with an increase in serum uric acid levels (Chauhan et al., 2010; Elsaid and Elkomy, 2006).

Thymol and carvacrol have antioxidant properties, and they also cause the increase of glandular secretion of the digestive system. In addition, carvacrol can weaken the inflammatory processes through suppressing the gene expression, thus resulting in a reduction in tissue damage (Abdelhalim et al., 2013; Zahin et al., 2010).

Jamali and his colleagues reported that the protective effect of garlic on the kidney was due to its antioxidant properties, because various types of oxidation reactions showed negative effects on glomerular filtration rate. Due to its antioxidant and protective properties, garlic can remove the lead toxic effects on the kidney tissue (Jamali et al., 2014).

It is demonstrated that *Ajowan* contains antioxidant compounds such as phenolic compounds, the most important of which are thymol and carvacrol (Gilani et al., 2005; Takahashi et al., 2003). Various biological effects can be attributed to these compounds including anti-inflammatory, anti-leishmanic, anti-microbial, anti-cancer and antioxidant effects (Gilani et al., 2005).

Abdul-Hamid and colleagues studied the rats with kidney damage. They found that ethyl acetate extract of ginger has significant protective effects on the kidney against high-dose paracetamol that it may be due to the intermediate antioxidant properties in the ginger (Abdul-Hamid et al., 2012).

Different types of natural antioxidants are polyphenols such as vitamins, pigmentation, and other polyphenols with properties such as anti-mutagenic, anticancer and a decrease in blood glucose (Verma and Asnani, 2007).

Due to the effect of sulfur content in the garlic extract, it is likely that the antioxidant properties of these substances prevent peroxidation of the lipids in the cell membrane and the destruction of the kidney tissue (Jamali et al., 2014).

It is said that compared to the control and sham groups, the group receiving the cadmium chloride shows a significant increase in the uric acid, leading to the destruction of the kidney tissue. Moreover, the extracts of *Oliveria decumbens* Vent plant alone do not show any significant change on body weight, kidney weight, serum uric acid concentration, as well as the kidney tissue compared to the control and sham groups while the groups receiving the extract display a decrease in cadmium chloride-induced nephrotoxicity. Antioxidants reduce the damage to the kidney tissue by blocking the oxidative pathways and lipid peroxidation, causing the flow of blood in the kidney, and thereby improving renal function (Abdelhalim et al., 2013).

In 2007, Varzi and his colleagues stated that the consumption of silymarin eliminates the nephrotoxic effects of gentamicin (Varzi et al., 2007).

In the present study, the results of histological studies showed that kidney tissue in the control, sham, and all 4 experimental groups were completely normal with no injury on days 16 and 32, with the kidney glomeruli and tubule keeping their natural structure. These histological findings suggest that there is no adverse effect in the use of *C.copticum* extracts even at maximum dose (800 mg/kg) which is consistent with the biochemical results.

Conclusion

This study revealed that different doses of *C. copticum* aqueous extract in short and long terms (with minor differences) caused an increase in the kidney function. In addition, the findings demonstrated that aqueous extract of *C. copticum*, even in doses higher than 800 mg / kg did not have any adverse effects on kidney and the lack of changes in renal tissue confirmed that.

Acknowledgement

We would like to thank the respectable authorities in Islamic Azad University, Kazerun, Iran, in the adoption and implementation of this research.

References

- Abdelhalim, MAK., Abdelmottaleb Moussa, SAT. (2013). The gold nanoparticle size and exposure duration effect on the liver and kidney function of rats: In vivo. *Saudi J Biol Sci.*, 20:177-81.
- Abdul- Hamid, Z., Budin, S.B., Wenjie, N., Hamid, A., Husain, K., Mohamed, J. (2012). Nephroprotective effects of Zingiber zerumbet Smith ethyl acetate extract against paracetamol- induced nephrotoxicity and oxidative stress in rats. *J. Zhejiang. Univ. Sci. B.*, 13:176-185.
- Ajith, T.A., Nivitha, V., Usha, S. (2007). Zingiber officinale roscoe alone and in combination with Alpha-tocopherol protect the kidney against cisplatin induced acute renal failure. *Food chem. Toxicol.*, 45:921-27.
- Ashrafi Tamai, I., Zahraei Salehi, T., Khosravi, A.R., Sharifzadeh, A., Balal, A. (2013). Chemical composition and anti-candida activity of Trachyspermum ammi essential oil on azoles resistant Candidaalbicans isolates from oral cavity of HIV+ patients. *J. Med. Plants*, 12: 137-149.
- Bairwa, R., Sodha, R.S., Rajawat, B.S. (2012). Trachyspermum ammi. *Pharmacogn Rev.*, 6:56-60.
- Boskabady, M.H. ,Jandaghi, P. ,Kiani, S., Hasanzadeh, L. (2005). Antitussive effect of Carum copticum in guinea pigs. *Journal of Ethnopharmacol.*, 97 :79-82.
- Carl, A., Edward, R., David, E., Tiet, z. (2008). *Fundamentals of Clinical Chemistry*. Publishing Diwcmr: Andrew Allen, 34: 632-636.
- Cavangh, K., and Lkizler, T. A. (2011). *Chronic Renal Failure*. Cecil Essential of Medicine, Arjman cd BOOK, Pp. 508-519.
- Changizi-Ashtiyani, S., Zohrabi, M., Hassanpoor,A., Hajihashemi, S., Hosseini, N. (2013). Studying the effects of aqueous extract of rosemary after treatment (Rosmarinus Officinalis) over 48 hours early after ischemia - reperfusion in rat kidney. *Journal of Research in Medical Sciences*, 15: 1-7.
- Chauhan, P.S., Satti, N.K., Suri, K.A., Amina, M., Bani, S. (2010). Stimulatory effects of Cuminum and flavonoid glycoside on cyclosporine-Aand restraint stress induced immune-suppression in swiss albino mice. *Chem Biol Interac.*, 185:66-72.
- Elsaid, F.G. and Elkomy, M.M. (2006). Aqueous garlic extract and sodium thiosulphate as antidotes for cyanide in toxication in albino rats. *Research Journal of medicine and medical Sciences*, 2: 50-56.
- Gilani, A.H., Jabeenq, Q., Ghayur, M.N., Janbaz, K.H., Akhtar, M.S. (2005). Studies on the antihypertensive, antispasmodic, bronchodilator and hepatoprotective activities of the carum copticum seed extract, *J Ethnopharmacol.*, 98:127-35.

- Guyton, A.C. and Hall, J.E. (2008). Text book of medical physiology, 11th Edition, Saunders, 4-R.H.Berne and M.N. Levy, Principles of Physiology, 6th Edition, Mosby Company.
- Hejazian, S.H., Fattahi Bafghi, A., Mahdavi, S.M. (2009). Investigating the analgesic effect of aqueous extract of *C. copticum* on chronic pain in comparison with its oil part. *Journal of Scientific-Research, Medicinal and Aromatic Plants Research*, 25: 104-112.
- Hosseinzadeh, H. and Mehrabi, M. (2003). Investigating the antiemetic effects of aqueous alcoholic extract of *C. copticum* on broiler chicks. *Quarterly Journal of Medicinal plants*. 9: 16-22.
- Ihsan Yman and Engin Balikci (2010). Protective effects of *Nigella sativa* against gentamicin – induced nephrotoxicity in rats. *Experimental and Toxicologic pathology*, 63: 183-190.
- Jafari, H. (2004). The effects of aqueous extract of *C. copticum* on the symptoms of withdrawal syndrome in male rats. *Quarterly Journal of Medicinal plants*, 3: 15-20.
- Jamali, H., Zamani, Z., Yazdani, M., Mokhtari, M., Johari, H., Hemayatkhah Jahromi, V. (2014). The Investigation of Garlic (*Allium Sativum*) Extract on Lead Detoxification of Neonatal Rats Kidney, *Journal of Fasa University of Medical Sciences*, 4: 90-98.
- Kanter, M., Coskun, O., Korkmaz, A., Oter, S. (2004). Effects of *Nigella sativa* on oxidative stress and beta-cell damage in streptozotocin-induced diabetic rats. *Discov Mol Cell Evol Biol.*, 279: 685-91.
- Karimi, G., Tabibi, N., Hosseinzadeh, H., Shirzad, F. (2004). Sub- acute toxicity of the aqueous extract of saffron stigmas and petals on rats. *The Journal of Medicinal Plants*, 12:32-9.
- Komeili, G. and Sargazi, M. (2012). The Therapeutic Effect of *Carum copticum* Seed Aqueous Extract on Peptic Ulcers Induced by Ibuprofen in Rat, *Zahedan Journal of Research in Medical Sciences*, 14:21-24.
- Rezvani, M.E., Roohbakhsh, A., Mosaddegh, M.H., Esmailidehraj, M., Khaloobagheri, F., Esmaeili, H. (2011). Anticonvulsant and depressant effects of aqueous extracts of *Carum copticum* seeds in male rats. *Epilepsy Behav.*, 22: 220- 25.
- Sharifi Mood, B., Shafaghat, M. (2014). The Inhibitory Effect of Ajowan Essential Oil on Bacterial Growth. *Int J Infect.*, 1: e19394.
- Shun, Y.M., Wen, Y.H., Yong, C.Y., Jian, G.S. (2003). Two benzyl dihydroflavones from *phellinus igniarius*. *Chinese Chemical Letters*, 14: 810-3.
- Takahashi, Y., Inaba, N., Kuwahara, S., Kuki, W. (2003). Effects of gamma-terpinene on lipid concentrations in serum using Triton WR1339 -treated rats. *Biosci Biotechnol Biochem*, 67: 2448-50.
- Varzi, H.N., Esmailzadeh, S., Morovvati, H., Avized, R., Shahriari, A, Givi, M.E. (2007). Effect of silymarin and vitamin E on gentamicin-induced nephrotoxicity in dogs. *Journal of Vet Pharmacol Ther.*, 30:477-81.
- Verma, R.J., Asnani, V. (2007). Ginger extract ameliorates parable induced biochemical changes in liver and kidney of mice. *Acta pol pharm.*, 64: 217-20.
- Walter, G. (1990). *Clinical Methods: The History, Physical, and Laboratory Examinations*. 3th Edition, chapter 156, Pp. 770-772.

Washington, I. M. and Hoosier, G.V. (2012). Clinical Biochemistry and Hematology. In Suckow MA, Stevens KA, Wilson RP (authors) The Laboratory Rabbit, Guinea Pig, Hamster, and Other Rodents. Academic Press, Pp. 57-116.

Zahin, M., Ahmad, I., Aqil, F. (2010). Antioxidant and antimutagenic activity of Carum copticum fruit extracts. Toxicol in Vitro, 24: 1243-1249.