



Clinical and Pathological Study of Bone Tumors of Dogs in Veterinary Clinics of Shiraz, South of Iran, from 2010 to 2021

Amir Ashkan Mahjoor*

Department of Pathobiology, Kazerun branch, Islamic Azad University, Kazerun, Iran

Received: 03/Jan/2021

Revised: 18/Mar/2021

Accepted: 09/Apr/2021

Abstract

Background and purpose: Bone tumors can be benign or malignant and primary or secondary in dogs. Osteosarcoma (OS) is considered the most common primary bone neoplasm in dogs, which has high metastasis ability.

Materials and methods: A retrospective histopathological study was performed over cases submitted to veterinary hospitals and clinics in Shiraz, the capital city of Fars province, south of Iran. Surgery and necropsy files of dogs submitted to clinics from 2010 and 2021 were retrospectively studied and cases suspected to bone tumors were separated.

Results: A total of 872 necropsy and surgical resection specimens from dogs referred to these clinics due to musculoskeletal defects were reviewed during this period, and among them, nine dogs (six male and three female dogs) corresponded to bone tumors.

Conclusion: All of the tumors were diagnosed as osteosarcoma. The epidemiological and pathological findings of these tumors are reported.

Keywords: Bone tumor, Osteosarcoma, Pathology, Dog

Cite this article as: Amir Ashkan Mahjoor. Clinical and pathological study of bone tumors of dogs in veterinary clinics of Shiraz, south of Iran, from 2010 to 2021. J Altern Vet Med. 2021; 4(8): 467-472.

* Corresponding Author

Department of Pathobiology, Kazerun branch, Islamic Azad University, Kazerun, Iran.

E-mail: amir.mahjoor@gmail.com, Orcid: <https://orcid.org/0000-0002-8351-4933>

Introduction

Unlike humans and some other species of domestic animals, malignant bone neoplasms are much more prevalent than benign neoplasms in dogs. Different types of bone neoplasms are seen in dogs, but Osteosarcoma is considered the most common primary bone neoplasm in these animals (Trosti *et al.*, 2012). Osteosarcoma accounts for approximately 5% of all canine neoplasms and more than 85% of all primary malignant bone tumors in dogs (Dernell 2003). Osteosarcoma is a malignant primary bone tumor arising from primitive transformed mesenchymal cells that differentiate into osteoblasts. In addition to producing an osteoid matrix, this tumor can also raise fibroblastic or cartilaginous matrix, therefore, it has been divided into six subtypes of poorly differentiated, osteoblastic, chondroblastic, fibroblastic, telangiectatic and giant cell forms (Esmaili Nejad *et al.*, 2019).

Osteosarcoma commonly occurs in the metaphysis of long bones, with micro metastases at the time of diagnosis. Biological behavior of Osteosarcoma is similar in dogs and humans, therefore, information on the incidence related to specific breeds of dogs might help to clarify the supposed correlation between birth weight, growth rate, adult body weight or height, and the development of Osteosarcoma (Anfinsen *et al.*, 2011). Additionally, diseased dogs have similar responses that makes them valuable contributors to the process of developing new anti-cancer therapy.

There are few reports of sporadic occurrence of bone neoplasms in dogs in Iran that all of them were diagnosed as osteosarcoma (Esmailinejad *et al.*, 2019, Bniadam *et al.*, 2010, Al Davood *et al.*, 2006). This study was designed to find the prevalence and types of bone tumors of dogs referred to veterinary clinics and hospitals in Shiraz.

Material and methods

The data of this study was collected from cases submitted to veterinary hospitals and clinics in Shiraz, the capital city of Fars province, south of Iran. Retrospective study was performed on dogs suspected to bone tumors noted in surgery and necropsy files of cases submitted to clinics from 2010 and 2021 by

clinical history, x-ray and/or pathological register. History relating to sex, breed, age, and location of the tumor on the body was obtained along the submission. The data of complete physical exam, blood test and radiography from the primary tumor site and lungs were also collected. All cases suspected to bone tumors were included in this study even if a parameter was not recorded.

Representative specimens of the bone lesions were obtained from the dogs by biopsy, necropsy or surgery. The materials were fixed in %10 formalin and decalcified in 5% nitric acid. Tissue sections (5 mm) were obtained, stained with hematoxylin and eosin (H & E), routinely processed for histology, and mounted on slides. The slides were studied by light microscopy.

Tumors were diagnosed and classified according to Klein *et al.*, 2006 and Pool 1990 into the following histological subtypes: Conventional (osteoblastic, fibroblastic, chondroblastic), Epithelioid, telangiectatic, giant cell type, and osteoblastoma-like/chondroblastoma-like osteosarcoma when more than one histological pattern was present. Histologic variables included osteoid matrix deposition, tumor cell pleomorphism, amount of tumor matrix, tumor cell density, tumor necrosis, estimated number of multinucleated giant cells, estimated whirl formation, mitotic index, tumor growth into vessels, and tumor grade and the type of matrix (osteoid, cartilage, or fibrous tissue) defining the histologic subtype (Trosti *et al.*, 2012).

All of the histologic samples were reviewed by a single reviewer to decrease interobserver variation, however, consultation was done with tumor field experts.

Results

Out of 872 dogs referred to these clinics due to musculoskeletal defects, nine dogs (six male and three female dogs) were diagnosed of having bone tumors. Among them, three dogs did not refer again for treatment by their owners, and four dogs went under surgery. In addition, two dogs were euthanized after the failure of treatment procedure.

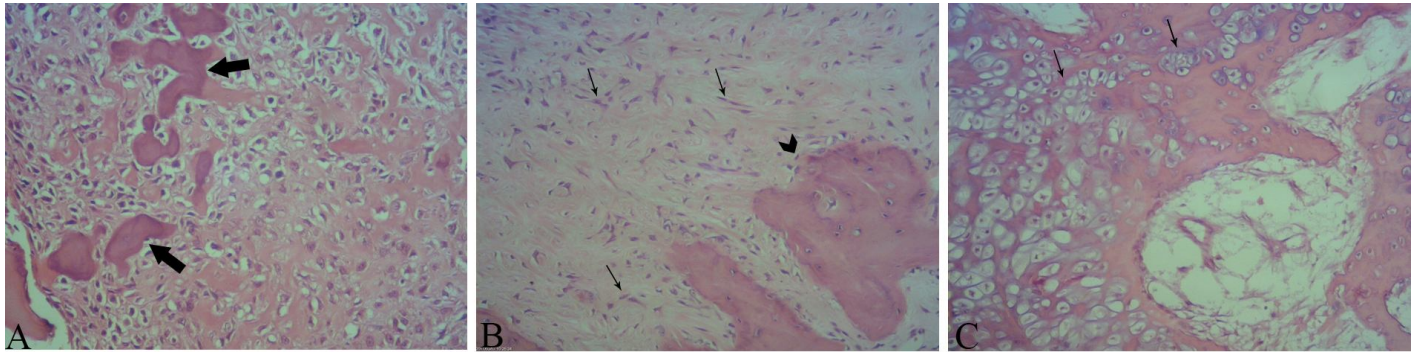


Figure 1. **A-** Osteoblastic osteosarcoma. Abundant production of extracellular bone matrix: immature bone and/or osteoid in a lacy pattern. Note marked nuclear pleomorphism and the low mitotic index (arrows). **B-** Fibroblastic osteosarcoma. Spindle cells resembling atypical fibroblasts (arrows), with bone matrix formation (arrow head). **C-** Chondroblastic osteosarcoma: Note chondroblast in lacunar spaces encompassed by the chondroid matrix (arrows). Some osteoid formation is seen, too. (H&E, $\times 100$).

Five dogs were over 7 years old. Three dogs were 5-6 years old and one dog was 2 years old. All of the tumors were located in appendicular skeleton. Among them, five dogs had tumors located in forelimb (4 Proximal humerus and 1 in Distal radius) and four in hind limbs (2 in Distal femur and 2 in Distal tibia).

Aggressive appearance, irritability, weight loss, aggression, loss of appetite, sleeplessness, different degrees of lameness and firm, painful swelling were the common clinical signs. Pathological fracture was not seen in these dogs.

Radiograph was not available in three dogs but in other dogs, radiography revealed cortical bone lysis and sclerotic lesion accompanied with trabeculation extending to bone cortex and the articular surface. Amorphous new bone formations were formed around the bone. Soft tissue invasion of the tumor was noted in all dogs. Lung metastasis was noted in 4 out of 6 dogs.

In Microscopic evaluation, all the tumors were diagnosed as osteosarcoma. Six of them were classified as osteoblastic osteosarcoma, two as fibroblastic osteosarcoma and one as chondroblastic osteosarcoma.

Based on gross radiographic and histopathological evaluation, the tumor in three of the dogs were classified periosteal osteosarcoma, two as conventional (high grade) osteosarcoma and one as high grade surface osteosarcoma. Due to lack of radiograph and proper gross discription, we were unable to classify three of the tumors.

Abundant osteoid production as anastomosing network of delicate trabeculae was the main feature in osteoblastic osteosarcoma cases. The neoplastic cells

were highly atypic and pleomorphic. The prominent tumor cells resembled osteoblasts with densely eosinophilic cytoplasm and atypic nuclei. Fibroblast-like spindle cells, small round cells, epithelioid cells and giant tumor cells were other present cells. Periosteal invasion was noted in all of the osteoblastic osteo sarcoma cases (Figure 1A).

The main histopathological features in fibroblastic osteosarcoma (Figure 1B) cases were spindled and epithelioid cells with high degree of atypia with the presence of extracellular bundles of collagen fibers. Most parts of the lesion were composed of proliferating fibroblasts with infrequent mitosis. Invasion into the adjacent soft tissue was also noted.

In chondroblastic osteosarcoma (Figure 1C) case, the tumor cells were present in lacunar space in a lobular pattern. The periphery of the lobules was hypercellular and cartilaginous matrix production with scattered immature bone formation was also noted. Hemorrhagic centers with bundles of collagen fibers were seen in some parts of the affected bone in 4 cases.

Discussion

Seventy five percent of osteosarcomas occur in long bones. Bone infarct, presence of an internal fixation devise, osteomyelitis and repeated microtrauma to metaphysis of long bones produced by weight-bearing stresses may also play a role in the development of osteosarcoma ((Baniadam *et al.*, 2010). Osteosarcomas are highly malignant. They cause lysis or new bone formation, or both, but rarely spread over joints. Giant and large breed dogs are at

increased risk of developing OS (Dernell *et al.*, 2007). Nine out of 872 dogs in our study were suspected of osteosarcoma. Through a questionnaire study, Anfinsen *et al.* (2011) reported that from 1385 dogs whose owners had responded, 29 dogs, 2.1% (1.4% to 3.0%), had suffered from primary bone tumors, Dobson *et al.*, (2002) in a study based on insurance data reported an incidence rate of 5.7 cases per 10000. All the dogs, with an exception of one in our study were over five years old. The mean age of osteosarcoma is between 7.5 to 8 years (Baniadam *et al.*, 2010). A smaller peak in age incidence at 18 to 24 months corresponds with the human peak incidence at late puberty, which has led to the hypothesis of skeletal growth parameters representing some of the possible etiological factors for developing this disease (Anfinsen *et al.*, 2011).

Six out of nine dogs in our study were male. Although Kruse *et al.*, (2012) and Brodey & Riser (1969) have reported a higher incidence of osteosarcoma in female dogs of certain dog breeds, such as Saint Bernard, most researches have shown a higher prevalence of osteosarcoma in male dogs (Trosti *et al.*, 2012; Morello *et al.*, 2010). All the female dogs in our study were spayed and four out of six male dogs in our study were castrated. Some studies have shown an increased risk of primary bone tumors in neutered dogs, especially when this procedure is performed at an early age (Cooley *et al.*, 2002). The age that the dogs were castrated in our study was not clear. Jeusette *et al.*, (2006) suggests that neutering can lead to excessive body weight gain, in part because of hormonal alterations that affect both basal metabolism and appetite regulation. The tumor site in all of our cases were in fore and hind limbs. The usual site of osteosarcoma is in the appendicular skeleton, of which the distal radius and proximal humerus of the forelimbs are the most common. In the hindlimbs, the distal tibia and fibula and the proximal tibia are frequently involved (Egenvall *et al.*, 2007 Dernell 2003), In three dogs diagnosed with primary bone tumors in this study, histological diagnosis was not performed, and the diagnosis was based upon clinical signs and radiography. Anfinsen *et al.* (2011) assumes that only %75 of cases diagnosed by clinical and radiological findings are confirmed by histopathology.

In the present study, the obtained weight data of the dogs noted in their files were not reliable

preventing a comparative analysis. Both lytic and productive type of osteosarcoma was seen in our study. Thompson (2007) noted that the radiographic and macroscopic appearance of the osteosarcoma could be lytic, productive or mixed depending on the behavior of neoplastic cells and the type of matrix produced by them (Thompson 2007). Parachini-winter (2019) has reported a 95% of subcutaneous metastasis of osteosarcoma and noted that the skin or subcutaneous tissue can be the first osteosarcoma metastatic site detected. Necropsy was not performed on three dogs in our study. Thus, it is possible that some metastasis of the tumor has been missed. Subcutaneous metastasis are most commonly firm, solitary masses, and are rarely associated with pain, inflammation, or ulceration that could be the main reason that this kind of metastasis was not noticed by clinicians involved in our study.

The classification of osteosarcoma in veterinary medicine is determined by the predominant morphologic features of the neoplastic cells and includes osteoblastic, chondroblastic, fibroblastic, telangiectatic, giant cell-rich, and poorly differentiated osteosarcoma (Jenkins *et al.*, 2018). The histopathological features of our study were similar to those reported by other researchers Trosti *et al.*, 2012, Morello *et al.*, 2010, Klein *et al.*, 2006, Pool 1990. High degree of necrosis and anaplasia was not seen in the present study. In the cases with hemorrhage, the hemorrhagic foci's did not cover fifty percent of the slides with hemorrhage, so the tumor was not classified as telangiectatic osteosarcoma. The histopathological features of fibroblastic osteosarcoma in our case are similar to what has been described by Jenkins *et al.*, 2018.

These researchers noted that the presence of osteoid are key features that favor a diagnosis of osteosarcoma over a metastatic carcinoma, that was either found in our case. There were some limitations in our study that the main one was the lack of proper number of histopathological slides, clinical data and thorough body examination for tumor metastasis.

Acknowledgment

The author thanks Dr Chaharbaradari and Dr Saboki from Arya vet hospital and Dr Negahdari and

Dr Fahimi from Iran veterinary hospital for providing case material.

References

- Al davood Sj., Veshkini A. and Kariminejad MH. Osteosarcoma in frontal bone in a dog. 31 st world small animal veterinary congress. Prague, Check republic, 2006.
- Anfinsen KP., Grotmol T., Bruland OS. and Jonasdottir TJ. Breed-specific incidence rates of canine primary bone tumors - A population based survey of dogs in Norway. *Can J Vet Res*, 2011; 75(3): 209-215.
- Baniadam A., Ahmadian F., Mohamadian B., Mosalanejad B. and Ghadiri AR. Surgical treatment of osteosarcoma in the ribs of a dog. A case report. *Iran J Vet Med*, 2010; 4(1): 29-32.
- Brodey RS. and Riser WH. Canine osteosarcoma. A clinicopathologic study of 194 cases *Clinical Orthopaedics and Related Research*, 1969; 62: 54-64.
- Cooley DM., Beranek BC., Schlittler DL., Glickman NW., Glickman LT. and Waters DJ. Endogenous gonadal hormone exposure and bone sarcoma risk. *Cancer Epidemio Biomark Prev*, 2002; 11:1434-1440.
- Egenvall A., Nodtvedt A. and Von Euler H. Bone tumors in a population of 400 000 insured Swedish dogs up to 10 y of age: Incidence and survival. *Can J Vet Res*, 2007; 71(4): 292-299.
- Esmaili Nejad MR., Rana Vafaei R., Masoudifard M., Nassir SM. and Salim A. Aggressive chondroblastic osteosarcoma in a dog: A case report. *Vet Res forum*, 2019; 10(4): 361-364.
- Dernell WS., Ehrhart NP., Straw RC. and Vail DM. Tumors of the skeletal system. In: Withrow S, Vail DM, editors. *Withrow & MacEwen's Small Animal Clinical Oncology*. 4 ed. St Louis, Missouri: Saunders Elsevier; 2007. PP. 540-582.
- Dernell WS. Tumours of the skeletal system. In: *BSAVA Manual of Canine and Feline Oncology*. 2. Quedgeley, England: British Small Animal Veterinary Association, 2003; PP. 179-195.
- Dobson JM., Samuel S., Milstein H., Rogers K. and Wood JLN. Canine neoplasia in the UK: estimates of incidence rates from a population of insured dogs. *J Small Anim Pract*, 2002; 43: 240-246.
- Jeusette I., Daminet S. and Nguyen P. Effect of ovariectomy and ad libitum feeding on body composition, thyroid status, ghrelin and leptin plasma concentrations in female dogs. *J anim physiol Anim Nutr*, 2006; 90:12-18.
- Kruse MA., Holmes ES., Balko JA., Fernandez S. and Brown DC. Evaluation of clinical and histopathologic prognostic factors for survival in canine osteosarcoma of the extracranial flat and irregular bones. *Vet Pathol*, 2012; 50(4): 704-70.
- Klein MJ. and Siegal GP. Osteosarcoma anatomic and histologic variants. *Am J Clin Pathol*, 2006; 125(4): 555-581.
- Morello E., Martano M. and Buracco P. Biology, diagnosis and treatment of canine appendicular osteosarcoma: Similarities and differences with human osteosarcoma. *Vet J*, 2010; 189: 268-277.
- Parachini-Winter C., M Curran K., Pellin M., Laver T., Hanot C, Vernier TH. and Séguin B. Cutaneous and subcutaneous metastasis of appendicular osteosarcoma in dogs: 20 cases. *J Vet Intern med*, 2019; 33(5): 2200-2208.
- Pool RR. Tumors of bone and cartilage. In: MOULTON, J. E. *Tumors in domestic animals*. 3rd ed. Berkeley: University California Press, 1990.
- Trost ME., Kommers GD., Brown CC; Barros CSL., Irigoyen LF., Figheral RA., et al. Primary bone neoplasms in dogs: 90 cases. *Pesqui Vet Bras*, 2012; 32(12): 272-284.
- Jenkins TL., Agnew D. and Rissi DR. Fibroblastic osteosarcoma with epithelioid and squamous differentiation in a dog. *J Vet Diagn Invest*, 2018; 30(4): 593-597.
- Thompson K. Bones and Joints. In: Maxxie M.G. (Ed.), *Jubb, Kennedy and Palmer's Pathology of Domestic Animals*. 5th ed. Mosby Elsevier, St Louis, 2007; p.1-184.



بررسی بالینی و پاتولوژیک تومورهای استخوانی سگ ها در کلینیک های

دامپزشکی شیراز، جنوب ایران، از سال ۱۳۸۹ تا ۱۴۰۰

امیراشکان مهجور*

گروه پاتوبیولوژی، واحد کازرون، دانشگاه آزاد اسلامی، کازرون، ایران

تاریخ دریافت: ۱۳۹۹/۱۰/۱۴ اصلاح نهایی: ۱۳۹۹/۱۲/۲۸ تاریخ پذیرش: ۱۴۰۰/۰۱/۲۰

چکیده

زمینه و هدف: تومورهای استخوانی به صورت خوش خیم و بد خیم و اولیه و ثانویه در سگ دیده می شود. استئوسارکوم مهمترین تومور اولیه استخوانی در سگ است که دارای قدرت متاستاز بالایی می باشد.

مواد و روشها: این مطالعه گذشته نگر بر روی سگ های مشکوک به تومور استخوانی که به کلینیک های دامپزشکی شیراز مراجعه کرده بودند انجام شد. پرونده های مربوط به جراحی و کالبدگشایی این سگ ها جدا شده و مطالعه شد

یافته ها: با مطالعه پرونده هشتصد و هفتاد و دو سگ مراجعه شده به علت مشکلات اسکلتی به این کلینیک ها، ۹ مورد مشکوک (شش نر و سه ماده) مبتلا به تومور استخوانی تشخیص داده شد.

نتیجه گیری: با مطالعه این تومورها، تمام موارد استئوسارکوم تشخیص داده شد و یافته های میکروسکوپی این تومورها شرح داده شد.

واژه های کلیدی: تومور استخوان، استئوسارکوم، آسیب شناسی، سگ

امیراشکان مهجور. بررسی بالینی و پاتولوژیک تومورهای استخوانی سگ ها در کلینیک های دامپزشکی شیراز، جنوب ایران، از سال ۱۳۸۹ تا ۱۴۰۰. مجله طب دامپزشکی جایگزین. ۱۴۰۰؛ ۴(۸): ۴۶۷-۴۷۲.

* نویسنده مسئول: گروه پاتوبیولوژی، واحد کازرون، دانشگاه آزاد اسلامی، کازرون، ایران.