



# Radiological Evaluation of Vertebral Column Injuries in Dogs Referred to Tehran Hospitals and Veterinary Clinics

Reza Behmanesh\*

Assistant Professor, Faculty of Veterinary, Garmsar Branch, Islamic Azad University, Garmsar, Iran

Received: 24/Sep/2021

Revised: 27/Oct/2021

Accepted: 11/Nov/2021

## Abstract

**Background and aim:** Vertebral column injuries are very common and vary in severity and prognosis. The aim of this study was to examine the spine for abnormal curvature of the spine, such as scoliosis and kyphosis and osteoarthritis of the intervertebral joints and the collapse (degeneration) of the discs between the bones of the spine and other abnormality in dogs.

**Materials and Methods:** In this study osteoarthritis of the intervertebral joints and the collapse (degeneration) of the discs between the bones of the spine and spinal injuries, examined on radiographs of the vertebrae. In this study we evaluated relationship between these injuries and age, sex and the breed of dogs referred to clinics and hospitals in Tehran during a period of 2 years (2020-2021).

**Results:** The incidence of spinal disorders in different age groups during the study period were 17.89% in the age group 0 to 5 years, 49.75% for age group 6 to 10 years and 32.36% for age group 11 to 15 years. The incidence of spinal disorders in different sexes during the study period was 39.80% in males and 60.20% in females.

**Conclusion:** This study revealed that the probability of suffering from primary vertebral injuries increased with a dog's age and the percentage of vertebral problems in females is higher than males.

**Keywords:** Radiography, Vertebral column, Spinal cord Injuries, Dog

**Cite this article as:** Reza Behmanesh. Radiological evaluation of vertebral column injuries in dogs referred to Tehran hospitals and veterinary clinics. J Altern Vet Med. 2021; 4(10): 601-608.

## \* Corresponding Author

Assistant Professor, Faculty of Veterinary, Garmsar Branch, Islamic Azad University, Garmsar, Iran.

E-mail: [dr.rezabehmanesh@yahoo.com](mailto:dr.rezabehmanesh@yahoo.com), Orcid: <https://orcid.org/0000-0003-0521-1424>

## Introduction

Vertebral column injury (trauma) is a frequent and common injury, which has different kinds regarding the severity and prognosis. Its symptoms can vary from temporary neurological dysfunction, focal defect, and fatal event to the condition of the symptoms (Schlensker & Dislt, 2013). One of the most important and practical diagnostic tools in spine injury is radiography, which plays an essential role in the diagnosis of spine diseases in dogs (Ricciardi, 2016). In the preparation of diagnostic films, the exact position of the patient and attention to the technique are very important, and if the animal has pain or muscle spasm, it is usually necessary to inject a sedative or general anesthesia. If additional information is needed, myelography technique is used. In this method, a contrast material containing iodine dissolved in water is injected into the subarachnoid space through the cisterna magna, and this injection is performed under general anesthesia. Although imaging techniques such as MRI, CT scan, radioisotope scan and other methods can be used to investigate spinal problems, however, usually before any procedure, the veterinarian first prefers to administrate and observe a simple radiograph (Stieger-Vanegas *et al.*, 2015). Each vertebra is a complex and three-dimensional structure, but only two dimensions of this complex, three-dimensional structure is displayed in radiographic technique (x-ray beam energy). The stability, position of the patient as well as radiographic technique are all important in diagnosing spine problems, because subtle abnormalities may not be recognized or normal structures may be recognized as abnormal structures. It is important to collect images in two planes (orthogonal), laterally (lying on the side) and dorsoventral (lying on the back), but if there is a possibility of spinal instability or trauma, oblique images between these two orthogonal planes may also be applied (Kramer *et al.*, 1982). The aim of this study was to examine the spine for abnormal curvature, such as scoliosis and kyphosis and osteoarthritis (Moissonier *et al.*, 2011) of the intervertebral joints and the collapse (degeneration) of the discs between the bones of the spine and other abnormality in dogs.

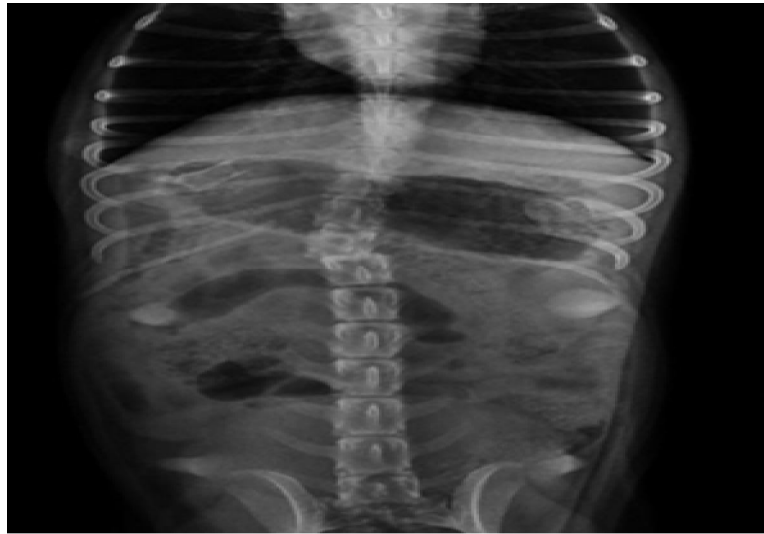## Materials and Methods

In this study, dogs referred to veterinary hospitals and clinics in Tehran between 2020 and 2021 were examined. The criteria for entering the dogs into the study were the presence of at least one vertebral abnormality with the diagnostic method of digital radiography and with diagnostic quality of the lateral and ventral-dorsal spine. Also, radiography of the thoracic spine was performed using the same digital radiography system (VIEWORK, Flat Panel Detector for Veterinary, South Korea). Radiographs were reviewed and interpreted by two observers.

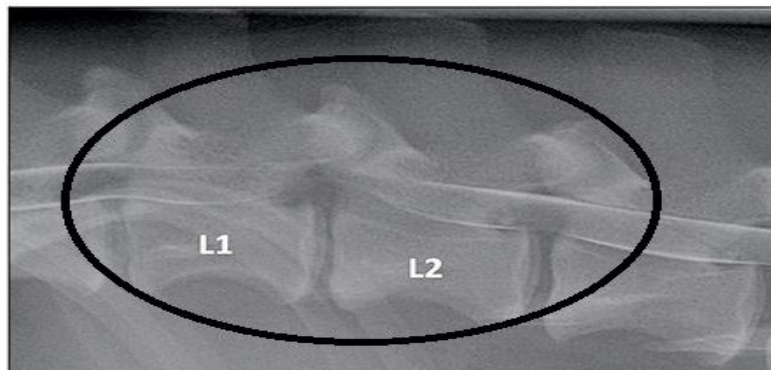
In this study, the radiological features of all types of spine diseases in dogs, infectious conditions, congenital and developmental abnormalities, nutritional, degenerative, trauma and neoplasia were investigated (Henry & Cole, 2018). For radiography of small breed dogs, kvp and mas were set to 50 to 60 KV and 4.5 to 5 mAs, and for large breed dogs, 80 to 90 KV and 7 to 8 mAs. In the present study, osteoarthritis of the intervertebral joints and the collapse (degeneration) of the discs between the bones of the spine and spinal injuries, such as fractures or dislocations (Figure 1) were evaluated and the effects of some problems such as infections, tumors, or bone bridges, as well as all the complications, were examined on radiographs of the vertebrae (Figure 2). Also, in this study we evaluated the relationship between these injuries and age, sex and the breed of 100 dogs referred to clinics and hospitals in Tehran during years 2020 to 2021. The radiographs for each dog were retrieved and evaluated by two observers who were unaware of dog group status at the time of interpretation. Images were displayed using an open-source PACS Workstation DICOM viewer Imaging Software. Each vertebral malformation classification was determined by a consensus between the two observers.

## Statistical Data Analysis

The collected data were analyzed descriptively and analytically using SPSS software version 16. In order to analyze the data, Kolmogorov-Smirnov test, Chi square test and Mann-Whitney test were used.



**Figure 1.** Plain Ventrodorsal radiographic view showing T-L fracture luxation in dog.



**Figure 2.** Lateral myelogram of a 5-year-old dog with an L1-L2 IVDE.

## Results

The percentage of spinal disorders of thoracic and lumbar vertebrae in different breeds among 100 dogs referred to radiology was, Boxer 9.30%, Doberman 13.46%, German Shepard 23.94%, Great Dane 2.08%, Labrador Retriever 10.47%, Sarabi 2.08%, Pameranin 18.75%, Spitz 14.58% and Pag 5.34% (Table1). The incidence of spinal disorders in different age groups during the study period was 17.89% in the age group 0 to 5 years, 49.75% for 6 to 10 years, and 32.36% was observed for 11 to 15 years old with spinal disorders (Table 2 and Graph 1).

The incidence of spinal disorders in different sexes during the study period was 39.80% in males and 60.20% in females (Table 3 and Graph 2). The incidence of various types of spinal disorders in this study was observed as follows: 37.92% intervertebral disc, 18.92% vertebral fracture, 15.55% vertebral dislocation, 14.66% spondylitis and vertebral infection, and 6.64% vertebral malformations (kyphosis, lordosis and scoliosis), 1.67% of spinal canal lesions such as Wempler syndrome and Spina bifida and another 4.65% of spinal cord lesions such as spondylosis and discospondylitis (Table 4).

Breed	Boxer	Doberman	German Shepard	Great Dane	Labrador Retriever	Sarabi	Pameranin	Pag	Spitz
Percentage of spinal disorders	9.30%	13.46%	23.94%	2.08%	10.47%	2.08%	18.75%	5.34%	14.58%

**Table 1.** The percentage of spinal disorders of thoracic and lumbar vertebrae in different breeds among 100 dogs referred to the radiology department.

Incidence of spinal disorders	0 to 5 years	6 to 10 years	11 to 15 years
Percentage	17.89%	49.75%	32.36%

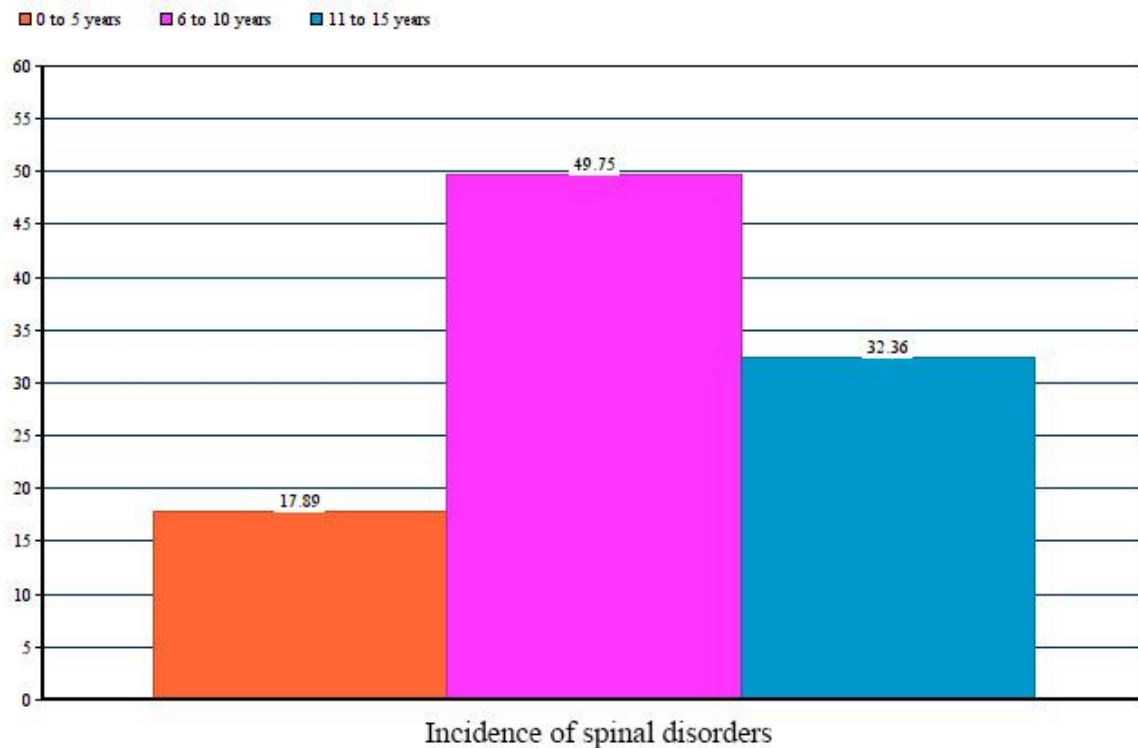
**Table 2.** The incidence of spinal disorders in different age groups.

Sex	Male	Female
Percentage	39.80%	60.20%

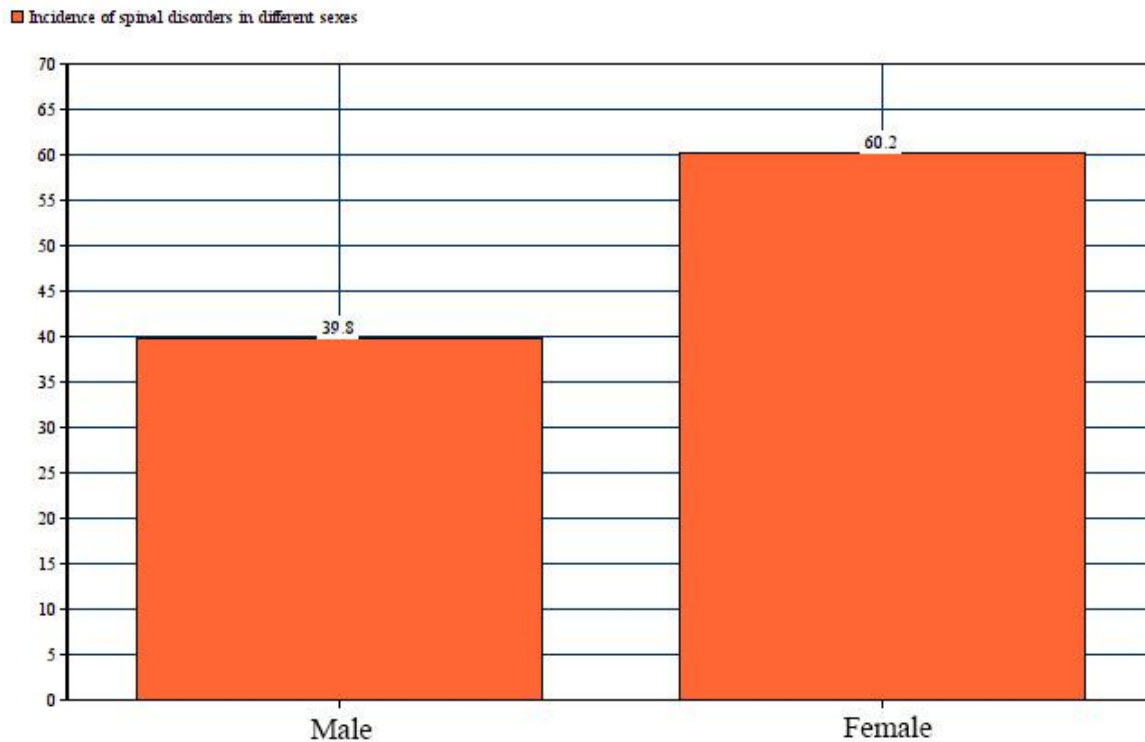
**Table 3.** The incidence of spinal disorders in different sexes.

Types of spinal disorders	Intervertebral disc	Vertebral fracture	Vertebral dislocation	Spondylitis and vertebral infection	Vertebral malformations	Spinal canal lesions	Spinal cord lesions
Percentage	37.92%	18.92%	15.55%	14.66%	6.64%	1.67%	4.65%

**Table 4.** The incidence of various types of spinal disorders.



**Graph 1.** The incidence of spinal disorders in different age groups.



**Graph 2.** The incidence of spinal disorders in different sexes.

### Discussion

One of the most important causes of pain and nerve dysfunction in dogs is broken vertebral fractures and luxations. Depending on the extent and severity of damage to the spinal cord and nerve roots, the prognosis varies and may include a range from severing spinal cord to minimal damage. In these cases, the diagnostic and treatment approach should include awareness of the possibility of multiple injuries and the risk of further injuries during diagnostic procedures or during surgical interventions. Radiographs are usually inexpensive, readily available, and performed quickly (Volta *et al.*, 2016). When a disease or abnormality is related to the vertebrae itself or leads to displacement of the vertebrae, radiography of the vertebral column is very valuable. Some examples of spinal disease include vertebral fractures or dislocations, vertebral abnormalities, tumors that cause bone destruction or proliferation, or bone infection that causes bone loss (McMaster & Singh, 1999). Mild changes in the bone or the width of the intervertebral disc space, such as extrusion or protrusion of the intervertebral disc, can be caused by some diseases (Westworth & Sturges, 2010). Care should be taken not to over interpret

survey spinal radiographs in intervertebral disc disease. The utility of radiographs should not be underestimated, especially where there is concern for column instability such as fracture or luxation (Volta *et al.*, 2016).

Acute injuries to the spinal cord are usually characterized by a fracture or luxation of the spine. Common causes of spinal cord injuries in dogs and cats are bite wounds, car accidents, and gunshot wounds (Kinns *et al.*, 2006). Early radiographic findings for Vertebral Column Injuries consist of destruction of the adjacent vertebral end plates and the collapse of disk space and more abnormalities. More advanced lesions also have variable extents of osteophyte formation. Acute spinal trauma can lead to unstable spinal injuries which can potentially result in temporary or permanent paralysis. Positioning patients without sedation can lead to images that are not of optimal diagnostic value (Moissonier *et al.*, 2011).

In a study conducted by Gutierrez-Quintana *et al.*, between 2009 and 2013 on congenital abnormalities of the thoracic vertebrae in brachiocephalic dog breeds, it was shown that out of 28 dogs (12 dogs with neurological defects, 16 dogs without

neurological defects) who had the inclusion criteria abnormalities that affected the thoracic vertebrae. The findings of this study were consistent with previous studies that showed that congenital vertebral anomalies in the thoracic spine of brachycephalic "twist tail" dog breeds were common and 23.5% of the examined vertebrae were affected in that study. Most of the dogs (64.2%) in this study had multiple vertebral abnormalities. This finding was also similar to previous reports describing the frequency of vertebral anomalies in French bulldogs, English bulldogs, and other brachycephalic breeds with multiple vertebrae commonly affected. Also, similar to previous studies, they observed that the most commonly injured vertebra was in the mid-thoracic region (T6-T9 region) (Gutierrez-Quintana *et al.*, 2014). In our study, small breeds of dogs had many vertebral abnormalities, like the aforementioned research.

In another study conducted by Soroori *et al.*, during a 5-year period (2004-2008), 232 dogs were examined for osteoarthritis, radiographically. In this study, osteoarthritis was found in 21.12% of dogs. Also, osteoarthritis in the vertebral column was found in 6.46% of dogs. This study showed that the radiographic changes of osteoarthritis are more detectable in large breed dogs (34.56%) than in small breeds (13.63%). This study showed that the probability of early arthritis increases with the age of the dog. According to the findings of this study, age and high weight played an important role in increasing the risk of vertebral injuries. Increased age and weight have a significant effect on the occurrence of spinal cord injuries in dogs (Soroori *et al.*, 2012). The percentage of vertebral problems in females is higher in males, which was observed in this study, but more studies in a larger group of dogs are needed to confirm this issue.

One of the limitations to be mentioned in this study is the impossibility of selecting the sex and breed of dogs referred to the radiology center before starting the study. There were several limitations to this study, including being retrospective in nature. Second, the breed distribution between the groups was not similar and this could have influenced the type of vertebral malformations seen in each group. Third, the number of cases in the present study was small, thus it was not possible to give an accurate representation of the frequency of the different

this study, 23.5% of them had congenital vertebral vertebral malformations in in each breed. Another limitation was the absence of long-term follow up of the cases and it is unknown if some of the dogs in groups may have developed vertebral abnormalities at a later date. None of them had any additional imaging to confirm that there was no spinal cord compression at the site of their vertebral body anomalies.

#### Acknowledgements

The author would like to thank the President and Vice Chancellor of the Faculty of Veterinary Sciences, Islamic Azad University of Garmsar, and the Department of Radiology for their cooperation.

#### References

- Gutierrez-Quintana R., Guevar J., Stalín C., Faller K., Yeaman C. and Penderis J. A proposed radiographic classification scheme for congenital thoracic vertebral malformations in brachycephalic "screw-tailed" dog breeds. *Vet Radiol Ultrasound*. 2014; 55(6): 585-91. doi: 10.1111/vru.12172.
- Henry GA. and Cole R. Fracture healing and complications in dogs. In: Thrall DE, editor. *Textbook of Veterinary, Diagnostic Radiology*. 7th ed. Saint Louis: Elsevier, 2018; PP: 366-389.
- Kinns J., Mai W., Seiler G., Zwingenberger A., Johnson V., Caceres A., *et al.* Radiographic sensitivity and negative predictive value for acute canine spinal trauma. *Vet Radiol Ultrasound*, 2006; 47(6): 563-570
- Kramer JW., Schiffer SP., Rantanen NW. and Whitener EK. Characterization of heritable thoracic hemivertebra of the German shorthaired pointer. *J Am Vet Med Assoc*, 1982; 181:814-815.
- McMaster MJ. and Singh H. Natural history of congenital kyphosis and kyphoscoliosis. *J Bone Joint Surg*, 1999; 81(A): 1367-1383.
- Moissonier P., Gossot P. and Scotti S. Thoracic kyphosis associated with hemivertebra. *Vet Surg*, 2011; 40:1029-1032.
- Ricciardi M. Usefulness of multidetector computed tomography in the evaluation of spinal



- neuromusculoskeletal injuries. *Vet Comp Orthop Traumatol*, 2016; 29(1): 1-13.
- Schlensker E. and Dislt O. Prevalence, grading and genetics of hemivertebrae in dogs. *Eur J Comp Anim Pract*, 2013; 23: 119-123.
- Soroori S., Bahonar A., Masoudifard M., Rostami A. and Taherpour F. Radiographical study of osteoarthritis in dogs. *J Vet Res*, 2012; 67(1): 77-81. doi: 10.22059/jvr.2012.24264.
- Stieger-Vanegas SM., Senthirajah SK., Nemanic S., Baltzer W., Warnock J. and Bobe G. Evaluation of the diagnostic accuracy of four-view radiography and conventional computed tomography analysing sacral and pelvic fractures in dogs. *Vet Comp Orthop Traumatol*, 2015; 28(3): 155-163.
- Volta A., Morgan JP., Gnudi G., Bonazzi M., Gazzola M., Zanichelli S., et al. Clinical-radiological study of the vertebral abnormalities in the English bulldog. Proceeding of the 12th annual conference of the European Association of Veterinary Diagnostic Imaging, 2005 Oct 5-8; Naples, Italy, P: 31.
- Westworth DR. and Sturges BK. Congenital spinal malformations in small animals. *Vet Clin North Am Small Anim Pract*, 2010; 40:951-981.



## بررسی رادیولوژیکی آسیب های ستون مهره ها در سگ های ارجاع داده شده به بیمارستان ها و کلینیک های دامپزشکی تهران

رضا بهمنش\*

استادیار، دانشکده دامپزشکی، واحد گرمسار، دانشگاه آزاد اسلامی، گرمسار، ایران

تاریخ دریافت: ۱۴۰۰/۰۷/۰۲ اصلاح نهایی: ۱۴۰۰/۰۸/۰۵ تاریخ پذیرش: ۱۴۰۰/۰۸/۲۰

### چکیده

**زمینه و هدف:** آسیب های نخاعی بسیار شایع هستند و شدت و پیش آگهی آنها متفاوت است. هدف از این مطالعه بررسی ستون فقرات از نظر انحنا غیرطبیعی ستون فقرات مانند اسکولیوز و کایفوز و استئوآرتریت مفاصل بین مهره‌ای و تخریب (دژنراسیون) دیسک‌های بین مهره‌ای و سایر ناهنجاری‌ها در سگ‌ها بود.

**مواد و روش‌ها:** در این مطالعه آرتروز مفاصل بین مهره‌ای و تخریب (دژنراسیون) دیسک‌های بین استخوان‌های ستون فقرات و آسیب‌های ستون فقرات، در رادیوگرافی مهره‌ها بررسی شد. در این مطالعه ارتباط بین این آسیب‌ها با سن، جنس و نژاد سگ‌های مراجعه کننده به کلینیک‌ها و بیمارستان‌های شهر تهران در مدت ۲ سال (۱۳۹۹-۱۴۰۰) بررسی شد.

**یافته‌ها:** بروز اختلالات ستون فقرات در گروه های سنی مختلف در طول دوره مطالعه ۱۷/۸۹ درصد در گروه سنی ۰ تا ۵ سال، ۴۹/۷۵ درصد برای گروه سنی ۶ تا ۱۰ و ۳۲/۳۶ درصد برای گروه سنی ۱۱ تا ۱۵ سال بود. میزان بروز اختلالات ستون فقرات در جنس های مختلف در طول دوره مطالعه در نرها ۳۹/۸۰ درصد و در ماده ها ۶۰/۲۰ درصد بود.

**نتیجه گیری:** این مطالعه نشان داد که با افزایش سن سگ، احتمال آسیب‌های مهره‌ای اولیه افزایش می‌یابد و درصد مشکلات مهره‌ای در ماده‌ها بیشتر از نرها می‌باشد.

**واژه‌های کلیدی:** رادیولوژی، ستون فقرات، آسیب های نخاعی، سگ

رضا بهمنش. بررسی رادیولوژیکی آسیب های ستون مهره ها در سگ های ارجاع داده شده به بیمارستان ها و کلینیک های دامپزشکی تهران. ۱۴۰۰؛ ۴(۱۰): ۶۰۱-۶۰۸.

\* نویسنده مسئول: استادیار، دانشکده دامپزشکی، واحد گرمسار، دانشگاه آزاد اسلامی، گرمسار، ایران.