



Evaluation of the Effect of Topical Ointment of 10% Hydroalcoholic Extract of Pistachio Peel on Wound Healing in Rat: A Histological Study

Alireza Yousofi^{1*}, Negin Jafari¹, Sara Varzandian¹, Elham Faghieh Shirazi²

¹Department of Clinical Sciences, Veterinary Faculty, Kazerun Branch, Islamic Azad University, Kazerun, Iran

²Department of Physiology, Shiraz University of Medical Sciences, Shiraz, Iran

Received: 08/Oct/2022

Revised: 11/Nov/2022

Accepted: 22/Nov/2022

Abstract

Background and aim: The loss of the integrity of the skin can cause damage and diseases for a person, which leads to physical disabilities and even death; therefore, one of the most important issues that medical science has faced so far is the issue of treating wounds. This study was conducted to compare the histopathological evaluation of skin wound healing in male Wistar rats with a topical ointment of 10% hydroalcoholic extract of pistachio peel.

Materials and Methods: Twenty male rats were randomly allocated to two experimental groups (n=10). A skin wound with a diameter of 2 cm was created in a circular shape on the back of all animals. Group 1 was considered as control. Group 2 received Hydroalcoholic ointment prepared from the pure extract of pistachio peel. 24 hours after wound formation, treatment with 10% ointment of purified pistachio peel extract began and continued until 21 days and the healing process was evaluated on days 4, 7, 14, and 21. Animals were anesthetized, and the skin of specimens was taken. In addition, the amount of wound contraction was obtained using the calculated surface of the wound and was subjected to statistical analysis using SPSS and T-test.

Results: According to the result, hydroalcoholic extract of pistachio peel ointment is effective and accelerates the healing of the wound. We found that the average wound size and the number of inflammatory cells were decreased in treatment groups but the number of fibrocytes, fibroblast cells, formation and order of collagen fibers had increased in the treatment groups.

Conclusion: This study suggests that topical treatment with hydroalcoholic extract of pistachio peel can be used as clinical therapy and can enhance tissue healing.

Keywords: *Pistachio peel extract, Wound healing, Histological study, Inflammatory cells, Hematoxylin-eosin staining*

Cite this article as: Alireza Yousofi, Negin Jafari, Sara Varzandian, Elham Faghieh Shirazi. Evaluation of the effect of topical ointment of 10% hydroalcoholic extract of Pistachio peel on wound healing in rat: a histological study. *J Altern Vet Med.* 2022; 5(14): 826-835.

* Corresponding Author

Department of Clinical Sciences, Veterinary Faculty, Kazerun Branch,
Islamic Azad University, Kazerun, Iran.

E-mail: alireaza.yousofi@iau.ac.ir, Orcid: <https://orcid.org/0000-0003-3919-9195>

Introduction

Skin is the largest organ of the body and has a critical role in different processes such as hydration, protection from chemicals and pathogens, vitamin D synthesis initialization, excretion and thermal regulation. The loss of the integrity of the skin can cause damage and diseases for a person, which leads to physical disabilities and even death; therefore, one of the most important issues that medical science has faced so far is the issue of treating wounds. A wound means the destruction of the anatomical and functional structure of the skin (Tottoli *et al.*, 2020; Ghaderi & Afshar, 2014). Wound healing is a complex and organized process characterized by tissue changes, which include increased vascularization, cell proliferation, and extracellular matrix synthesis (Rosińczuk *et al.*, 2018; Bueno *et al.*, 2016). Several studies have drawn attention to the protective effects of medical plants on wound healing (Gál *et al.*, 2009; Ghaderi & Afshar, 2014; Estevão *et al.*, 2013b). Herbal medications have special characteristics which distinguish them from chemical drugs. Several plants have been used to investigate their therapeutic properties on wound healing, but the therapeutic efficacy of these plants is still controversial. Pistachio has been known for its medicinal properties since ancient times and belongs to the Anacardiaceae family, which grows in the Mediterranean and Central Asian countries such as Turkey, Iran, etc (Magiatis *et al.*, 1999). Pistachio and its skin are rich sources of phenolic, antioxidant and anti-inflammatory compounds such as Gallotannins, Myricetin, Gallic acid and Quercetin and are among the top 50 rich sources of phenolic compounds; these compounds are more found in pistachio skin than pistachio kernel (Salari Sedigh *et al.*, 2022). As reported in traditional folk medicine, pistachio has a variety of therapeutic and pharmacological effects such as anti-inflammatory, antioxidants, antibacterial, antimicrobial, and antifungal (Ghaseminasabparizi *et al.*, 2015; Assar *et al.*, 2019; Oliveira *et al.*, 2008). Studies show that the tendency to investigate the therapeutic properties of pistachio skin is higher than other applications, and research on various therapeutic effects is ongoing. For example, the antibacterial effect of hydroalcoholic (methanolic) extract prepared from fresh pistachio skin on gram-positive bacteria isolated from clinical samples

showed that this extract is completely effective on the mentioned bacteria (Peirovi-Minaee, 2021).

To the best of the authors' knowledge, there is no standard treatment for skin wounds, and the current drugs have various side effects. On the other hand, there is no previous report about the evaluation of the impacts of Pistacia peel extract on skin wound healing. Thus, this study was designed to investigate the effects of Pistacia peel extract on the healing of skin wound in rats at different time points (days 4, 7, 14 and 21 of the experiment) by using histological evaluations and measuring different cells involved in the healing.

Materials and Methods

Animals and grouping

Twenty male rats with an average age of 6 months and an average weight of 200 grams were kept for three weeks in the same temperature and feeding conditions temperature of 20 to 30 degrees Celsius and 12 hours of light and 12 hours of darkness. Also, they had access to water and food and were away from pollution. Rats were studied in two groups. Twenty male rats were randomly allocated to two experimental groups (n=10). The first group without treatment and the second group treated with hydroalcoholic ointment were prepared from the pure extract of pistachio peel.

Preparation of pistachio peel extract

Dried pistachios were collected from Sirjan, Iran. To prepare the extract, Pistachio skin was pulverized (100 g) and soaked in 500 mL of ethanol (70%) for 72 h. The extract was then concentrated in a rotary under low pressure and stored at -20°C.

Wound induction

On the day of operation, rats were anesthetized by intraperitoneal injection of ketamine (5%) 35 mg/kg and diazepam 5 mg/kg. The backs of all animals were completely shaved and the Skin wound was created in a circular shape with a diameter of 2 cm. 24 hours after the wound, treated with 10% pure pistachio peel extract ointment, It was begun and continued until the 21 day. The wounds were photographed using a digital camera at a fixed distance of 20 cm on 4, 7, 14, and 21 days. The percentage of wound closure was calculated using the following formula:

% wound Closure = $\frac{\text{Initial wound size} - \text{Wound size at each time}}{\text{Initial wound size}} \times 100$.

Histopathological examinations

In this study, tissue samples were taken from the rat of both groups on 4, 7, 14, and 21 days. Following fixation of the tissue samples in 10% formalin, samples were dehydrated using graded alcohol series. Afterwards, skin samples were cleared in xylene and then embedded in paraffin wax. Serial sections of 5- μ m were prepared and stained with hematoxylin-eosin (H&E) and Masson's trichrome for routine histopathological evaluation. All slides were investigated in a blinded manner by a pathologist. Qualitative comparison based on the extent and severity of the wound, edema cells, angiogenesis, fibroblast cells and fibrocytes, and the formation and order of collagen fibers were scored with number 1 as the lowest score and 5 as the highest score.

Statistical analysis

All the data analyses were performed using SPSS software. Normal distribution was evaluated by the Kolmogorov-Smirnov test. The Student T-test was used to compare the means of the 2 groups with normal distribution values. All values are expressed as Mean \pm SEM. P-values less than 0.05 were considered as statistically significant.

Results

The macroscopic wound assessment was performed within 21 days and recorded in photographs. According to the results of our research, the extent and severity of the wound in the treated group were significantly reduced compared to the control group. The macroscopic alterations of the wound area are displayed in Figure 1.

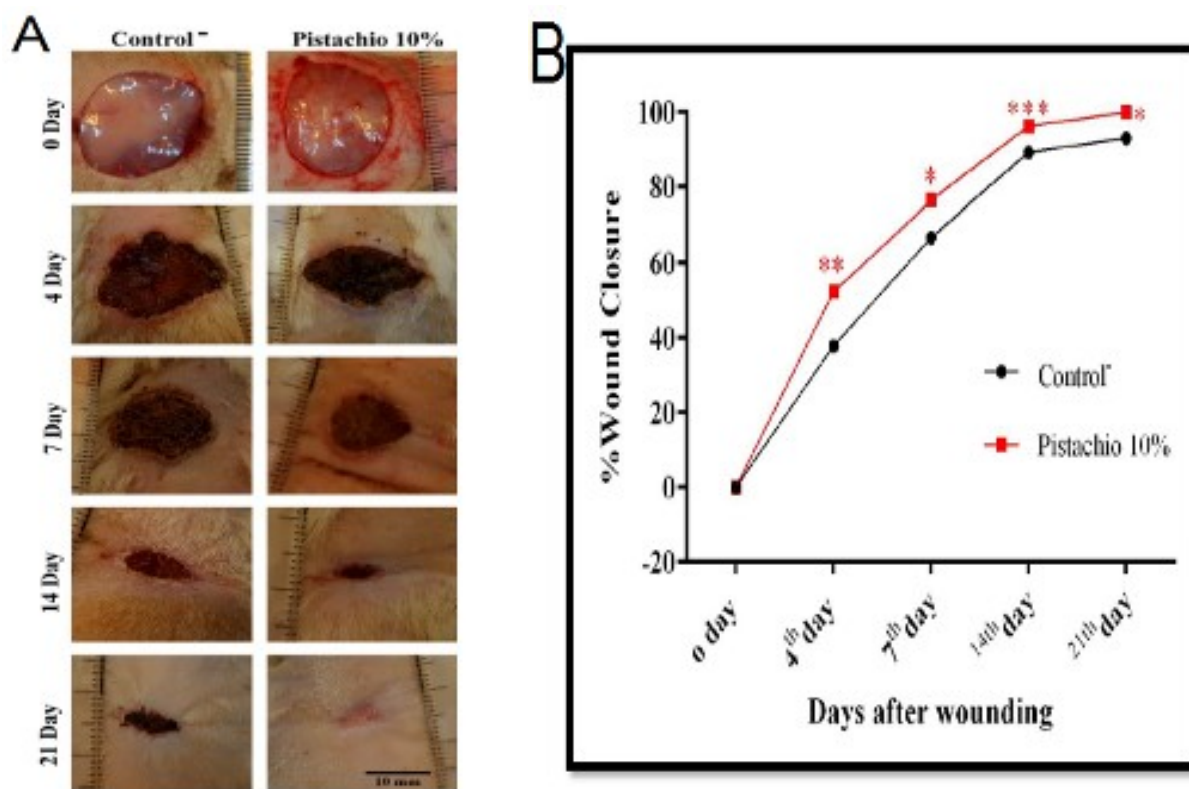


Figure 1. The results related to the extent and severity score of the wound in two groups. A: The percentage of Wound closure on days 0, 4, 7, 14 and 21 in two groups. B: Photographs of the macroscopic observations of excision wound on days 0, 4, 7, 14 and 21. *P<0.05, **P<0.01, ***P < 0.001 versus control group.

A significant difference (P<0.05) was observed between Pistachio peel extract -treated animals and the control on the days 14 and 21, and the wound was found to be almost healed on day 21 in the treated

group with no scar. The results related to the formation and order of collagen fibers, number of fibrocytes and fibroblast, angiogenesis, swollen cells and wound area are presented in table 1. Also, the

results related to the percentage of wound closure in the treated groups on days 4 ($P<0.01$), 7 ($P<0.05$), 14 ($P<0.001$), and 21 ($P<0.05$) have decreased significantly compared to the control group. And the average wound area in the treated group on days 4 ($P<0.01$), 7 ($P<0.05$), 14 ($P<0.001$), and 21 ($P<0.001$) has decreased significantly compared to the control group (Figure 2). Also a significant decrease in the score of swollen cells in the treated group compared to the control group was observed on day 21 ($P<0.05$). But there was no significant difference in the angiogenesis score on different days in both groups (Figure 3). The results of this research showed

that the number of fibrocyte and fibroblast cells in the treated group increased significantly on days 14 and 21 compared to the control group ($P<0.05$) (Figure 4). Furthermore, the formation and order of collagen fibers also show a significant increase in the score of this parameter in the treated group on days 14 and 21 ($P<0.05$) compared to the control group (Figure 5). The microscopic photographs of histopathological evaluation of wound healing are displayed in Figure 6. Therefore, according to the results of this research, application of Pistachio peel extract exhibited a considerable potential in wound healing activity.

	Control				Pistachio 10%			
	4th Day	7th Day	14th Day	21st	4th Day	7th Day	14th Day	21st
Formation and order of collagen fibers	1±0.11	1.5±0.13	3±0.27	3±0.29	2±0.73	3.5±0.61	4±0.70	5±0.82
Number of fibrocytes and fibroblast	1±0.14	1.5±0.23	3±0.37	3±0.61	2.5±0.33	3.5±0.72	4±0.87	4±0.65
Angiogenesis	1±0.21	2±0.19	3±0.54	3±0.58	2±0.36	4.5±0.78	4±0.66	2±0.32
Swollen cells	5±0.36	4±0.39	4±0.43	3±0.71	3.5±0.29	3±0.65	3±0.53	1±0.19
Wound area (mm)	5±0.28	4±0.42	4±0.19	3±0.49	4±0.45	3±0.55	3±0.75	1±0.12

Table 1. The results related to the formation and order of collagen fibers, number of fibrocytes and fibroblast, angiogenesis, swollen cells and wound area in two groups.

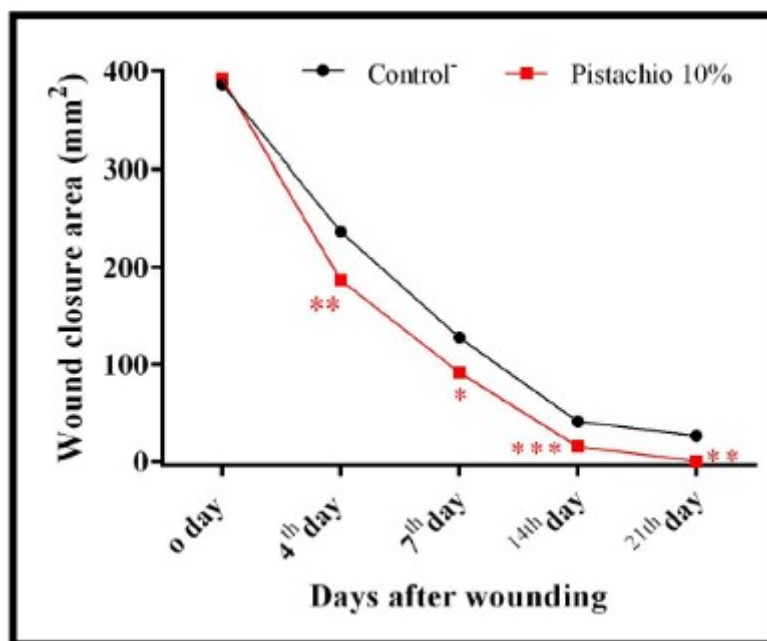


Figure 2. The results related to the wound closure percent score and wound closure area score of the wound in two groups.

* $P<0.05$, ** $P<0.01$, *** $P<0.001$ versus control group.

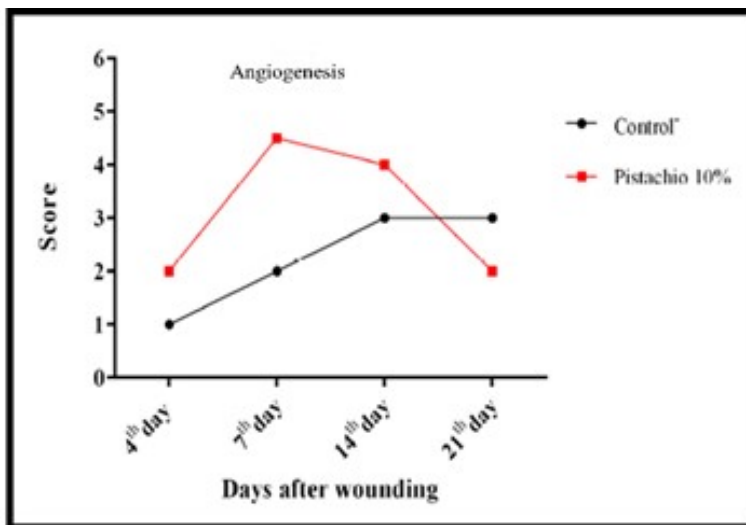


Figure 3. The results related to the swollen cells score and angiogenesis score in two groups

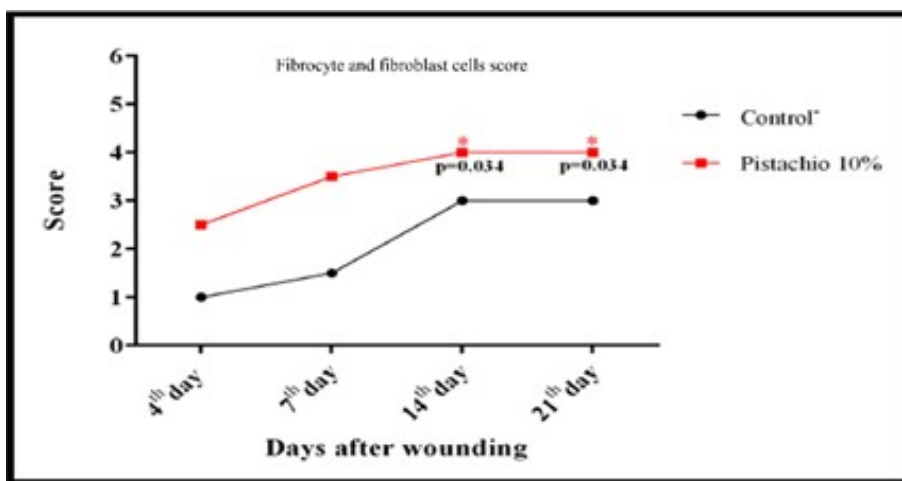


Figure 4. The results related to the fibrocyte cells score and fibroblast cells score in two groups. * P<0.05 versus control group.

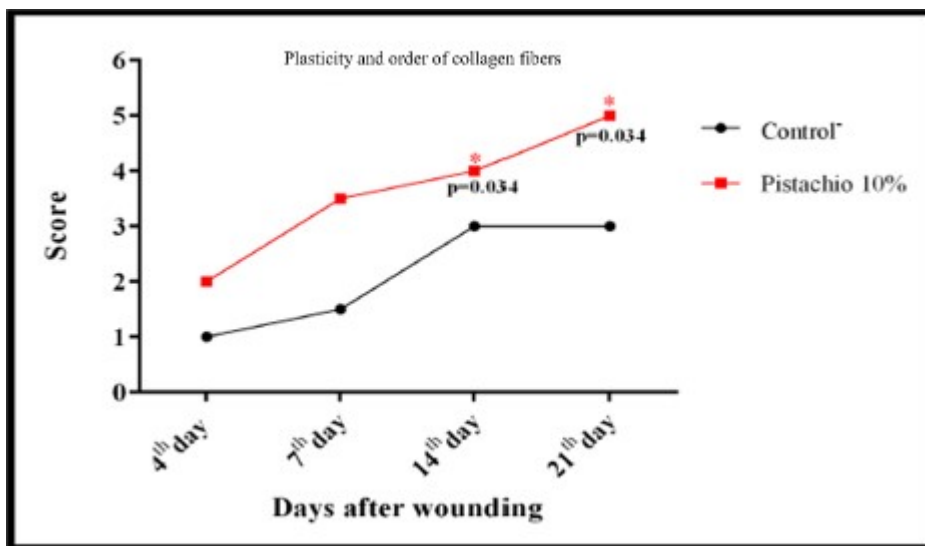


Figure 5. The results related to formation and order of collagen fibers score in two groups. *P<0.05 versus control group.

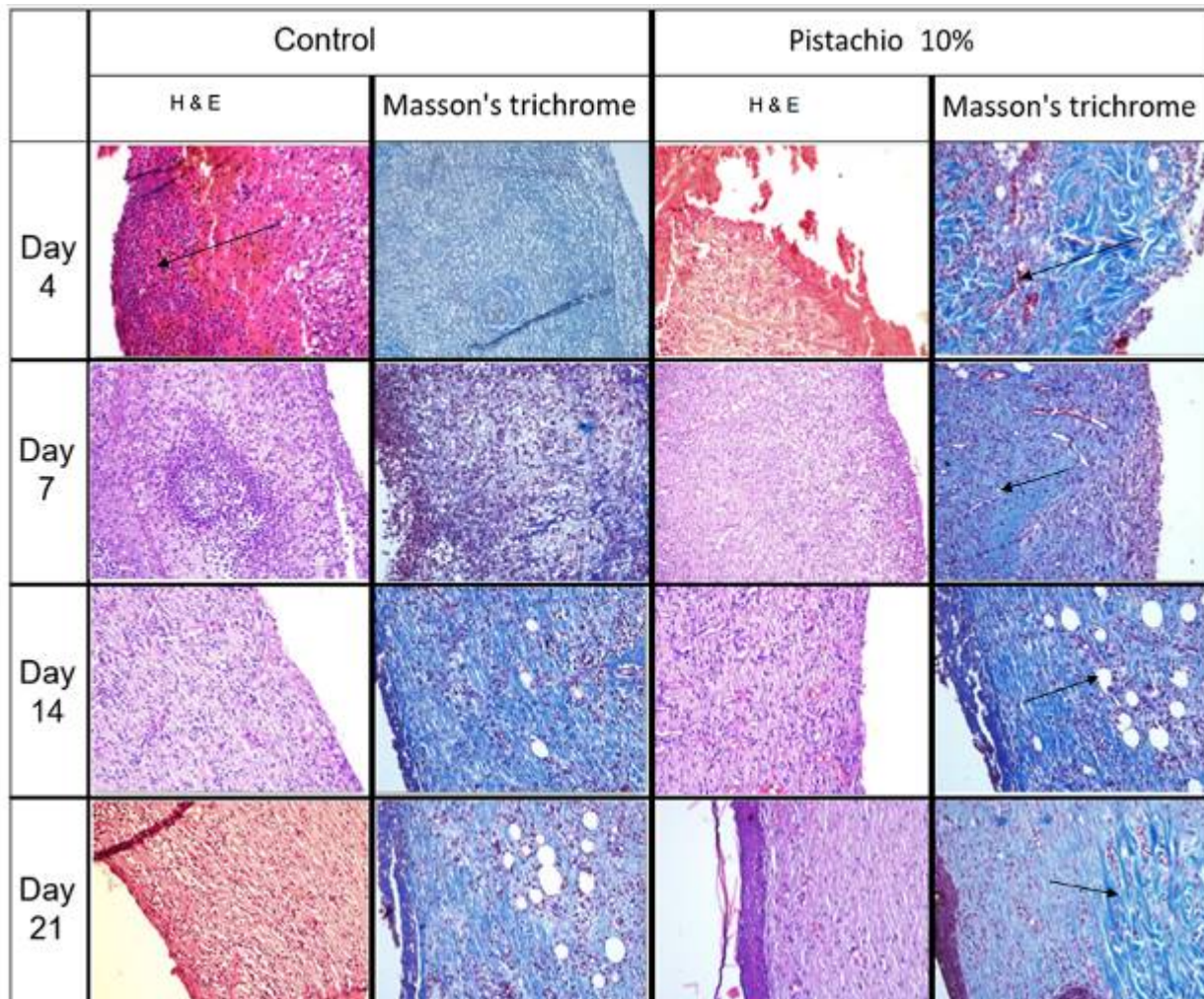


Figure 6. On day 4, a high level of edematous cells was seen. On the 7th day, the reduction of edema cells and the beginning of angiogenesis were seen. On the 14th day, vessels can be seen in large numbers and fibrocyte and fibroblast cells increased. On the 21st day, the collagen fiber number increased and became more regular.

Discussion

Breakdown in natural anatomic structure and function of the skin, known as skin wound, which could occur through several causes including physical injuries, may lead to the opening and disruption of the skin. Wound healing is a dynamic, complex process that involves soluble mediators, blood cells, extracellular matrix and parenchymal cells. The process of wound healing involves three overlapping phases of events, including inflammatory, proliferative and remodeling phases (Davoodi-Roodbordeii *et al.*, 2019).

We herein attempted to use 10% hydroalcoholic extract of pistachio peel on an animal model of skin wound to verify the hypothesis that this formulation could demonstrate a distinguished treatment in healing wounds by providing an enhanced tissue

repair. Our results revealed that the topical administration of 10% hydroalcoholic extract of pistachio peel on a rat excision wound model leads to a significant improvement in wound healing after 4, 7, 14 and 21 days, a finding confirmed by an increased wound closure percentage compared to the control group. This enhanced potential of wound healing may be due to anti-inflammatory, antimicrobial properties of the plant, which are well documented in the literatures (Aliyari *et al.*, 2020; Bakhshi & Bagherzade, 2021). In line with our findings, Taghipour *et al.*, evaluated the effects of pistachio oil on skin burn wounds. They demonstrated that 10% pistachio oil has beneficial effects on burn wound healing compared to dexpanthenol (Taghipour *et al.*, 2018).

According to this study's findings, pistachio extract did not affect the angiogenesis. Our results were similar to those obtained by Salari Sedigh et al., that reported pistachio extract did not affect the number of arteries (Salari Sedigh et al., 2022). Although, in a study by Haghdoost et al., the effect of *Pistacia atlantica* resin on burn wound healing were attributed to the improvement of angiogenesis after 14 days (Haghdoost et al., 2013).

The first stage of wound healing is the inflammatory phase, in which edema occurs ((Davoodi-Roodbordeii et al., 2019). Prolonged or excessive edema should be prevented, since it can increase the risk of tissue ischemia and infection and thereby delay the healing process (Aliyari et al., 2020). Edema is defined by visible swelling of the skin caused by the uncompensated filtration of fluid from the blood to tissues due to increased vasodilatation, extravascular osmotic activity, and microvascular permeability. This vascular effect appears as a post-wound acute inflammatory response. The results of this research showed that a significant decrease in the score of swollen cells in the treated group. The suggested mechanism for anti-inflammatory effects of pistachio ointment is by inhibiting Cox-2 which leads to decreasing prostaglandin E2 (PGE2) and TNF- α in the wound healing area (Rahimi et al., 2013). Also, Pistachio consists of high amounts of antioxidants and essential materials that are known for accelerating the healing process. Previously, it is reported two major Iranian native Pistachio species such as (*Pistacia Atlantica* and *Pistacia khinjuk*) possess antibacterial activity in wound healing. Also, the antibacterial property of pistachio is effective in reducing and scavenging the superoxide anions. Therefore, both antibacterial and anti-inflammatory properties of pistachio are responsible for wound healing (Meftahizade, 2011). In our study, the score of swollen cells in the treated group compared to the control group was decreased, which could be because of Oleanonic acid in pistachio, which inhibits phospholipase A2-induced edema (Estevão et al. 2013a). The second phase of wound healing is the proliferative phase. In this phase, wound closure occur via keratinocytes and fibroblasts (Karina Samudra et al., 2019). Fibroblasts are critical in all three phases, playing a key role in the deposition of extracellular matrix (ECM) components, wound contraction and remodeling of new ECM (desJardins-

Park et al., 2018) Fibroblasts also secrete growth factors to stimulate the wound repair and synthesize ECM such as collagen and fibronectin for ECM fibers generation and rearrangement (Worthen et al., 2020). The results of our research showed that the number of fibrocyte and fibroblast cells in the treated group increased significantly on days 14 and 21. In addition, topical administration of 10% hydroalcoholic extract of pistachio peel was found to significantly increase the formation and order of collagen fibers compared to the control wounds. Similar observations have also been reported by Pourjabali et al., who concluded that there was a significant difference in the thickness of skin and collagen diameter, and reduction of edema between experimental and control groups (Pourjabali et al., 2022). Collagen is the main structural protein component of connective tissue. Chvapil et al., demonstrated that collagen sponge enhances the connective tissue formation and increases the vascularization of the repaired tissue. Therefore it is known that collagen effectively increases the process of healing. Collagen also enhances suitably modulated collagen lysis and favours a more orderly fibroblast proliferation, probably by acting as a recruiting factor for these cells and taking part in their metabolism directly (Chvapil et al., 1986; Süntar et al., 2011). In the present study, the order of collagen fibers and numbers of fibroblasts showed a significant increase. Hence, the wound healing effects of 10% hydroalcoholic extract of pistachio peel used in this study were most likely due to their effects on the stimulation of collagen activity and fibroblast proliferation. However, further studies are required to clarify the efficacy and action mechanism of hydroalcoholic extract of pistachio peel on wound healing.

Conclusion

The study and evaluations of medicinal plants are essential because of alternative therapies and their therapeutic application. Hence, synthetic drugs may have side effects but the drugs of plants are safe, so they can be used to treat wounds. In this study, both macroscopic and microscopic findings showed that pistachio peel ointment had a curative effect on wound healing. By the present study, we recommend further research needed to clarify possible interaction on wound healing pathways of pistachio peel ointment.

Conflict of interest

None.

References

- Aliyari P., Bakhshi Kazaj F., Barzegar M. and Ahmadi Gavlighi H. Production of functional sausage using pomegranate peel and pistachio green hull extracts as natural preservatives. *J Agric Sci Technol*, 2020; 22: 159-72.
- Assar S, Fathalizadeh J, Ayoobi F, Ziaadini M, Shamsizadeh A, Kazemi Arababadi M, et al. In vitro antibacterial properties of pistachio (*Pistacia vera* L.) rosy hull phenolic extracts. *PHJ*, 2019; 2: 17-29.
- Bakhshi O. and Bagherzade G. Biosynthesis of organic nanocomposite using *Pistacia vera* L. hull: An efficient antimicrobial agent. *Bioinorg Chem Appl*, 2021; 4105853.
- Bueno FG., Moreira EA., Morais GR., Pacheco IA., Baesso ML., Leite-Mello EV., et al. Enhanced cutaneous wound healing in vivo by standardized crude extract of *Poincianella pluviosa*. *PLoS One*, 2016; 11(3): e0149223.
- Chvapil M., Chvapil TA. and Owen JA. Reaction of various skin wounds in the rat to collagen sponge dressing. *J Surg Res*, 1986; 41(4): 410-8.
- Davoodi-Roodbordeii F., Afshar M., Haji Abas Tabrizi F., Choopani S., Torkaman G., Moayer F., et al. Topical hydrogel containing *Fumaria vaillantii* Loisel. extract enhances wound healing in rats. *BMC Complement Altern Med*, 2019; 19(1): 254.
- desJardins-Park HE., Foster DS. and Longaker MT. Fibroblasts and wound healing: an update. *Regen Med*, 2018; 13(5): 491-495.
- Estevão LR., Mendonça Fde S., Baratella-Evêncio L., Simões RS., Barros ME., Arantes RM., et al. Effects of aroeira (*Schinus terebinthifolius* Raddi) oil on cutaneous wound healing in rats. *Acta Cir Bras*, 2013a; 28(3): 202-9.
- Estevão LR., Medeiros JP., Baratella-Evêncio L., Simões RS., Mendonça Fde S. and Evêncio-Neto J. Effects of the topical administration of copaiba oil ointment (*Copaifera langsdorffii*) in skin flaps viability of rats. *Acta Cir Bras*, 2013b; 28(12): 863-9.
- Gál P., Toporcer T., Grendel T., Vidová Z., Smetana K Jr., Dvoránková B., et al. Effect of *Atropa belladonna* L. on skin wound healing: biomechanical and histological study in rats and in vitro study in keratinocytes, 3T3 fibroblasts, and human umbilical vein endothelial cells. *Wound Repair Regen*, 2009; 17(3): 378-86.
- Ghaderi R. and Afshar M. Novel advancements in wound healing. *J Birjand Univ Med Sci*, 2014; 21(1): 1-19.
- Ghasemynasabparizi M., Ahmadi A. and Mazloomi S. A review on pistachio: Its composition and benefits regarding the prevention or treatment of diseases. *J Occup Health Epidemiol*, 2015; 4(1): 57-69.
- Haghdoust F., Baradaran Mahdavi MM., Zandifar A., Sanei MH., Zolfaghari B. and Javanmard SH. *Pistacia atlantica* Resin Has a Dose-Dependent Effect on Angiogenesis and Skin Burn Wound Healing in Rat. *Evid Based Complement Alternat Med*, 2013; 2013: 893425.
- Magiatis P., Melliou E., Skaltsounis AL., Chinou IB. and Mitaku S. Chemical composition and antimicrobial activity of the essential oils of *Pistacia lentiscus* var. *chia*. *Planta Med*, 1999; 65(8): 749-52.
- Meftahizade H. Evaluation of antibacterial activity and wound healing of *Pistacia atlantica* and *Pistacia khinjuk*. *J Med Plant Res*, 2011; 5: 4310-14.
- Oliveira I., Sousa A., Ferreira IC., Bento A., Estevinho L. and Pereira JA. Total phenols, antioxidant potential and antimicrobial activity of walnut (*Juglans regia* L.) green husks. *Food Chem Toxicol*, 2008; 46(7): 2326-31.
- Peirovi-Minaee R. Different applications of pistachio skin. *PHJ*, 2021; 4: 1-6.

- Pourjabali M., Zarei L. and Ezzati Sarai V. Evaluation of the effect of topical pistachio hull hydroalcoholic extract ointment on wound healing in rat: a histologic and planimetric study. *SJKU*, 2022; 27(3): 12-22.
- Rahimi R., Baghaei A., Baeceri M., Amin G., Shams-Ardekani MR., Khanavi M., et al. Promising effect of Magliasa, a traditional Iranian formula, on experimental colitis on the basis of biochemical and cellular findings. *World J Gastroenterol*, 2013; 19(12): 1901-11.
- Rosińczuk J., Taradaj J., Dymarek R. and Sopel M. Mechanoregulation of wound healing and skin homeostasis. *Biomed Res Int*, 2016; 2016: 3943481.
- Salari Sedigh S., Mozafari A., Sadeghi M., Eslammanesh T. and fatemi, I. Oral Wound Healing Activities of Pistacia vera Hydroalcoholic Extract. *PHJ*, 2022; 5(1): 3-10.
- Karina Samudra MF., Rosadi I., Afni I., Widyastuti T., Sobariah S., Remelia M., et al. Combination of the stromal vascular fraction and platelet-rich plasma accelerates the wound healing process: pre-clinical study in a Sprague-Dawley rat model. *Stem Cell Investig*, 2019; 6: 18.
- Süntar I., Akkol EK., Keleş H., Oktem A., Başer KH. and Yeşilada E. A novel wound healing ointment: a formulation of Hypericum perforatum oil and sage and oregano essential oils based on traditional Turkish knowledge. *J Ethnopharmacol*, 2011; 134(1): 89-96.
- Taghipour Z., Hassanipour M., Mohammadian B., Khanjari A., Taghizadeh R., Kaeidi A., et al. The effects of the topical administration of Pistacia vera oil on the second-degree burn model in rats', *PHJ*, 2018; 1(2): 7-11.
- Tottoli EM., Dorati R., Genta I., Chiesa E., Pisani S. and Conti B. Skin wound healing process and new emerging technologies for skin wound care and regeneration. *Pharmaceutics*, 2020; 12(8): 735.
- Worthen CA., Cui Y., Orringer JS., Johnson TM., Voorhees JJ. and Fisher GJ. CD26 identifies a subpopulation of fibroblasts that produce the majority of collagen during wound healing in human skin. *J Invest Dermatol*, 2020; 140(12): 2515-2524.e3.



ارزیابی اثرات پماد موضعی عصاره هیدروالکلی ۱۰ درصد پوست پسته بر روی فرآیند ترمیم زخم در موش صحرائی: یک مطالعه بافت شناسی

علیرضا یوسفی^{۱*}، نگین جعفری^۱، سارا ورزندیان^۱، الهام فقیهی شیرازی^۲

^۱گروه علوم بالینی، دانشکده دامپزشکی، واحد کازرون، دانشگاه آزاد اسلامی، کازرون، ایران
^۲گروه علوم بالینی، دانشکده دامپزشکی، واحد کازرون، دانشگاه آزاد اسلامی، کازرون، ایران

تاریخ دریافت: ۱۴۰۱/۰۷/۱۶ اصلاح نهایی: ۱۴۰۱/۰۸/۲۰ تاریخ پذیرش: ۱۴۰۱/۰۹/۰۱

چکیده

زمینه و هدف: از دست رفتن انسجام پوست می تواند باعث ایجاد آسیب و بیماری برای یک شخص شود که منجر به ناتوانی جسمی و حتی مرگ گردد. بنابراین یکی از مهم ترین مشکلاتی که علم پزشکی با آن مواجه است. درمان زخم می باشد. هدف این مطالعه بررسی هیستوپاتولوژیک ترمیم زخم پوستی در موشهای صحرائی تر و یستار با پماد موضعی حاوی عصاره هیدروالکلی ۱۰ درصد پوست پسته بود.

مواد و روش ها: بیست موش صحرائی نر به صورت تصادفی به دو گروه تقسیم شدند. (n=۱۰) یک زخم پوستی به شکل حلقوی به قطر ۲ سانتی رو بخش پشتی حیوانات ایجاد شد. گروه یک به عنوان گروه کنترل در نظر گرفته شد. گروه ۲ پماد هیدروالکلی آماده شده از عصاره خالص پوست پسته را دریافت کرد. ۲۴ ساعت بعد از ایجاد زخم درمان با پماد هیدروالکلی ۱۰ درصد پوست پسته آغاز شد و تا روز ۲۱ ادامه پیدا کرد. و فرآیند ترمیم زخم در روزهای ۴، ۷، ۱۴ و ۲۱ ارزیابی گردید. حیوانات بیهوش شدند و نمونه های پوستی برداشته شدند. به علاوه مقدار بسته شدن زخم با استفاده از محاسبه مساحت زخم توسط آنالیزهای آماری با استفاده از نرم افزار SPSS و t-test ارزیابی شد.

یافته ها: بر اساس نتایج عصاره هیدروالکلی پوست پسته در ترمیم زخم موثر واقع شده و روند ترمیم زخم را تسریع می بخشد. نتایج ما نشان می دهد میانگین سایش زخم و تعداد سلول های التهابی در گروه های درمان کاهش پیدا کرده است. اما تعداد فیبروسایت ها و فیبروبلاست ها تشکیل و نظم فیبر های کلاژن در گروه های درمان افزایش یافته بود.

نتیجه گیری: این مطالعه پیشنهاد می کند که درمان موضعی با عصاره هیدروالکلی ۱۰ درصد پوست پسته می تواند به عنوان درمان کلینیکال برای تسریع روند بهبود زخم ها استفاده گردد.

واژه های کلیدی: عصاره پوست پسته، ترمیم زخم، مطالعات بافت شناسی، سلول های التهابی، رنگ آمیزی هماتوکسیلین-انوزین

علیرضا یوسفی، نگین جعفری، سارا ورزندیان، الهام فقیهی شیرازی. ارزیابی اثرات پماد موضعی عصاره هیدروالکلی ۱۰ درصد پوست پسته بر روی فرآیند ترمیم زخم در موش صحرائی: یک مطالعه بافت شناسی. مجله طب دامپزشکی جایگزین. ۱۴۰۱؛ ۵ (۱۴): ۸۲۶-۸۳۵