



## Investigating the Accuracy, Sensitivity and Specificity of Ultrasound-Guided Fine Needle Aspiration in the Diagnosis of Spleen Masses in Dogs

Hila Askari<sup>1</sup>, Siamak Alizadeh<sup>2\*</sup>

<sup>1</sup>Graduate of Veterinary Medicine, Faculty of Veterinary Medicine, Urmia Branch, Islamic Azad University, Urmia, Iran

<sup>2</sup>Department of Clinical Sciences, Faculty of Veterinary Medicine, Urmia Branch, Islamic Azad University, Urmia, Iran

Received: 19/Mar/2023

Revised: 20/Apr/2023

Accepted: 27/Apr/2023

### Abstract

**Background and aim:** Ultrasound-guided fine-needle aspiration has been accepted as a reliable tool in diagnosing and staging intra-abdominal tumors. The purpose of this research was to investigate the value of fine needle aspiration with the help of ultrasound in diagnosing local lesions of the spleen in dogs.

**Materials and Methods:** This study used twenty dogs (twelve males and eight females) suspected of spleen malignancy with a mean age of 9.3 years. The ultrasonography of each dog was prepared in the ventrodorsal and right lateral recumbency. The dogs were scanned by subcostal and intercostal methods. Sampling was done with the help of spinal needle No. 21 with a length of 10 cm (through fine needle aspiration). The results of aspiration were compared with the results of biopsy, surgery, other clinical examinations, radiological information, and subsequent ultrasonography during the treatment period. After summarizing and final diagnosis, the diagnostic value of fine needle aspiration was evaluated by calculating its accuracy, specificity, and sensitivity.

**Results:** According to our results, the accuracy of this method was 92%, and the sensitivity and specificity of this technique for malignant spleen lesions were 93.5% and 91%, respectively. It should be noted that most of the false negative cases that occurred may be due to the small size of the lesion (less than 5 mm in diameter) and the depth of the lesions (more than 4.5 cm from the surface), that the conditions caused technical problems in performing aspiration.

**Conclusion:** According to the results of our study, the fine needle aspiration technique can be an easy, low-risk, and very effective method in malignant lesions diagnosed in the spleen.

**Keywords:** *Fine needle aspiration, Spleen mass, Dog, Ultrasonography*

**Cite this article as:** Hila Askari, Siamak Alizadeh. Investigating the accuracy, sensitivity and specificity of ultrasound-guided fine needle aspiration in the diagnosis of spleen masses in dogs. *J Altern Vet Med.* 2023; 6(16): 946-952.

### \* Corresponding Author

Department of Clinical Sciences, Faculty of Veterinary Medicine, Urmia Branch,  
Islamic Azad University, Urmia, Iran.

E-mail: [s\\_alizadeh01@yahoo.com](mailto:s_alizadeh01@yahoo.com), Orcid: <https://orcid.org/0000-0003-1112-7026>



## Introduction

The word spleen is derived from the Greek word (Splēn) and this organ is usually affected by diseases. The differential diagnosis of splenic masses includes malignancy (lymphoma and metastatic disease), infection (tuberculosis, fungal), and infiltrative processes such as sarcoidosis (McInnes *et al.*, 2011). Cross-sectional can identify splenic masses, but cannot distinguish lesions from each other. Histology is very important in diagnosing the type of lesion, but it is suggested when there is no other method for histological diagnosis (Hughes *et al.*, 2019). Splenic tissue samples can be obtained by splenectomy, percutaneous biopsy, and ultrasound guidance (Kelsey *et al.*, 2022). In the percutaneous biopsy method, there is a risk of splenic capsule rupture as a result of inspiration and expiration (Jeong *et al.*, 2013). Metastasis in the spleen can occur following some malignant tumors of the mammary glands, lung, ovary, colorectal, and melanoma (Rinaldi *et al.*, 2022) and most of the reported metastases in the spleen are associated with the spread of multi-visceral tumors. The rarity of splenic metastases can be due to the type of splenic lymphatic system, the angle of the splenic artery branching from the celiac trunk, and the type of splenic tissue that prevents the growth of micrometastatic foci (Balekuduru *et al.*, 2020).

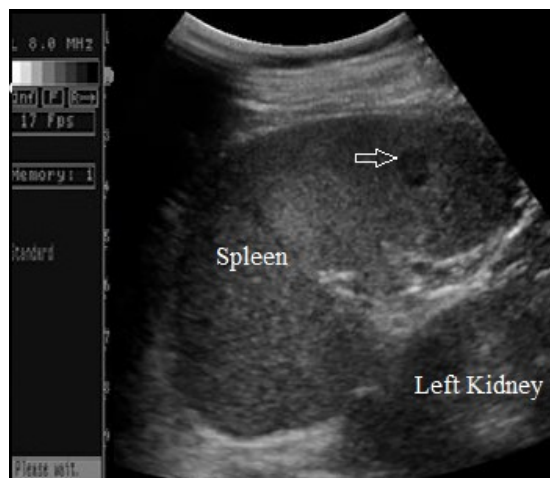Diagnosing the nature of visceral masses, especially in the spleen, is important and is always discussed. Due to the ease of the ultrasound method, its availability and safety, it is the first method of choice in diagnosing masses in the ventricular area as well as the spleen. Also, ultrasound has been introduced as a very effective guide for fine needle aspiration of spleen lesions (Fornarif, 1992; Finora *et al.*, 2006; Dusenbery *et al.*, 1995).

Since the histopathological diagnosis of spleen lesions is very accurate, therefore, this method plays an important role in the final decision and treatment of patients (Watson *et al.*, 2021). So it seems that the existence of this easy, low-risk, effective and accurate technique in diagnosing the type of splenic lesions has great value. Fine needle aspiration has rare limitations and contraindications, and performing it together with ultrasonography can be very useful. The complications and risks of this method for the patient are very minor and can be ignored (Bigge *et al.*, 2020; Hanson *et al.*, 2018). Financially, the costs of this method are also low due to the fact that the patient is

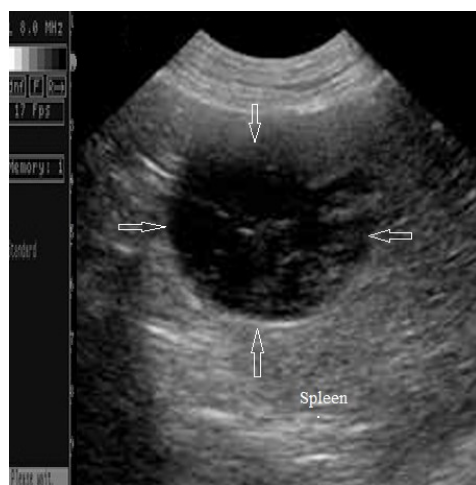
not hospitalized. Considering the importance of the contents mentioned above, it seems that we should conduct more studies in this field and determine the sensitivity and specificity of this effective technique. The purpose of this research was to investigate the accuracy, sensitivity and specificity of the value of fine needle aspiration by ultrasound guide in diagnosing patients with suspected spleen malignancy in dogs.

## Materials and Methods

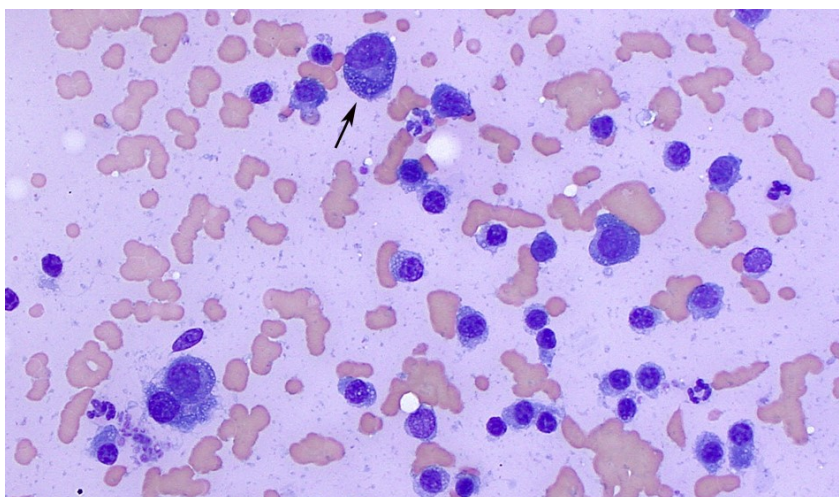
In the present study, 20 dogs (12 males and 8 females with an average age of 9.3 years) suspected of spleen malignancy such as hemangioma, hemangiosarcoma (Figure 1), lymphoma, lymphosarcoma, mast cell tumors, plasma cell and multiple myeloma and leiomyosarcoma of the spleen (Figure 2) were investigated. An EUB-8500 XP ultrasound machine (Hitachi Medical Corporation, Tokyo, Japan) and a linear probe with a frequency of 8 MHz (EUP-L54M, length: 53 mm) were used for ultrasound, and evaluations were done by a veterinary radiologist. The average examination time of each patient was five to ten minutes. Ultrasonography of these dogs were obtained from dorsoventral, and left and right lateral recumbency. The dogs were scanned using subcostal and intercostal methods. First, the spleen and its area were examined by ultrasonography and after determining the most appropriate and shortest route, sampling of the lesion was done by a 10 cm long spinal needle No. 21. To increase the accuracy of sampling from some of the masses, several punctures were made (Figures 3 and 4). The deepest lesion that underwent needle aspiration was located 5 cm from the skin surface. The diameter of the smallest and largest mass was 5 and 22 mm, respectively. Five microscopic slides were prepared from each dog and sent to the pathology laboratory for cytological examination. Patients with blood coagulation problems, obvious vascular lesions, hydatid cyst lesions, severe splenic hyperemia, and severe ascites in the abdominal cavity were not examined in this study due to possible risks. The results of aspiration were compared with the results of biopsy, surgery and other clinical examinations and radiological and ultrasonographic information and after summarizing and definitive diagnosis, accuracy, specificity and sensitivity and diagnostic value of fine needle aspiration were calculated.



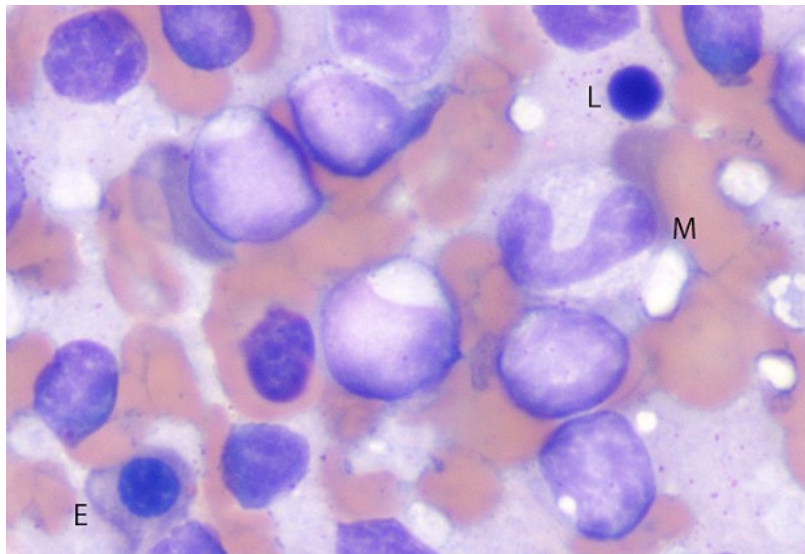
**Figure 1.** Sagittal sonogram of splenic hemangiosarcoma (arrow) in a 10-year-old male hybrid dog.



**Figure 2.** Sagittal sonogram of splenic leiomyosarcoma (arrows) in a 13-year-old female German Shepherd.



**Figure 3.** Aspiration from the spleen of a dog with multiple myeloma. The spleen has numerous plasma cells. These cells have eccentric nuclei with a clear perinuclear region in the cytoplasm (arrow).



**Figure 4.** Aspiration from the spleen of a dog with lymphoma. In this smear, can be seen a small number of residual elements of the spleen, including a monocyte (M), a multi-chromatophilic nucleated red blood cell (E) and a small mature lymphocyte (L).

**Results**

Out of 20 fine needle aspiration tests, in 15 cases the definitive diagnosis of malignancy was confirmed by surgical and biopsy methods, which was consistent with the results of needle aspiration cytology (15 true positive cases) (Table 1). Of the remaining 3 cases, the definitive diagnosis of malignancy did not match the needle aspiration results (3 false negative cases). In 2 cases, due to the inappropriateness of the sample, cytology was not possible and the sample was reported to have no diagnostic value. In these 2 cases, the size of the lesion was about 4 mm and its depth was more than 4.5 cm, which technically made it difficult to perform aspiration and caused that either the amount of sample was insufficient or it was taken from the wrong place (The sample was taken from the necrotic part of the mass). In one of the three false negative cases, despite the large size of the lesion (10

mm) and the short distance to the skin surface, the result of cytology was negative, which seems that there was no problem in performing the aspiration, and a sufficient and suitable sample was sent to the laboratory and the cause false negatives in these cases were problems in the laboratory and cytology report.

In 4 cases, a definitive diagnosis of benign lesions was given. Of these, 1 case was consistent with the results of needle aspiration (3 true negative cases) and in another case, the possibility of malignancy was reported in the cytology study (one false positive case). The data were processed and analyzed with SPSS software (Version 21) after collection. In this study, the correlation coefficient was considered 70% and  $P < 0.001$ . Thus, the sensitivity, specificity and accuracy of fine needle aspiration in the diagnosis of malignant liver lesions were reported as 93.5%, 91% and 92%, respectively.

	Pathological lesions	Dog (%)
<b>Malignant lesions</b>	Hemangiosarcoma	6 (40%)
	Lymphosarcoma	3 (20%)
	Leiomyosarcoma	2 (13.33%)
<b>Benign lesions</b>	Hemangioma	2 (13.33%)
	Lymphoma	1 (6.33%)
	Mast cell, plasma cell and multiple myeloma tumors	1 (6.33%)

**Table 1.** Cases of definitive diagnosis of malignancy confirmed by surgical and biopsy methods that were consistent with the results of needle aspiration cytology.

## Discussion

Normal and common biopsies cause many complications such as bleeding at the biopsy site. In some cases, they may not provide a sufficient sample of local lesions, especially if the lesions are deep or located at the visceral level of the spleen (Balsa & Culp, 2019). Fine needle aspiration under ultrasound control, in addition to having high accuracy, sensitivity, and specificity for diagnosing spleen masses and viscera in the abdominal cavity (especially malignant lesions), can also reduce the risk and complications of biopsy. In the present study, the biopsies did not cause any complications. With this method, even visceral and deep lesions of the spleen can be easily sampled with minimal risk. In the present study, the sensitivity, specificity, and accuracy of fine needle aspiration in the diagnosis of malignant liver lesions in 20 patients were 93.5%, 91%, and 92%, respectively, which provides almost equal and similar results in comparison with previous studies (Balsa & Culp, 2019; Dusenbery *et al.*, 1995).

Most of the false negative cases in this study were due to the smallness of the lesion (diameter less than 5 mm) and its depth (distance to the skin surface more than 4.5 cm). These cases were mentioned in previous similar studies as one of the most important reasons for false negative cases (Hughes *et al.*, 2019; Turner *et al.*, 2021).

Ohlerth *et al.*, in a study on 60 dogs with suspected liver diseases stated that the specificity of the ultrasound method in detecting malignant liver masses is small and harmonic contrast imaging can be useful for differentiating between benign and malignant spleen lesions in dogs. In this research, determining the amount of specificity is different from our study. In our research, the specificity of the ultrasound method was reported to be 91%, which can be acceptable in terms of clinical application. The causes of this discrepancy can be related to the type of device, working method and data analysis (Ohlerth *et al.*, 2008).

In another study, Vanstee *et al.*, investigated the role of fine needle aspiration biopsy by ultrasonography in the diagnosis of canine spleen lymphoma and reported the high value of this diagnostic method (Vanstee *et al.*, 2015), and their results are similar to the findings of our study. Thamm *et al.*, studied 62 dogs suspected of spleen diseases and reported the sensitivity, specificity,

positive and negative predictive value of paraclinical methods such as ELISA in the diagnosis of mass lesions of the spleen to be 52, 93, 94 and 48%, respectively (Thamm *et al.*, 2012). In our study, the sensitivity and specificity of the fine needle aspiration biopsy method by ultrasonography in the diagnosis of malignant lesions of the spleen were reported as 93.5 and 91%, respectively. Also, in our study, there were no serious complications on the spleen tissue (due to aspiration), which is similar to previous studies (Pongchairerks, 2022).

Currently, this technique is one of the most accurate methods for sampling the spleen and other abdominal viscera, which can be implemented with standard ultrasound devices. It seems that fine needle aspiration is a reliable and non-life-threatening method in the diagnosis of local lesions of the spleen and is a suitable alternative to more invasive diagnostic methods.

It should be emphasized that due to the progress in diagnostic imaging techniques to detect focal parenchymal lesions and increase the life expectancy of patients with lymphomas and some other tumors, the correct diagnosis of focal lesions of the spleen is becoming an important issue in patients. Therefore, the indications of spleen biopsy are expanding and our results in this study show that fine needle aspiration biopsy with the help of spleen sonography is an effective, safe and inexpensive technique for definitive diagnosis of pathological lesions.

## Conclusion

According to the results of our study, the fine needle aspiration technique can be an easy, low-risk and very effective method in malignant lesions diagnose in the spleen.

## Acknowledgments

This study was supported by Faculty of Veterinary Medicine, Urmia Branch, Islamic Azad University, Urmia, Iran.

## Conflict of Interest

The authors declared no conflict of interest.

## References

- Balekuduru AB., Kapali AS., Kurella SP. and Subbaraj SB. Endoscopic ultrasound-guided

- transgastric fine needle aspiration of splenic metastasis. *JDE*, 2020; 11(03): 238-41.
- Balsa IM. and Culp WT. Use of minimally invasive surgery in the diagnosis and treatment of cancer in dogs and cats. *Veterinary sciences*, 2019; 6(1): 33 1-12.
- Bigge LA., Brown DJ. and Penninck DG. Correlation between coagulation profile findings and bleeding complications after ultrasound-guided biopsies: 434 cases (1993-1996). *JAAHA*, 2020; 37(3): 228-33.
- Dusenbery D., Ferris JV. and Thaete FL. Percutaneous ultrasound-guided needle biopsy of hepatic mass lesions using a cytologic approach in the small animals. *Am J Clin Pathol*, 1995; 104(5): 583-72.
- Finora K., Leibman NF., Fettman MJ., Powers BE., Hackett TA. and Withrow SJ. Cytological comparison of fine-needle aspirates of liver and spleen of normal dogs and of dogs with cutaneous mast cell tumours and an ultrasonographically normal appearing liver and spleen. *Vete and Comp Onco*, 2006; 4(3): 178-83.
- Fornarif L. Ultrasonically guided fine needle biopsy of gastrointestinal organs in the canine. *Digestive Diseases*, 1992; 10(3):121-33.
- Hanson JA., Papageorges M., Girard E., Menard M. and Hebert P. Ultrasonographic appearance of splenic disease in 101 cats. *Vete Radi & Ultra*, 2018; 42(5): 441-5.
- Hughes JR., Szladovits B. and Drees R. Abdominal CT evaluation of the liver and spleen for staging mast cell tumors in dogs yields nonspecific results. *Vete Radio & Ultra*, 2019; 60(3): 306-15.
- Jeong SU., Aizan H., Song TJ., Seo DW., Kim SH., Park DH., Lee SS., Lee SK. and Kim MH. Forward-viewing endoscopic ultrasound-guided NOTES interventions: A study on peritoneoscopic potential. *World J of Gastro*, 2013; 19(41): 7160-67.
- Kelsey J., Balfour R., Szabo D. and Kass PH. Prognostic value of sternal lymphadenopathy on malignancy and survival in dogs undergoing splenectomy. *Vete and Comp Onco*, 2022; 20(1): 1-7.
- McInnes MD., Kielar AZ. and Macdonald DB. percutaneous image-guided biopsy of the spleen: systematic review and meta-analysis of the complication rate and diagnostic accuracy. *Radiology*, 2011; 260(3): 699-708.
- Oehlerth S., Dennler M., Rüefli E., Hauser B., Poirier V. and Siebeck N. Contrast harmonic imaging characterization of canine splenic lesions. *J vete inte med*, 2008; 22(5):1095-102.
- Pongchairerks P. Ultrasound – guided liver Biopsy: accuracy, safety and sonographic findings. *J Med Assoc Thai*, 2022; 76(11): 597-600.
- Rinaldi V., Crisi PE., Vignoli M., Pierini A., Terragni R., Cabibbo E., Boari A. and Finotello R. The Role of Fine Needle Aspiration of Liver and Spleen in the Staging of Low-Grade Canine Cutaneous Mast Cell Tumor. *Vete Sci*, 2022; 9(9): 473 1-7.
- Thamm D., Kamstock D., Sharp C., Johnson S., Mazzaferro E. and Herold L. Elevated serum thymidine kinase activity in canine splenic hemangiosarcoma. *Vete and comp onco*, 2012; 10(4):292-302.
- Turner RB., Liffman R., Woodward AP., Beck C., Courtman N. and Dandrieux JR. Assessment of the clinical usefulness of ultrasound-guided cytological specimens obtained from gastrointestinal lesions in dogs and cats. *J Small Animal Pra*, 2021; 62(2): 114-22.
- Vanstee LL., Boston SE., Singh A., Romanelli G., Rubio-Guzman A. and Scase TJ. Outcome and prognostic factors for canine splenic lymphoma treated by splenectomy (1995–2011). *Vete Surg*, 2015; 44(8):976-82.
- Watson AT., Penninck D., Knoll JS., Keating JH. and Sutherland JA. Safety and correlation of test results of combined ultrasound-guided fine-needle aspiration and needle core biopsy of the canine spleen. *Vete Radio & Ultra*, 2021; 52(3): 317-22.



## بررسی دقت، حساسیت و ویژگی بیوپسی اسپیراسیون سوزنی ظریف با کمک اولتراسونوگرافی در تشخیص توده‌های بدخیم طحال در سگ

هیلا عسکری<sup>۱</sup>، سیامک علیزاده<sup>۲\*</sup>

<sup>۱</sup>دانش آموخته دکترای حرفه‌ای دامپزشکی، دانشکده دامپزشکی، واحد ارومیه، دانشگاه آزاد اسلامی، ارومیه، ایران  
<sup>۲</sup>گروه علوم درمانگاهی، دانشکده دامپزشکی، واحد ارومیه، دانشگاه آزاد اسلامی، ارومیه، ایران

تاریخ دریافت: ۱۴۰۱/۱۲/۲۸ اصلاح نهایی: ۱۴۰۲/۰۱/۳۱ تاریخ پذیرش: ۱۴۰۲/۰۲/۰۷

### چکیده

**زمینه و هدف:** اسپیراسیون با سوزن ظریف با هدایت اولتراسوند به عنوان یک ابزار قابل اعتماد در تشخیص و دسته‌بندی ضایعات داخل شکمی پذیرفته شده است. هدف از انجام این تحقیق بررسی ارزش اسپیراسیون سوزنی ظریف به کمک اولتراسونوگرافی در تشخیص ضایعات موضعی طحال سگ‌ها بود.

**مواد و روش‌ها:** در این مطالعه ۲۰ قلاده سگ بیمار مشکوک به بدخیمی طحال (۱۲ قلاده نر و ۸ قلاده ماده) با میانگین سنی ۹/۳ سال مورد بررسی قرار گرفتند. سگ‌ها در وضعیت خوابیده به سمت راست بدن و همچنین به صورت شکمی پشتی تحت اولتراسونوگرافی قرار گرفتند. اسکن سگ‌ها به دو روش ساب کوستال و اینترکوستال انجام گرفت. نمونه‌برداری با کمک سوزن اسپینال شماره ۲۱ به طول ۱۰ سانتی‌متر (به طریق اسپیراسیون سوزنی ظریف) انجام شد. نتایج حاصل از اسپیراسیون با نتایج بیوپسی، جراحی و دیگر بررسی‌های کلینیکی و اطلاعات رادیولوژیک و اولتراسونوگرافی‌های بعدی در طی دوره درمان مقایسه و پس از جمع‌بندی و تشخیص نهایی، ارزش تشخیصی اسپیراسیون سوزنی ظریف با محاسبه دقت، ویژگی و حساسیت آن ارزیابی شد.

**یافته‌ها:** طبق نتایج به دست آمده در این مطالعه، دقت این روش ۹۲ درصد و حساسیت و ویژگی این تکنیک برای ضایعات بدخیم طحال به ترتیب ۹۳/۵ درصد و ۹۱ درصد بود. همچنین موارد منفی کاذب به دلیل کوچک بودن اندازه ضایعه (ضایعه با قطر کمتر از ۵ میلی‌متر) و عمقی بودن ضایعات (بیش از ۴/۵ سانتی‌متر فاصله از سطح) رخ داد، که این شرایط می‌تواند باعث ایجاد اشکالات تکنیکی در انجام اسپیراسیون شود.

**نتیجه‌گیری:** با توجه به دقت مناسب تشخیصی، سهولت دسترسی، ارزانی و عوارض قابل قبول توصیه ما انجام تکنیک اسپیراسیون سوزنی ظریف با راهنمایی اولتراسونوگرافی در تشخیص ضایعات بدخیم طحال می‌باشد.

**واژه‌های کلیدی:** اسپیراسیون سوزنی ظریف، توده‌های طحال، سگ، اولتراسونوگرافی

هیلا عسکری، سیامک علیزاده. بررسی دقت، حساسیت و ویژگی بیوپسی اسپیراسیون سوزنی ظریف با کمک اولتراسونوگرافی در تشخیص توده‌های بدخیم طحال در سگ. مجله طب دامپزشکی جایگزین. ۱۴۰۲؛ ۶(۱۶): ۹۴۶-۹۵۲.

\* نویسنده مسئول: گروه علوم درمانگاهی، دانشکده دامپزشکی، واحد ارومیه، دانشگاه آزاد اسلامی، ارومیه، ایران.