



# Comparative Ultrasonographic Measurements of Fetlock Joint Tendons and Ligaments Thickness in Front and Hind Limbs of Sound Dareh-Shori Horses

Roham Vali<sup>1\*</sup>, Arash Varnan<sup>2</sup>

<sup>1</sup>Assistant Professor, Department of Clinical Sciences, School of Veterinary Medicine, Kazerun Branch, Islamic Azad University, Kazerun, Iran

<sup>2</sup>D.V.M, Faculty of Veterinary Medicine, Kazerun Branch, Islamic Azad University, Kazerun, Iran

Received: 16/Apr/2023

Revised: 06/Jun/2023

Accepted: 21/Jun/2023

## Abstract

**Background and aim:** The tendons and ligaments in palmar/plantar aspect of fetlock joints of the horse are important in weight bearing and stay apparatus. These structures are always subject to damage caused by diseases and injuries. Ultrasound is one of the most useful methods for diagnosing soft tissue injuries including tendons and ligaments in horses. The aim of this study was to measure and to compares the thickness of fetlock joint tendons and ligaments in both front and hind limbs of sound Dareh-Shori horses.

**Materials and Methods:** This study consisted of 10 healthy Dareh-Shori horses that mean age and height of them were  $11.2 \pm 3.5$  years and  $151.6 \pm 10.2$  cm, respectively. After clipping and washing, the area between 4cm above the proximal sesamoid bones and distal to the level of the proximal sesamoid bones was divided into 1 level in sagittal and 3 levels in transverse view. An ultrasonography was performed with a linear transducer 12 MHZ Frequency on both front and hind limbs in full weight bearing. The thickness of tendons and ligaments such as superficial digital flexor tendon, deep digital flexor tendon and suspensory ligament were measured both in sagittal and transverse views. Echogenicity and fibrillary pattern of tendons and ligaments were assessed in longitudinal images.

**Results:** The greatest measured thickness of the digital flexor tendons and suspensory ligament was related to the deep digital flexor tendon while the Minimum thickness was related to the suspensory ligament in the left front joints. The results obtained from the present study did not show any significant changes between the right and left side of front and hind limbs of sound Dareh-Shori horses.

**Conclusion:** This study provides a thorough, in-depth knowledge on the normal ultrasound measurements of the tendon and ligaments thickness in the fetlock joints. Therefore, these values can reliably be used for diagnosis of fetlock joint soft tissue injuries.

**Keywords:** Thickness, Dareh-Shori horses, Fetlock joint, Tendons and Ligaments, Ultrasonography

**Cite this article as:** Roham Vali, Arash Varnan. Comparative Ultrasonographic measurements of fetlock joint tendons and ligaments thickness in front and hind limbs of sound Dareh-Shori horses. J Altern Vet Med. 2023; 6(18): 1052-1059.

## \* Corresponding Author

Assistant Professor, Department of Clinical Sciences, School of Veterinary Medicine, Kazerun Branch, Islamic Azad University, Kazerun, Iran.

E-mail: [rohamvali@gmail.com](mailto:rohamvali@gmail.com), Orcid: <https://orcid.org/0000-0003-1187-913X>



## Introduction

Dareh-Shori horse is one of the most well-known and oldest indigenous and original Iranian horse breeds, which are distributed in different areas of the country. Its main origin is fars province and its main breeders are Qashqai people. Over the years, the breed of Dareh-Shori horses has been well modified and has adapted to the nomadic lifestyle and migration that requires high physical strength, comfortable riding, and great endurance. Accordingly, for these reasons, horses are exposed to injuries caused by traumas and diseases related to the movement organs. Though this horse shows many similarities with the Arab horse, the differences in appearance, such as taller height, longer ears, angular rump and smaller hoof, distinguishes this horse from the Arab horse. Their identification documents are based on their phenotype and appearance characteristics (Vali & Borazgani, 2016). Since 1983, ultrasonography was used for the diagnosis and documentation of tendon/ligament injuries by assessment of echogenicity changes and measuring the dimensions of tendon/ligament (Rantanen *et al.*, 1983).

Tendons are made of dense connective tissue their purpose is to firmly attach a muscle to the bone. Tendons and ligaments do not have a good supply of blood, so they lack the source of oxygen and nutrients that would allow faster healing. Ligaments, generally, connect bone to bone. In some instances, they can also help to form an anchor for other structures in the body. Ligaments are also composed of dense connective tissue, but are more elastic than tendons. Ligaments are the structures that hold joints together and provide stability to a joint (Denoix, 1994; Mohammad *et al.*, 2008; Nazem & Sajjadian, 2015). Ultrasound has a wide extensive use in the diagnosis and measurement of equine soft tissues and musculoskeletal injuries and also in investigating the recovery procedures of flexor tendon/ligament injuries found in horses (Alzola *et al.*, 2018; Domingo *et al.*, 2017; Ge *et al.*, 2020; Hauser & Rantanen, 1983; Rantanen *et al.*, 1983; Reef, 1998). Ultrasonography can detect both echogenicity and changes of normal tendons and ligaments dimensions. On transverse ultrasound view normal tendons and ligaments show a homogenously echogenic appearance, on sagittal view they demonstrate a long linear fiber pattern. Injuries show up as increased

cross-sectional areas (size) with decreased echogenicity and a disrupted fiber pattern. Normal tendons and ligaments show a homogenously echogenic appearance. Enlargement of tendon/ligament is seen in inflammation, and an enlargement found over 20% ought to be recognized clinically as a crucial issue (Alzola *et al.*, 2018; Smith *et al.*, 1994; Digiovanni *et al.*, 2016). It is essential, therefore, to identify the related dimensions of the normal ultrasonographic tendon/ligament for an exact and precise diagnosis. Thickness of tendon/ ligament can be measured ultrasonographically both transverse and longitudinal. Ultrasonographic measurements of tendon/ligament dimensions is important in order to evaluate the healing process (Domingo *et al.*, 2017; Reef, 1998; Whitcomb, 2004).

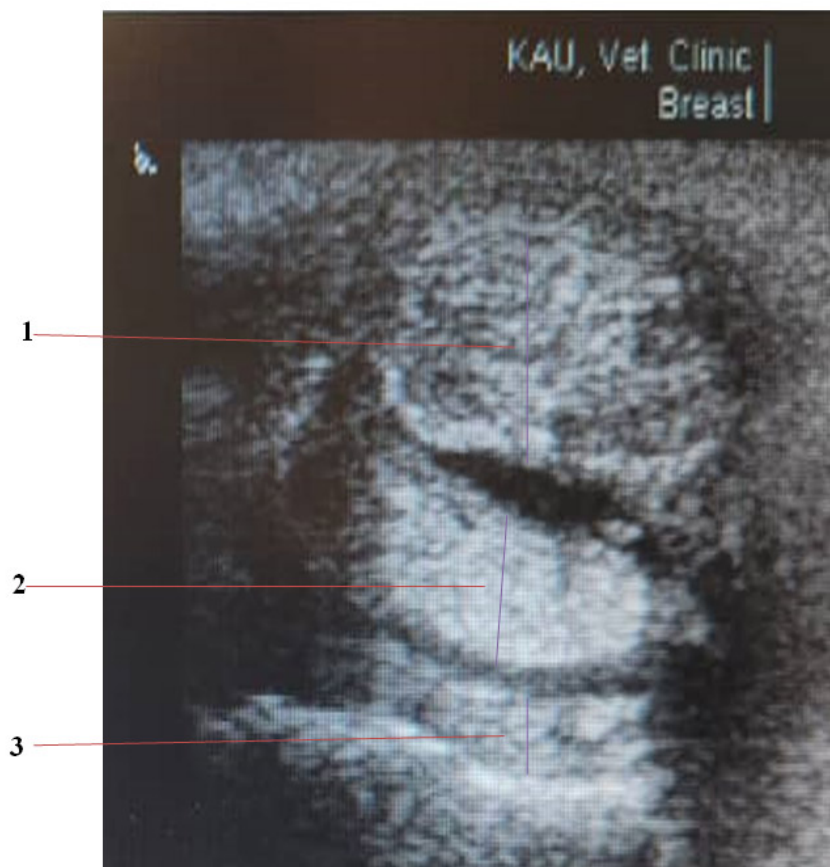
Extensive studies have measured the dimensions of tendon/ligament in different breeds of horses. In a study conducted on 10 healthy mare pure Persian Arabian horses in 2019, the thickness of the tendons and ligaments of the metacarpal area in the left and right limbs was measured and compared (Vosugh *et al.*, 2019). Furthermore, in some other studies carried out on Dutch Warmblood horses, the values as thickness, width, circumference and cross-sectional area values of superficial digital flexor tendon (SDFT), deep digital flexor tendon (DDFT), accessory ligament of the deep digital flexor tendon (AL) and also suspensory ligament (SL) were investigated and calculated in details (Van den Belt, 1995; Korosue *et al.*, 2015; Spinella *et al.*, 2018). The thickness and width of SDFT, DDFT, AL and SL in Thoroughbreds in the USA, Andalusian Anglo-Arabian and Pure Persian Arabian horses were measured in other studies (Genovese *et al.*, 1986; Cuesta *et al.*, 1995; Vosugh *et al.*, 2019). Based on the reported findings in the literature, the differences observed in tendon/ligament dimensions are attributed to the horses' breed, age, body weight, height, and their exercise program, as well as the exactness of ultrasound equipment (Van den Belt, 1995).

The purpose of this study is to investigate and measurement of tendons and ligaments thickness, in the fetlock joints of healthy Dareh-Shori horses in both longitudinal and transverse sections in order to provide normal values for use by veterinarians and other researchers.

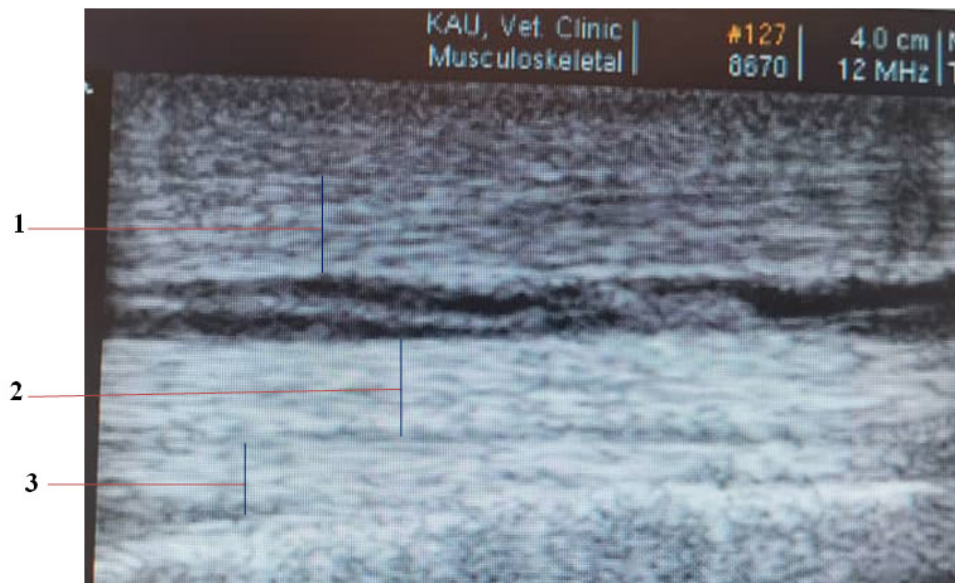
## Materials and Methods

Ten healthy Dareh-Shori horses with a mean age of  $11.2 \pm 3.5$  years and height of  $151.6 \pm 10.2$  cm were included in this study. Horses used in this study were transferred by their owner from one of the horse care centers to the faculty clinic and the ultrasound was performed in a quiet environment with physical restraint. The clinical examination of fetlock region was performed prior to the Ultrasonographic assessment in all horses. For this purpose, the tendons and ligaments of fetlock joints were palpated in a weight-bearing position and only the horses without any signs of lameness at walk or trot were selected for this study. Based on the proximal sesamoid bones, the palmar/plantar aspects of the fetlock region were divided into three zones. Zone1 located 4cm above the proximal sesamoid bones, Zone 2 at the level of the proximal sesamoid bones and Zone 3 distal to the level of the proximal sesamoid bones. After shaving

and washing, the ultrasonography of right and left fetlock regions in both front and hind limbs were performed by using a 12 MHz linear transducer (BK Medical minifocus). Ultrasound gel was used to increase contact. The area was examined by ultrasonography in both transverse and longitudinal scan in full weight bearing limbs. Measurements of tendon and ligament thickness in transvers and longitudinal views were determined by means of Electronic calipers on the ultrasound machine. Measurements of the dorsal to palmar/plantar dimensions in transverse scan were determined in 3 levels (Figures 1 and 2). For conducting statistical comparison of dimensions at each level in left and right limbs of horse, Paired sample T-test was used to examine and measure thickness of SDFT, DDFT and SL. A value of  $P < 0.05$  was considered to be significant.



**Figure 1.** Transverse ultrasonographic image of fetlock tendons and ligaments thickness in sound Dareh-Shori horse indicating parameters: 1. Superficial digital flexor tendon. 2. Deep digital flexor tendon. 3. Suspensory ligament.



**Figure 2.** Longitudinal ultrasonographic image of fetlock joint tendons and ligaments thickness in sound Dareh-Shori horse indicating parameters: 1. Superficial digital flexor tendon. 2. Deep digital flexor tendon. 3. Suspensory ligament.

## Results

The measurements related to morphometric values of the flexor tendons and suspensory ligament of 10 healthy Dareh-Shori horses are shown in Table 1 and 2. Thickness values of digital flexor tendons and suspensory ligament in longitudinal and transverse measurements from left and right limb in both fore and hind limbs are compared (Figures 1 and 2). In the left and right front limbs, the lowest thickness in the transverse measurement was related to the SDF tendon and SL ligament at levels 1 and 3 respectively, while the highest transverse thickness was related to the DDF tendon at level 1. The greatest thickness in the longitudinal measurement of both front and hind limbs was related to the deep flexor tendon in the right limb at level 1. In the hind limb, the maximum thickness of longitudinal measurement was related to the suspensory ligament in the right hind limb while

the lowest longitudinal thickness was related to the superficial digital flexor tendon in the left limb. The largest thickness in the transverse measurement was related to the DDF tendon in the right hind limb at level 1, while the lowest thickness was related to SDF tendon in the left hind limb. In left and right front limbs, maximum and minimum dorsopalmar thickness of the SDF in transverse section were seen at levels 3 and 1, respectively, while maximum and minimum dorsoplantar thickness of SDF in transverse section were related to level 2 and level 1 in left limb. The maximum thickness of DDF was seen in both right front and right hind at level 1. The maximum thickness of SL in front and hind limbs were seen in left front and right hind at levels 1 and 3. As the findings revealed, in this study, no significant differences were found between left and right side of front and hind limbs.

Parameter (mm)	Longitudinal			Transverse level 1			Transverse level 2			Transverse level 3		
	Left	Right	P Value	Left	Right	P Value	Left	Right	P Value	Left	Right	P Value
Superficial flexor tendon	4.4±0.01	3.9±0.06	0.45	2.7±0.03	3.6±0.02	0.38	4.4±0.1	4.5±0.3	0.83	4.3±0.1	4.5±0.2	0.93
Deep digital flexor tendon	5.8±0.03	5.4±0.08	0.82	5.8±0.08	6.1±0.08	0.86	3.9±0.09	4.5±0.05	0.89	4.3±0.04	5±0.1	0.40
Suspensory ligament	3.5±0.01	4.9±0.02	0.32	4.7±0.1	4.4±0.2	0.87	3.9±0.04	3.9±0.05	0.89	2.7±0.03	2.9±0.07	0.52

**Table 1.** Ultrasonographic measurements (Mean ± S.D) of fetlock joints tendons and ligaments dorsopalmar thickness in sound Dareh-Shori horses.



Parameter (mm)	Longitudinal			Transverse level 1			Transverse level 2			Transverse level 3		
	Left	Right	P Value	Left	Right	P Value	Left	Right	P Value	Left	Right	P Value
Superficial flexor tendon	3.8±0.05	4.4±0.1	0.35	3.1±0.1	3.7±0.1	0.46	4.9±0.2	4.7±0.2	0.89	3.5±0.9	3.7±0.2	0.86
Deep digital flexor tendon	3.9±0.01	4.4±0.04	0.73	5±0.1	6.1±0.08	0.65	4.5±0.2	4.5±0.05	0.85	4±0.1	5±0.1	0.25
Suspensory ligament	5.08±0.03	5.3±0.02	0.88	4±0.03	4.1±0.1	0.93	4.2±0.1	4.4±0.1	0.85	3.8±0.1	4.9±0.2	0.36

**Table 2.** Ultrasonographic measurements (Mean ± S.D) of fetlock joints tendons and ligaments dorsoplantar thickness in sound Dareh-Shori horses.

## Discussion

Although some studies have been reported on the measurement of tendons and ligaments of the fetlock joint region in different breeds of horses, there has not yet been published report on Dareh-Shori horses (Korosue *et al.*, 2015; Spinella *et al.*, 2018; Padaliya *et al.*, 2015; Coudry & Denoix, 2013; Reyes-Bossa *et al.*, 2020). The relevant measurements were carried out on 3 levels which were accordingly established by dividing the palmar/plantar fetlock area into 3 equal regions. They were starting from above the proximal sesamoid bone (level 1) to the region located just distal to the ergot and extended to mid proximal phalanx (level 3) as described previously (Mohammad *et al.*, 2008; Smith *et al.*, 1994; Van den Belt, 1995). Therefore, tendons/ligaments of horses were subsequently examined and measured at an equal ratio. Thickness, measurements of the SDFT, DDFT and SL in Arabian horse were determined by Celimli *et al.* (2004). Comparing the values obtained from Arabian and Dareh-Shori horses revealed that the thickness of SDFT of Arabian horse was close to values of the dareh-Shori in this study (Celimli *et al.*, 2004).

In another study conducted on Arabian horses, the thickness of the suspensory ligament in the palmar region of the front limbs was greater than that of the present study, while the values of the thickness of the deep digital flexor tendon were close to the values obtained in the present study (Vosugh *et al.*, 2019). In another study conducted on the pastern region in the front limbs of the horse, the thickness of the superficial and deep flexor tendons in the transverse view were reported to be 3 and 5.5 mm, respectively (Coudry & Denoix, 2013) While in the present study, maximum thickness values of superficial and deep flexor tendons were 4.5±0.3 and 6.1±0.08 mm respectively (Table1). In a study performed on 30 clinically healthy Colombian creole horses, the thickness of the superficial digital flexor tendon in the

left and right front limbs was reported to be 2.93±0.3 and 2.96±0.4 mm, respectively. The measured values for the deep flexor tendon in the mentioned study were 7.93±0.7 and 8.33±0.9 mm, While the values of the thickness of the suspensory ligament in the front limbs were 1.1±0.1 and 2.7±0.1mm respectively (Reyes-Bossa *et al.*, 2020). In the current study, the SDFT tendon thickness values were close to the values of the mentioned study, while the DDFT tendon thickness was greater than the values of the present study. On the other hand, the values of the thickness of the suspensory ligament in the present study were greater than the values mentioned in the above study (Table 1 and 2). Thickness measurements of the SDFT, DDFT and SL in Draught male horse determined by Mohammed *et al.* (2008), thickness of the SDFT in 3 levels and DDFT at level 3 were found the same values of Dareh-Shori horse in this study (Mohammad *et al.*, 2008).

Other measurements showed significantly greater values in comparison to the related ones for Dareh-Shori horses. In the current study, as the findings revealed, the measurements on thickness of flexor tendons in Andalusian Anglo-Arabian horses and Thoroughbreds were recognized to be higher in comparison to those found for Dareh-Shori horses (Genovese *et al.*, 1986; Cuesta *et al.*, 1995). Furthermore, the measures of thickness mean values which were examined in Dutch Warmblood horses and reported by Van den Belt (1995) were found to be greater than the consequent measurements for Dareh-Shori horses (Van den Belt, 1995). In summary, as the results showed, tendon and ligament measurements obtained from Dareh-Shori horses confirmed significant differences with those reported in some other studies for other breeds. The differences observed in this study are possibly attributed to horses' breed, age, body weight, height, and their training program and also it can be due to the accuracy of ultrasound equipment (Smith *et al.*,

1994; Van den Belt, 1995). In this study, as the findings revealed, smaller tendon/ligament measures found in Dareh-Shori horses can be explained by the fact that these horses are smaller at their withers, they have a lower bodyweight, and in comparison to other breeds they are slimmer and with finer build.

### Conclusion

In conclusion, the present study was an attempt to provide a thorough understanding and detailed information on normal ultrasound measurements of tendons and ligaments in the fetlock joints. Therefore, these values can reliably be used for diagnosis of fetlock soft tissue injury in this breed.

### Acknowledgment

The authors are grateful to the staff of the radiology department of the Faculty of Veterinary Medicine, Kazerun branch.

### Conflict of interest

There is no conflict of interest.

### References

- Alzola R., Easter C., Riggs CM., Gardner DS. and Freeman SL . Ultrasonographic-based predictive factors influencing successful return to racing after superficial digital flexor tendon injuries in flat racehorses: A retrospective cohort study in 469 Thoroughbred racehorses in Hong Kong. *Equine Vet J*, 2018; 50: 602-608.
- Celimli N., Seyrek-Intas D. and Kaya M. Morphometric measurements of flexor tendons and ligaments in Arabian horses by ultrasonographic examination and comparison with other breeds. *Equine Vet Educ*, 2004; 16: 81-85.
- Coudry V. and Denoix JM. Ultrasonographic examination of the palmar aspect of the pastern of the horse: Digital flexor tendons and digital sheath. *Equine vet Educ*, 2013; 25(4): 196- 203.
- Cuesta I., Riber C., Pinedo M., Gata JA. and Castejon F. Ultrasonographic measurement of metacarpal tendon and ligament structures in the horse. *Vet Radiol Ultrasound*, 1995; 36: 131-136.
- Denoix JM. Functional anatomy of tendons and ligaments in the distal limbs (manus and pes). *Vet Clin North Am Equine Pract*, 1994; 10(2): 273-322.
- Digiovanni DL., Rademacher N., Riggs LM., Baumruck RA. and Gaschen L. Dynamic sonography of the equine metacarpo (tarso) phalangeal digital flexor tendon sheath. *Vet Radiol Ultrasound*, 2016; 57(6): 621-629.
- Domingo RA., Riggs CM., Gardner DS. and Freeman SL. Ultrasonographic scoring system for superficial digital flexor tendon injuries in horses: intra-and inter-rater variability. *Vet Record*, 2017; 181(24): 655.
- Ge XJ., Zhang L., Xiang G., Hu Y.C. and Lun DX. Cross-Sectional Area Measurement Techniques of Soft Tissue: A Literature Review. *Orthop Surg*, 2020; 12(6): 1547-1566.
- Genovese RL., Rantanen NW., Hauser ML. and Simpson BS. Diagnostic ultrasound of equine limbs. *Vet Clin North Am Equine Pract*, 1986; 2: 145-226.
- Hauser ML. and Rantanen NW. Ultrasound appearance of the palmar metacarpal soft tissues of the horse. *J equine vet Sci*, 1983; 3: 19-22.
- Korosue K., Endo Y., Murase H., Ishimaru M., Nambo Y. and Sato F. The cross-sectional area changes in digital flexor tendons and suspensory ligament in foals by ultrasonographic examination. *Equine Vet J*, 2015; 47(5): 548-52.
- Mohammad MB., Gohary WS. and El-Glil, AIA. Ultrasonographic anatomy of the fetlock in draught horses. *Iran J Vet Surg*, 2008; 3(1): 9-18.
- Nazem MN. and Sajjadian SM. Anatomic assessment of tendons and ligaments of palmar surface of metacarpus in Anatoly donkey and its comparison with horse. *J Vet Res*, 2015; 70(4): 419-424.
- Padaliya NR., Ranpariya JJ., Kumar D., Javia CB. and Barvalia DR. Ultrasonographic assessment of the equine palmar tendons. *Vet World*, 2015; 8(2): 208-212.

- Rantanen NW., Genovese RL. and Gaines R. The use of diagnostic ultrasound to detect structural damage to the soft tissues of the extremities of horses. *J equine vet Sci*, 1983; 3: 134-135.
- Reef AB. Musculoskeletal. In: equine diagnostic ultrasound. 1nd ed., WB. Philadelphia, Saunders: 1998; P39-186.
- Reyes-Bossa B., Medina-Ríos H. and Cardona-Álvarez JA. Evaluation of morphometric measures of tendons and metacarpal ligaments by ultrasonography in Colombian creole horses. *Rev MVZ Cordoba*, 2020; 25(2): e1863.
- Smith RKW., Jones R. and Webbon PM. The cross-sectional areas of normal equine digital flexor tendons determined ultrasonographically. *Equine vet J*, 1994; 26: 460-465.
- Spinella G., Valentini S., Pitti L., Carrillo JM., Rubio M., Sopena J., et al. Ultrasonographic evaluation of cross-sectional area of tarsal ligaments in Standardbred Trotter Horses. *J Appl Anim Res*, 2018; 46(1): 915-919.
- Vali R. and Borazgani k. Some radiological measurements from the front hooves of normal Dareh-shori horses with relevance to hoof balance. *Iran J Vet Clin Sci*, 2016; 10(2): 83-89.
- Van den Belt AJM. Ultrasonography of equine flexor tendons and ligaments, Universiteit Utrecht, Fakulteit der Diergeneeskunde, 1995; P: 9-70. Ph.D thesis.
- Vosugh D., Nazem MN. and Lahuti S. Anatomy and ultrasonographic morphometric measurements of palmar metacarpal tendons and ligaments in pure Persian Arabian horses. *Anat Sci*, 2019; 16(2): 77-86.
- Whitcomb MB. Ultrasonographic evaluation of the metacarpus, metatarsus and pastern. *Clin Tech Equine Practice*, 2004; 3: 238-255.



# مقایسه ضخامت تاندون‌ها و لیگامان‌های ناحیه مفصل فتلاک اندام‌های حرکتی قدامی و خلفی اسب‌های سالم نژاد دره شوری با کمک اولتراسونوگرافی

رهام والی<sup>۱\*</sup>، آرش ورنان<sup>۲</sup>

<sup>۱</sup>استادیار، گروه علوم درمانگاهی، دانشکده دامپزشکی، واحد کازرون، دانشگاه آزاد اسلامی، کازرون، ایران  
<sup>۲</sup>دانش آموخته دکترای حرفه‌ای دامپزشکی، دانشکده دامپزشکی، واحد کازرون، دانشگاه آزاد اسلامی، کازرون، ایران

تاریخ دریافت: ۱۴۰۲/۰۱/۲۷ اصلاح نهایی: ۱۴۰۲/۰۳/۱۶ تاریخ پذیرش: ۱۴۰۲/۰۳/۳۱

## چکیده

**زمینه و هدف:** تاندون‌ها و لیگامان‌های ناحیه مفصل فتلاک در اندام‌های حرکتی قدامی و خلفی نقش مهمی در تحمل وزن و مکانیزم ایستایی دارند. این ساختارها همواره در معرض آسیب‌های ناشی از ضربه‌ها و بیماری‌های مربوط به اندام حرکتی هستند. اولتراسونوگرافی اولین انتخاب در تشخیص و تعیین میزان آسیب‌های وارد شده به تاندون‌ها و لیگامان‌ها با اندازه‌گیری ضخامت به عنوان یکی از شاخص‌های مهم در ارزیابی سلامت بافت‌های نرم هستند. هدف از مطالعه حاضر اندازه‌گیری و مقایسه ضخامت تاندون‌ها و لیگامان‌های ناحیه مفصل فتلاک اسب‌های سالم نژاد دره شوری در نماهای طولی و عرضی و ارائه مقادیر نرمال به منظور تشخیص آسیب‌های بافت نرم بود.

**مواد و روش‌ها:** این پژوهش روی ۱۰ راس اسب دره شوری سالم با میانگین سن  $11/2 \pm 3/5$  سال و ارتفاع  $151/6 \pm 10/2$  سانتی‌متر انجام گرفت. پس از کوتاه کردن و تراشیدن موها، ناحیه مفصل فتلاک در اندام‌های حرکتی قدامی و خلفی از ۴ سانتی‌متر بالای سزاموئید پروکزیمال تا ناحیه دیستال استخوان‌های سزاموئید به ۳ سطح در نمای عرضی و یک سطح در نمای طولی تقسیم شدند. سونوگرافی در حالت وزن‌گیری کامل در اندام‌های حرکتی قدامی و خلفی چپ و راست و با پروب خطی و فرکانس ۱۲ مگاهرتز انجام گرفت و شکل، جهت، ارتباط و اندازه‌گیری ضخامت ساختارهای تاندونی و لیگامانی در دو نمای طولی و عرضی انجام گرفت.

**یافته‌ها:** در اندام‌های حرکتی قدامی و خلفی کمترین ضخامت مربوط به لیگامان معلقه بود، در حالی که بیشترین ضخامت در اندام‌های حرکتی قدامی و خلفی مربوط به تاندون خم‌کننده عمقی بند انگشت گزارش شد، اختلاف معناداری بین نتایج حاصل از مقادیر به دست آمده از اندازه‌های ضخامت تاندون‌ها و لیگامان‌ها در اندام‌های حرکتی قدامی و خلفی چپ و راست اسب‌های دره شوری مشاهده نشد.

**نتیجه‌گیری:** این مطالعه دانش کامل و عمیقی را در مورد اندازه‌گیری‌های طبیعی ضخامت تاندون‌ها و لیگامان‌های ناحیه مفصل فتلاک اسب دره شوری با کمک اولتراسونوگرافی ارائه می‌دهد. بنابراین، این مقادیر را می‌توان با اطمینان برای تشخیص آسیب‌های بافت نرم مفصل فتلاک مورد استفاده قرار داد.

**واژه‌های کلیدی:** ضخامت، اسب دره شوری، مفصل فتلاک، تاندون‌ها و لیگامان‌ها، اولتراسونوگرافی

رهام والی، آرش ورنان. مقایسه ضخامت تاندون‌ها و لیگامان‌های ناحیه مفصل فتلاک اندام‌های حرکتی قدامی و خلفی اسب‌های سالم نژاد دره شوری با کمک اولتراسونوگرافی. مجله طب دامپزشکی جایگزین. ۱۴۰۲؛ ۶ (۱۸): ۱۰۵۲-۱۰۵۹.

\* نویسنده مسئول: استادیار، گروه علوم درمانگاهی، دانشکده دامپزشکی، واحد کازرون، دانشگاه آزاد اسلامی، کازرون، ایران.