



A Field Outbreak of *Dictyocaulus Filaria* in Sheep in the Northwest of Iran

Yaghoub Firouzvand*

Department of Pathobiology, Malekan Branch, Islamic Azad University, Malekan, Iran

Received: 04/Jul/2023

Revised: 23/Aug/2023

Accepted: 15/Sep/2023

Abstract

Background and aim: *Dictyocaulus filaria* is a threadlike worm that lives in the airways of the lungs in sheep and goats and can lead to pneumonia. In November 2022, a report of emaciation, anorexia and, weakness with frequent coughs in a flock of 145 sheep (including 30 males and 115 females) located in the city of Miyaneh (East Azarbaijan province) was reported to the private sector veterinary clinic.

Materials and Methods: During the necropsy of two dead sheep, and by cutting the air ducts and lung tissue, a large number of milky white worms were observed in the bloody secretions of the pulmonary ducts, and the smaller ducts became inflamed due to cellular infiltration and the ducts were filled with bloody exudate. The isolated worms were placed in 70% alcohol and were examined morphologically in the laboratory using an optical microscope.

Results: *Dictyocaulus filaria* worms were diagnosed. Male worms were 5.4-6.8 cm and females were 7.5-8.4 cm long. The uterus of the female worm was full of eggs containing larvae, approximately $95-110 \times 52-65 \mu$. Infected sheep were treated orally with levamisole at a dose of 7.5 mg/kg.

Conclusion: The present article is the first report of contamination and loss of sheep due to *Dictyocaulus filaria* in the field in East Azarbaijan province, Iran. Regular and strategic antiparasitic therapy should be performed using broad-spectrum antiparasitic drugs in small ruminants.

Keywords: *Dictyocaulus filaria*, Levamisole, Lungworm, sheep, Iran

Cite this article as: Yaghoub Firouzvand. A Field Outbreak of *Dictyocaulus Filaria* in Sheep in the Northwest of Iran. J Altern Vet Med. 2023; 6(18): 1097-1102.

* Corresponding Author

Department of Pathobiology, Malekan Branch, Islamic Azad University, Malekan, Iran.

E-mail: yaghuob_firoozi@yahoo.com, Orcid: <https://orcid.org/0000-0001-5620-7260>



Introduction

Lungworm infection of sheep and goats generally called verminous pneumonia or parasitic bronchitis, is caused by infection with *Dictyocaulus*, *Protostrongylus*, *Cystocaulus*, and *Muellerius* worms. The adult *Dictyocaulus filaria* lives in the airways of the lungs. The length of the male is 25-80 mm and the female worm is 43-112 mm. The life cycle of *Dictyocaulus filaria* is direct, with the first stage larva (L1) being excreted from the animal's feces and its transformation into the third stage larva (L3) in the pasture. Parasite larvae become infectious in humid conditions and at a temperature of 27 °C within a week. The host is infected by eating the third-stage larva during grazing, and then adult male and female worms settle in the airways of the lungs, and the female worm lays eggs containing larvae. First-stage larvae are released in the digestive tract and then excreted from the animal's feces. The conducted investigations show that the most common lungworm of sheep in Iran is *Dictyocaulus filaria* (Skerman *et al.*, 1970). Parasitic pneumonia outbreaks occur mostly in autumn and early winter seasons because larvae tend to have low temperatures (Panuska, 2006).

The severity of the infection depends on the extent of contamination of the pastures, the number of swallowed larvae, and also the host's safety conditions (Nashiruddullah *et al.*, 2007; Kebede *et al.*, 2014).

Infection is more in young animals or livestock with previous or underlying diseases. Worms in the airways increase the secretion of mucus and inflammation of the mucous layer, bronchitis and eosinophilic pneumonia, which is accompanied by blockage of the respiratory bronchioles and as a result, symptoms such as cough, dyspnea, fever, loss of appetite, poor growth rate, increased respiratory sounds, weakness, fatigue, grounding, emaciation are observed and can eventually lead to the death of the animal (Elsheikha & Khan, 2011; Holzhauer *et al.*, 2011; Forbes, 2018).

A harsh respiratory sound is heard on chest auscultation, and secondary bacterial infections may appear as a result of the infection (Sargison, 2016). In the necropsy, milky white long thread-like worms were observed in the airways with frothy blood secretions in the respiratory tracts, inflammation of the airways, and obstruction of the lung airways. This case report is the first report of deaths in sheep flocks due to *Dictyocaulus filaria* in East Azarbaijan province.

Case report

Clinical history

In November 2022, cases of thinness, anorexia and weakness along with frequent coughs were reported to a private veterinary clinic in a herd of 145 sheep (including 30 males and 115 females) located in Miyaneh city.

By referring to the place and taking a history, it was determined that two sheep died the other day due to severe weakness and disease, and 17 of the existing sheep had symptoms of excessive weight loss, cough, bilateral nasal secretions, lethargy, and loss of appetite. Five of the female sheep were stuck on the ground and their body temperature dropped below 37 °C and they were unable to stand up.

Necropsy

During the necropsy of two dead sheep, and after inspecting all the organs, the lung was inspected, and by cutting the air ducts and lung tissue, a large number of milky white worms were observed in the bloody secretions of the pulmonary ducts, the smaller ducts became inflamed due to cellular infiltration and, the ducts were filled with bloody exudate (Figure 1A).

The isolated worms were placed in 70% alcohol and were examined morphologically in the laboratory using an optical microscope, and *Dictyocaulus filaria* worms were diagnosed (Soulsby, 1982). Male worms were 4.5-6.8 cm and females were 4.8-7.5 cm long. At the anterior end, a small mouth with relatively small lips was observed. The posterior end of the female is narrow and, the male has a copulatory bursa with two brown spicules (Figure 1B and 2A). By inspecting other parts of the lung, no other worms were found. The uterus of the female worm was full of eggs containing larvae, approximately 95-110 × 52-65 μ (Figure 2B).

Then, the other herd animals were treated orally with levamisole (Rooyan darou, Iran; at a dose of 7.5 mg/kg), and the treatment was repeated two weeks later. After about four weeks, recovery was observed in the animals. It should be mentioned that during the treatment, one sheep died due to the severity of the symptoms.

Discussion

Dictyocaulus filaria is the most common lungworm of small ruminants in the world, and besides making the animal sick, it causes death and significant economic losses (Panuska, 2006; Borji *et al.*, 2012).

Severe cough, weak physical conditions, anorexia, grounding, and death were observed in sheep in the autumn season in East Azarbaijan province.

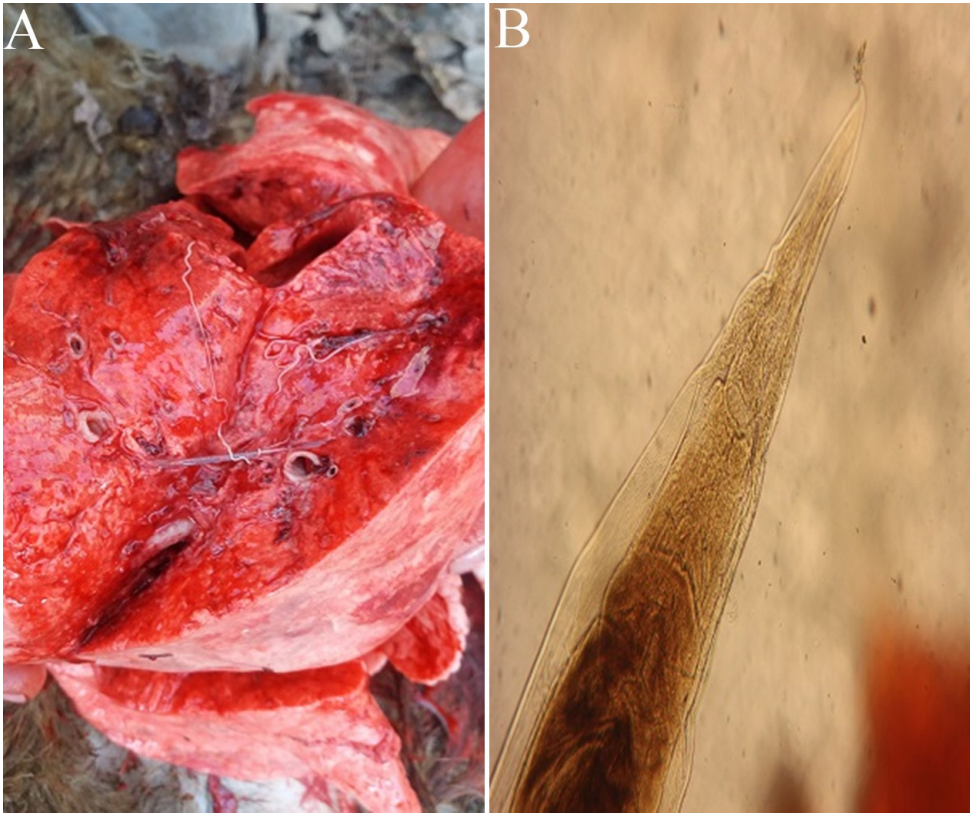


Figure 1. A) *Dictyocaulus filaria* in sheep lung. B) Posterior part of a female.

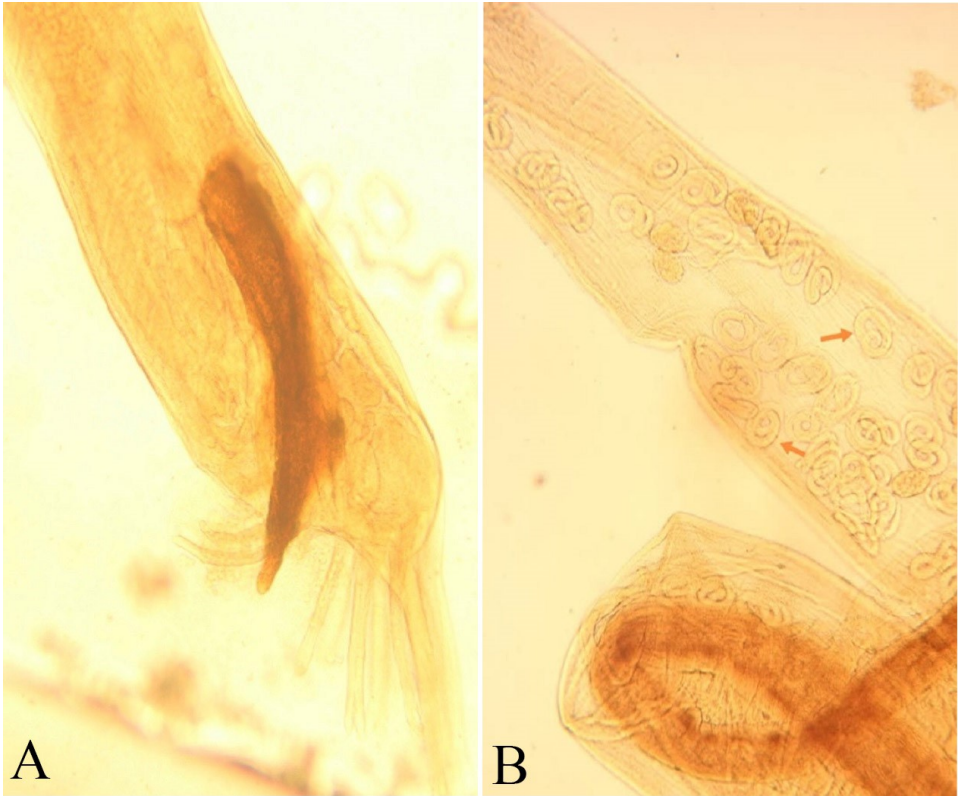


Figure 2. A) Posterior part of male worm with copulatory bursa and spicules. B) Eggs containing larvae inside the female worm are indicated by arrows.

The area is located at altitude of 1635 m above sea level and on the slopes of the mountain with a cold and moderate climate. The research conducted in Iran shows that the prevalence of *Dictyocaulus* is low in spring and summer and more in autumn and winter (Borji *et al.*, 2012; Hashemi *et al.*, 2011).

According to the Tewodros report (Tewodros, 2015), the infection is higher in autumn and winter. The symptoms of the disease vary from one animal to another, however, the symptoms in young animals are mostly associated with cough and emaciation. Sheep of any age can be infected with parasites. *Dictyocaulus filaria* infection leads to cough, weight loss, destruction of the respiratory system, and even death (Rather *et al.*, 2022). In the necropsy of the sheep, the lungs were congested and had bleeding spots. The bronchi and bronchioles were full of foamy blood exudate and contained many long white threadworms (Figure 1A).

The previous studies on the prevalence of lungworm infection in sheep and goats in Iran were based on slaughterhouse inspection, Baermann method and fecal flotation. The highest and lowest prevalence of *Dictyocaulus filaria* infection in sheep %56 and %0.1 has been reported respectively (Zafari *et al.*, 2022). In slaughterhouse surveys conducted in northwest Iran, the rate of *Dictyocaulus* infection varied from 0.1 to 34% (Nematollahi & Moghaddam, 2009). This difference can be due to differences in weather conditions, age and health status of the host, and other parasitic infections.

To the best of our knowledge, the present article is the first report of contamination and loss of sheep due to *Dictyocaulus filaria* in the field in Iran.

According to the researchers' report, special treatment measures should be taken to control and manage worm parasites (Asmare *et al.*, 2018). In the present study, levamisole drug was used to treat the infected herd and it showed that it is an effective drug for treatment. This drug can also be used to prevent the spread of disease.

Conclusion

Lungworm control is very important because L3 larvae can be spread by wind and even survive for long periods in the soil. Therefore, appropriate antiparasitic treatments at specific intervals can greatly reduce the contamination of pastures by L3 larvae (Ploeger, 2002).

Regular and strategic antiparasitic therapy should be performed using broad-spectrum antiparasitic drugs in small ruminants. The use of benzimidazole, levamisole, and ivermectin drugs in susceptible areas (high and humid), especially in young animals, and checking for lung parasites should be on the agenda.

Acknowledgments

Not applicable.

Conflict of interest statement

The authors declare no conflicts of interest.

Ethical approval

Not applicable.

References

- Asmare K., Sibhat B., Haile A., Sheferaw D., Aragaw K., Abera M. and Wieland B. Lungworm infection in small ruminants in Ethiopia: Systematic review and meta-analysis. *Vet Parasitol Reg Stud Reports*, 2018; 14: 63-70. doi:10.1016/j.vprsr.2018.08.003.
- Borji H., Azizzadeh M., Ebrahimi M. and Asadpour M. Study on small ruminant lungworms and associated risk factors in northeastern Iran. *Asian Pac J trop med*, 2012; 5(11): 853-856. doi:10.1016/S1995-7645(12)60159-X.
- Elsheikha HM. and Khan HA. *Essentials of veterinary parasitology*. 1st ed., UK: Nottingham, 2011.
- Forbes A. Lungworm in cattle: epidemiology, pathology and immunobiology. *Livesto*, 2018; 23(2): 59-66. doi:10.12968/live.2018.23.2.59.
- Hashemi S., Eslami A., Vosogh H. and Kakekhani S. Study on the prevalence of lungworm infection in the sheep and goat in Boroujerd slaughterhouse. *J clin res large anim*, 2011; 5(1): 61-65. (In Persian)
- Holzhauser M., Van Schaik G., Saatkamp HW. and Ploeger HW. Lungworm outbreaks in adult dairy cows: estimating economic losses and lessons to be learned. *Vet Rec*, 2011; 169(19): 494. doi:10.1136/vr.d4736
- Kebede S., Menkir S. and Desta M. On farm and Abattoir study of Lungworm infection of small ruminants in selected areas of Dale District, Southern Ethiopia. *Int J Curr Microbiol Appl Sci*, 2014; 3: 1139-52.
- Nashiruddullah N., Darzi MM., Shahardar RA., Kamil SA., Mir MS. and Mir M. Pathology of spontaneous *Dictyocaulus* sp. infection in hangul (*Cervus elaphus hanglu*), sheep and goat. *J Vet Parasitol*, 2007; 21(1): 37-40.
- Nematollahi A. and Moghaddam, GH. A survey an annual infestation of sheep with lungworms based on fecal test and slaughterhouse study in Tabriz. *J*

- Vet Res, 2009; 64(4). (In Persian with English abstract)
- Panuska C. Lungworms of ruminants. Veterinary Clinics: Food Anim Pract, 2006; 22(3): 583-93. doi:10.1016/j.cvfa.2006.06.002.
- Ploeger HW. *Dictyocaulus viviparus*: re-emerging or never been away? Trends parasitol, 2002; 18(8): 329-332. doi:10.1016/S1471-4922(02)02317-6.
- Rather MA., Hamadani A., Shanaz S., Shah R. and Nabi N. Outbreak of lungworm infection in yearling sheep-A case report. Bhartiya Krishi Anusandhan Patrika, 2022; 37(1): 94-96. doi:10.18805/BKAP439.
- Sargison N. The unpredictable epidemiology of *Dictyocaulus viviparus* lungworm infection of cattle. Vet Irel J, 2016; 6(7): 387-391.
- Skerman KD., Shahlapour AA., Eslami AH., Eliazian M. Anthelmintics for *Dictyocaulus filaria* in sheep. Arch. Razi Inst, 1970; 22: 177-185. doi: 10.22092/ARI.1970.108681.
- Soulsby EJLH. In Helminths, Arthropods and Protozoa of Domesticated Animals. 7th ed., London: Bailliere Tindall, 1982; pp: 262-268
- Tewodros AE. A review on: lungworm infection in small ruminants. World J Pharm life sci, 2015; 1(3): 149-159.
- Zafari S., Mohtasebi S., Sazmand A., Bahari A., Sargison ND. and Verocai GG. The Prevalence and Control of Lungworms of Pastoral Ruminants in Iran. Pathogens, 2022; 11(12): 1392. doi:10.3390/pathogens11121392.



شیوع صحرایی *Dictyocaulus filaria* در گوسفندان شمال غرب ایران

یعقوب فیروزی وند*

گروه پاتوبیولوژی، واحد ملکان، دانشگاه آزاد اسلامی، ملکان، ایران

تاریخ دریافت: ۱۴۰۲/۰۴/۱۳ اصلاح نهایی: ۱۴۰۲/۰۶/۰۱ تاریخ پذیرش: ۱۴۰۲/۰۶/۱۵

چکیده

زمینه و هدف: دیکتیوکولوس فیلاریا کرم نخی شکل است که در مجاری ریوی گوسفند و بز زندگی می کند و می تواند منجر به ذات الریه شود. در آبان ماه سال ۱۴۰۱ گزارشی از لاغری، بی اشتها و ضعف همراه با سرفه های مکرر در یک گله ۱۴۵ رأسی گوسفند (شامل ۳۰ گوسفند نر و ۱۱۵ گوسفند ماده) واقع در شهرستان میانه (استان آذربایجان شرقی) به کلینیک دامپزشکی بخش خصوصی داده شد.

مواد و روش ها: در حین کالبد گشایی دو رأس از گوسفندان تلف شده و با انجام برش بر روی مجاری هوایی و بافت ریه، تعداد زیادی کرم به رنگ سفید شیری، در بین ترشحات خون آلود مجاری ریوی مشاهده گردید و مجاری کوچکتر به دلیل ارتشاح سلولی، ملتهب و پر از ترشحات خون آلود بودند. کرمهای جدا شده در الکل ۷۰ درصد قرار داده شدند و در آزمایشگاه، از نظر ریخت شناسی بوسیله میکروسکوپ نوری مورد مطالعه قرار گرفتند.

یافته ها: کرمهای جدا شده از نظر مورفولوژی، دیکتیوکولوس فیلاریا تشخیص داده شدند. طول کرمهای نر ۸/۶-۴/۵ سانتی متر و طول کرمهای ماده ۴/۸-۵/۷ سانتی متر بود. رحم کرم ماده پر از تخمهای حاوی نوزاد تقریباً به اندازه ۱۱۰-۹۹ میکرون در ۶۵-۵۲ میکرون بودند. گوسفندان آلوده با استفاده از داروی لوامیزول با دوز ۵/۷ میلی گرم به ازای هر کیلوگرم وزن دام و بصورت خوراکی مورد درمان قرار گرفتند.

نتیجه گیری: بررسی حاضر، اولین گزارش آلودگی و تلفات گوسفندان در اثر دیکتیوکولوس فیلاریا در استان آذربایجان شرقی می باشد. درمانهای ضد انگلی منظم و استراتژیک باید با استفاده از داروهای ضد انگلی وسیع الطیف در نشخوارکنندگان کوچک انجام شود.

واژه های کلیدی: دیکتیوکولوس فیلاریا، لوامیزول، کرم ریه، گوسفند، ایران

یعقوب فیروزی وند. شیوع صحرایی *Dictyocaulus filaria* در گوسفندان شمال غرب ایران. مجله طب دامپزشکی جایگزین. ۱۴۰۲؛ ۶ (۱۸): ۱۰۹۷-۱۱۰۲.

* نویسنده مسئول: گروه پاتوبیولوژی، واحد ملکان، دانشگاه آزاد اسلامی، ملکان، ایران.