



Comparative Evaluation of Silver and Zinc Oxide Nanoparticles in Healing of *Staphylococcus aureus*-Infected Wounds: A Preclinical Study

Shabnam Golbouy Daghdari^{1*}, Ali Asghar Tehrani²

¹Department of Microbiology, Faculty of Veterinary Medicine, Urmia University, Urmia, Iran

²Department of Pathobiology, Faculty of Veterinary Medicine, Urmia University, Urmia, Iran

Received: 20/Jul/2024

Revised: 10/Sep/2024

Accepted: 20/Oct/2024

Abstract

Background and Aim: Skin and wound infections commonly result from *Staphylococcus aureus*, necessitating alternative therapeutic approaches due to escalating antibiotic resistance. This study aims to conduct a thorough comparative analysis, evaluating the distinct impacts of Zinc Oxide nanoparticles (ZnONPs) and Silver nanoparticles (AgNPs), both within the 20 to 30 nm range, on the healing process of infected wounds.

Materials and Methods: Forty-eight male mice were randomly divided into four groups. Full-thickness skin wounds were induced on the animals' backs under anesthesia, followed by inoculation with a bacterial suspension (10^8 CFU/ml) of *S. aureus*. Topical treatments, including 40 μ l of ZnONPs, 40 μ l of AgNPs, Tetracycline, and normal saline, were applied to the wound beds. Macroscopic monitoring and histopathological examinations on days 7, 14, and 21 assessed re-epithelialization, inflammation, and angiogenesis. Antibacterial effectiveness was determined by finding the MIC, and SPSS software was used for statistical analysis.

Results: The MIC results reveal a significant contrast in antibacterial effectiveness, with AgNPs at 3.91 μ g/ml and ZnONPs at 125 μ g/ml, indicating AgNPs' superior potency at lower concentrations. In the macroscopic examination of wounds, both AgNPs and ZnONPs exhibited a substantial acceleration in wound closure, significantly outperforming the negative control group ($p < 0.05$). However, a nuanced distinction emerged in histopathological analysis; while both nanoparticles similarly contributed to reducing inflammation, ZnONPs displayed superior effects on reepithelialization and neovascularization compared to other groups, all without inducing cytotoxicity.

Conclusion: The study concludes that AgNPs are potent antibacterial agents, while ZnONPs contribute significantly to advanced wound healing. The comparative analysis provides valuable insights for tailored wound management approaches, considering the distinctive strengths of each nanoparticle. Future research and clinical applications stand to benefit from optimizing therapeutic outcomes across diverse wound healing scenarios.

Keywords: *Staphylococcus aureus*, Zinc oxide nanoparticles, Silver nanoparticles, Wound healing

Cite this article as: Shabnam Golbouy Daghdari, Ali Asghar Tehrani. Comparative evaluation of silver and zinc oxide nanoparticles in healing of *staphylococcus aureus*-infected wounds: a preclinical study. J Altern Vet Med. 2024; 7(22): 1321-1332.

Introduction

Staphylococcus aureus is a leading pathogen responsible for skin and soft tissue infections, particularly in surgical wounds and chronic ulcers. Its presence often delays wound healing due to bacterial contamination (Linz *et al.*, 2023; Serra *et al.*, 2015). The increasing incidence of *S. aureus*-associated infections, along with its growing resistance to conventional antibiotics, underscores the urgent need for innovative therapeutic strategies (Foster, 2017).

Metals such as silver, gold, and zinc have long been recognized for their antimicrobial properties. Advances in nanotechnology have transformed these metals into nanoparticles (ranging from 1 to 100 nm), significantly enhancing their antibacterial potential. Among these, silver nanoparticles (AgNPs) have garnered significant attention due to their remarkable properties, including efficacy against multidrug-resistant microorganisms (Ahmadi & Adibhesami, 2017). With minimal toxicity and broad-spectrum antibacterial activity, AgNPs have found extensive applications in medicine, particularly in the management of infections and the promotion of wound healing (Mohanty *et al.*, 2012).

Nanoparticles with antimicrobial properties show potential in combating multidrug-resistant *S. aureus* infections (Martinez-Gutierrez *et al.*, 2010; Raghupathi *et al.*, 2011). Zinc oxide (ZnO) has attracted attention due to its safety and proven antibacterial, anti-inflammatory, and wound-healing properties (Pati *et al.*, 2014). Zinc oxide nanoparticles (ZnONPs), especially those measuring 20–30 nm, exhibit stronger antibacterial effects against a wide range of bacteria, including *S. aureus* (Pati *et al.*, 2014; Raghupathi *et al.*, 2011; Vendrame *et al.*, 2024).

Although *in vitro* studies on the antimicrobial properties of nanoparticles are rapidly increasing, there is a clear need for *in vivo* research to evaluate their therapeutic potential (Sirelkhatim *et al.*, 2015). This study aims to compare the effectiveness of zinc oxide nanoparticles (ZnONPs) and silver nanoparticles (AgNPs), sized between 20 and 30 nm, in promoting the healing of infected wounds. Building on previous findings that demonstrate the effectiveness of nanoscale materials in treating *S. aureus*-infected wounds in mice (Daghdari *et al.*, 2017), our research explores the therapeutic

capabilities of these nanoparticles in a murine wound infection model.

Materials and Methods

Bacterial suspensions

S. aureus (ATCC 25923 - MAST Company, UK), ZnONPs and AgNPs (10 – 30 nm) (US Research Nanomaterials, Inc., USA) were procured from the Faculty of Veterinary Medicine, Urmia University and NanoSany Corporation, Mashhad, Iran respectively. Bacterial suspensions were prepared by culturing *S. aureus* in Mueller Hinton Broth (incubated for 18 h at 37°C), followed by centrifugation at 10,000 g for 10 min at 4°C. The resulting pellet was washed with phosphate-buffered saline (PBS), dissolved in PBS, and diluted in normal saline to achieve a 0.5 McFarland density (10^8 CFU/ml) (Ahmadi & Adibhesami, 2017).

Antibacterial test

The minimum inhibitory concentration (MIC) was determined using the broth dilution method. *S. aureus* (10^8 CFU) was inoculated in Mueller-Hinton broth containing varying concentrations (500, 250, 125, 62.5, 31.25, 15.62, 7.81, 3.91 and 1.95 µl/ml) of ZnONPs and AgNPs separately. The MIC concentration was selected for subsequent experiments because it represents the lowest concentration capable of effectively inhibiting bacterial growth, minimizing the risk of cytotoxic effects while maintaining antibacterial efficacy. Incubation occurred overnight in a shaker at 37°C (Mendes *et al.*, 2022).

Animals

Forty-eight male albino mice (20-30 g) were divided into four groups ($n=12$). During a 2-week acclimatization period in standard single cages with controlled light-dark cycles at room temperature, mice were handled in accordance with ethical guidelines for animal care and use. The study followed the protocols outlined by the Medical Ethics Committee for the Care and Use of Laboratory Animals at Urmia University. Mice received standard plate diet and water *ad libitum* (Baumans & Van Loo, 2013).

Anesthesia and wounding

After intraperitoneal administration of ketamine (100 mg/kg) and xylazine (5 mg/kg), dorsal hair was

shaved, and wounds were created using a punch biopsy tool (3 mm) (Revolving punch pliers, Dimeda, Württemberg, Germany) (Figure 1) (Mihu *et al.*, 2010; Ziv-Polat *et al.*, 2010).

Infected wound model

Following wounding, 10 μ l of bacterial suspension (10^8 CFU of *S. aureus*) was inoculated on each wound. Treatments included 40 μ l of normal saline (negative control), 40 μ l of standard drug (Tetracycline) (8 mg/kg), 40 μ l of AgNPs (dose specified in MIC) and 40 μ l of ZnONPs (dose specified in MIC) for the positive and treatment groups, respectively. Wounds were left uncovered, and healing progress was monitored using a digital camera (Figure 1). Mice were euthanized three, seven, and 21 days post-infection, and biopsies were collected, fixed in 10% formalin, embedded in paraffin, and stained with Hematoxylin and Eosin (H&E). Histopathological parameters, including re-epithelialization, inflammation, and neovascularization, were evaluated using a light microscope (Ahmadi &

Adibhesami, 2017; Jiang *et al.*, 2012). In the end, Histopathological parameters, including inflammation and endothelial cells and epithelialization, were assessed for each mice by randomly selecting five fields (1 mm^2) on each slide, using the scoring method developed by Abramov *et al.* (2007), (Abramov *et al.*, 2007) and the results were presented as the mean \pm standard deviation (SD).

Results

Minimum inhibitory concentration

The MIC for ZnONPs against *S. aureus* was determined to be 125 μ g/ml. In contrast, the minimum inhibitory growth concentration for AgNPs was identified at 3.91 μ g/ml.

Macroscopic evaluation

The majority of infected wounds exhibited substantial healing within two weeks. Wounds displayed no signs of pus, necrosis, or inflammation during the healing process (Figure 1).

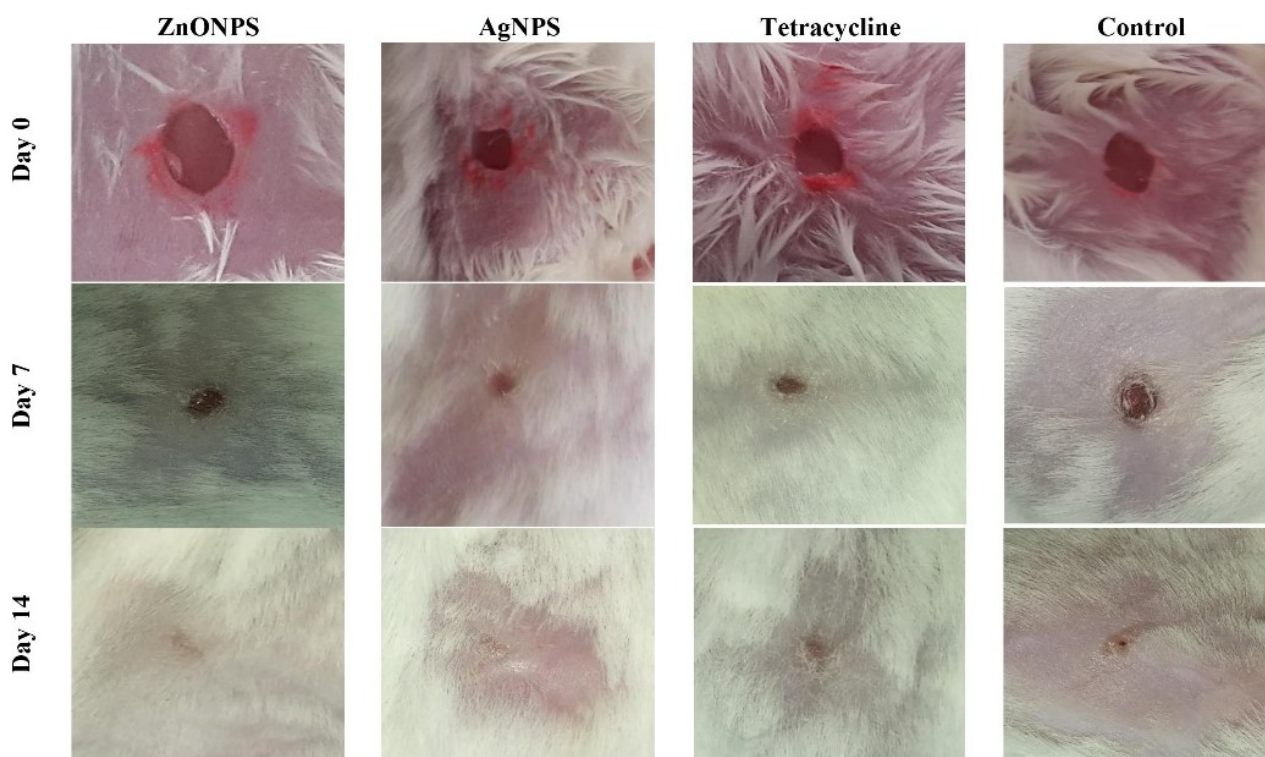


Figure 1. Wound photographs in ZnONPs, Tetracycline, and Negative Control on Days 0, 7, and 14.

Wound area assessment

The effectiveness of ZnONPs and AgNPs in fostering wound healing was systematically evaluated by measuring wound areas (Table 1). Across all groups, a consistent reduction in wound area occurred from day zero to day 21. Complete wound closure was evident on days 14 and 21 (Figure 1). One-Way Analysis of Variance (ANOVA) highlighted significant differences among treatment groups ($p < 0.05$). Notably, on day 7 post-treatment, a significant difference in wound area size was

observed between ZnONPs and AgNPs groups and the negative control ($p = 0.031$ and $p = 0.028$, respectively). The tetracycline group showed no significant difference compared to the negative control and nanoparticles treatment groups. Additionally, no significant difference was observed between the AgNPs and ZnONPs treatment groups ($p > 0.05$). This concise analysis underscores the impactful role of nanoparticles in accelerating wound healing.

Groups	Mean Wound Area \pm SEM (mm^2) on Days 0, 7, and 14 (%Wound Contraction)		
	0	7	14
Negative Control		2.46 ± 0.42 (%67)	0
Tetracycline	Average wound surface area: 7.06	1.74 ± 0.43 (%78)	0
AgNPs		* 1.01 ± 0.21 (%84.75)	0
ZnONPs		* 1.04 ± 0.10 (%85)	0

Table 1. The Impact of Topical Application of ZnONPs and AgNPs, and Tetracycline on the Skin Wound Area in Mice.

*Significant difference compared to the negative control group ($p < 0.05$).

Re-epithelization

Our findings show that ZnONPs effectively enhance re-epithelization. Histopathological studies revealed notable re-epithelization in ZnONP-treated wounds, with a significant increase in epithelial thickness on day 7, suggesting enhanced cell proliferation. Despite a subsequent decrease on days 14 and 21, the epithelial size in *S. aureus*-infected wounds treated with ZnONPs and AgNPs remained significantly larger than in control wounds ($p < 0.05$).

The ZnONPs group demonstrated a higher percentage reduction in epithelial thickness (75.8% from day 7 to 21) compared to the control group (72.7%), with a faster return to normalcy (Graph 1 and Figure 2).

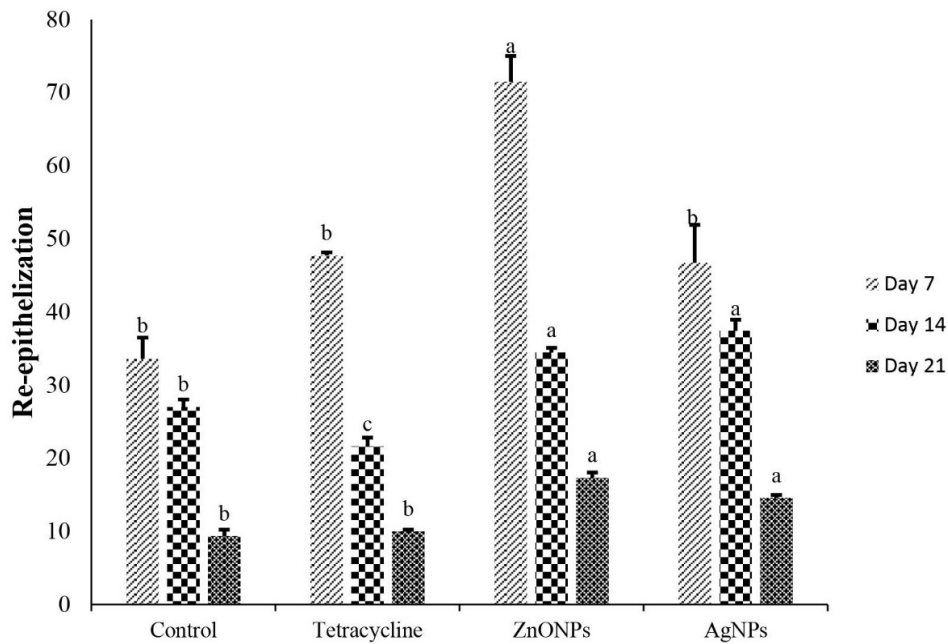
Inflammation

Pathological analyses showed dense neutrophil-rich infiltrates in untreated or Tetracycline-treated *S. aureus* wounds. Notably, on day 7, ZnONPs and

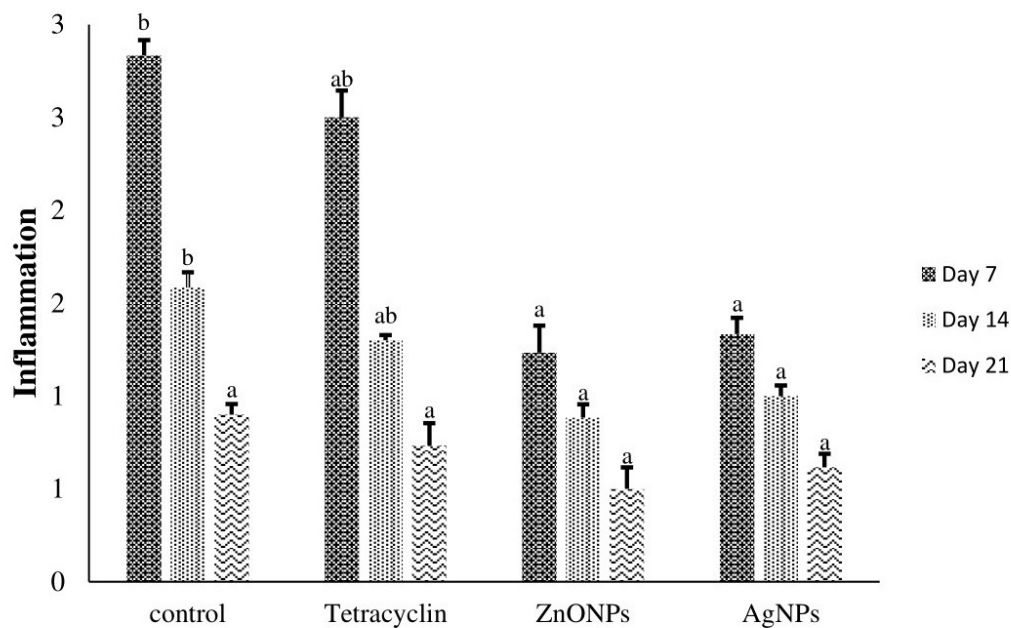
AgNPs displayed significantly fewer inflammatory responses. By day 14 post-infection, all groups exhibited a reduction in inflammatory cells, with ZnONPs- and AgNPs-treated wounds showing significantly lower levels than untreated tissues ($p < 0.05$). On day 21, while the ZnONPs and AgNPs groups showed a reduction in inflammatory cells compared to controls, the difference was not statistically significant (Graph 2 and Figure 2 and 3).

Angiogenesis

Histological analyses showed that ZnONPs significantly increased neovascularization on day 7 compared to the control group, but there was no significant difference with the AgNPs group. By day 14, wounds treated with ZnONPs had significantly more blood vessels than untreated wounds ($p < 0.05$). However, by day 21, the difference in blood vessel numbers was not statistically significant in the ZnONPs-treated group (Graph 3 and Figure 2 and 3).



Graph 1. Graph illustrating the average comparison of epithelial size (μm) in wounds. The average of the results for measurements decreased from day 7 to 21. Columns sharing similar letters are not statistically significant ($p>0.05$). On each day, columns sharing the same letters are not statistically significantly different ($p>0.05$), while columns with different letters indicate statistically significant differences ($p<0.05$).



Graph 2. Comparison diagram of inflammatory cells in the negative control, Tetracycline, AgNPs, and ZnONPs on Days 7, 14, and 21. On each day, columns sharing the same letters are not statistically significantly different ($p>0.05$), while columns with different letters indicate statistically significant differences ($p<0.05$).

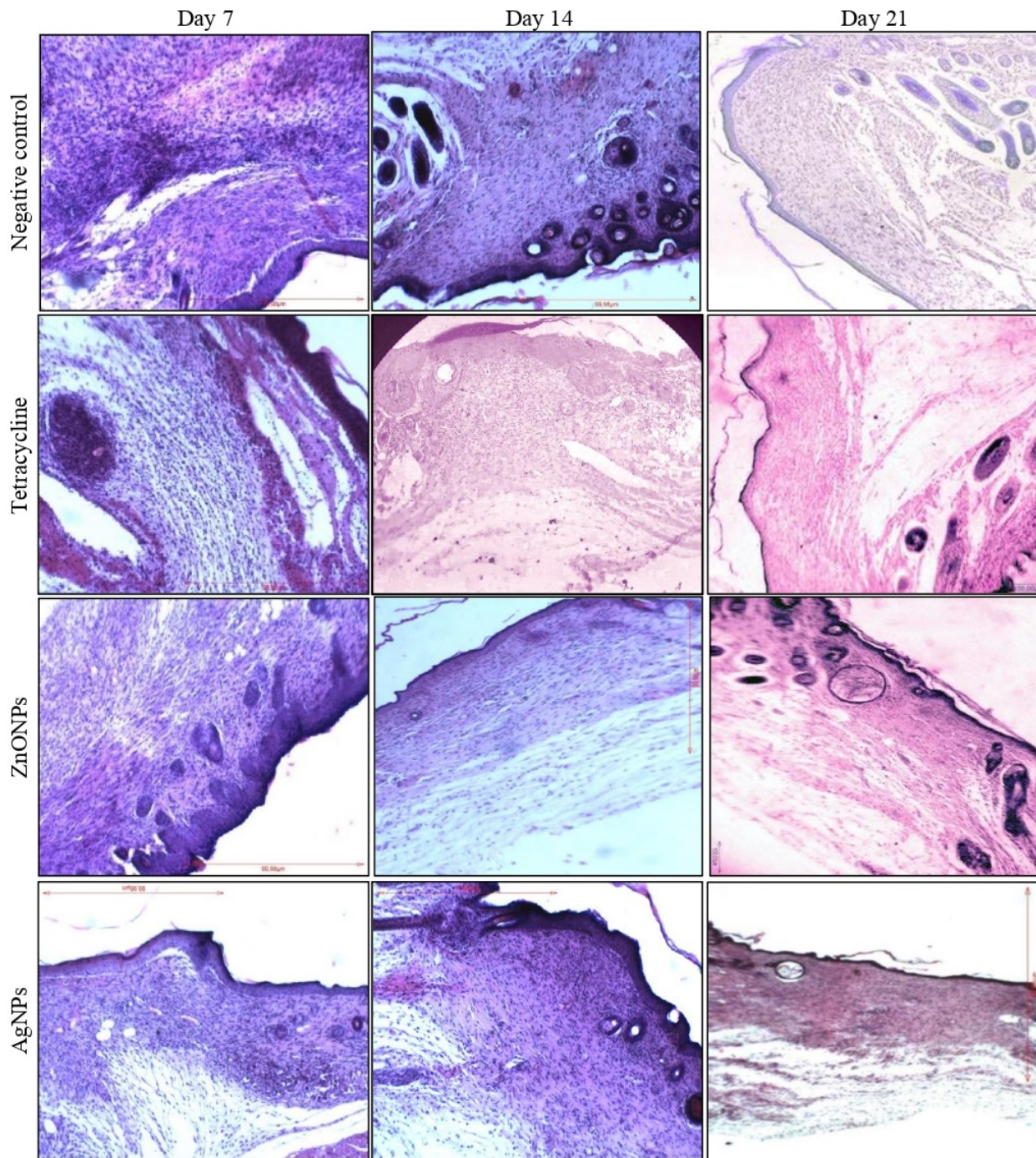
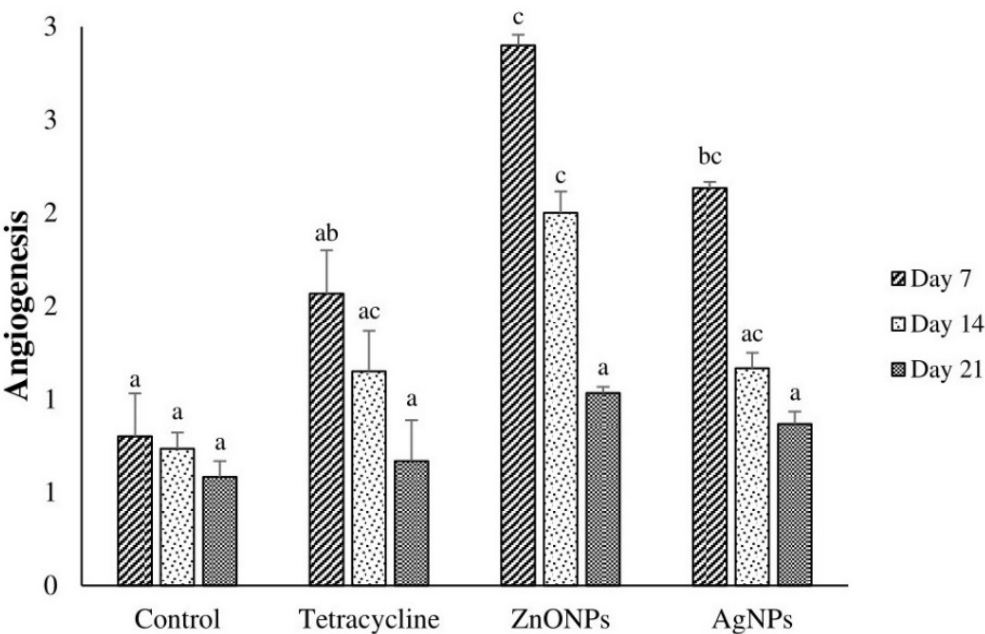


Figure 2. Histological progression of wound healing in mice across experimental groups at Days 7, 14, and 21 (H&E staining, $\times 100$). **Negative Control Group**, Day 7: Irregular granulation tissue with abundant inflammatory cells and formed epithelial tissue, Day 14: Reduced cell count, more regular tissue, Day 21: Regular scar tissue formation with decreased cells. **Tetracycline Group**: Day 7: Epithelium formation with abundant inflammatory cells and immature fibroblasts in granulation tissue, Day 14: Irregular granulation tissue and cells persist, Day 21: Gradual reduction in cell count, emergence of regular scar tissue. **ZnONPs Treatment Group**: Day 7: Presence of inflammatory cells, fibroblasts, and fully formed epithelium, Day 14: Regular granulation tissue with reduced inflammatory cells, Day 21: Formation of regular scar tissue with a decreased number of cells compared to the negative control group. **AgNPs Treatment Group**: Epithelium formation, presence of inflammatory cells and fibroblasts, Day 14: Regular granulation tissue with reduced inflammatory cells, Day 21: Formation of regular scar tissue.



Graph 3. Comparison of angiogenesis in negative control group, Tetracycline, and ZnONPs on Days 7, 14, and 21. On each day, columns sharing the same letters are not statistically significantly different ($p>0.05$), while columns with different letters indicate statistically significant differences ($p<0.05$).

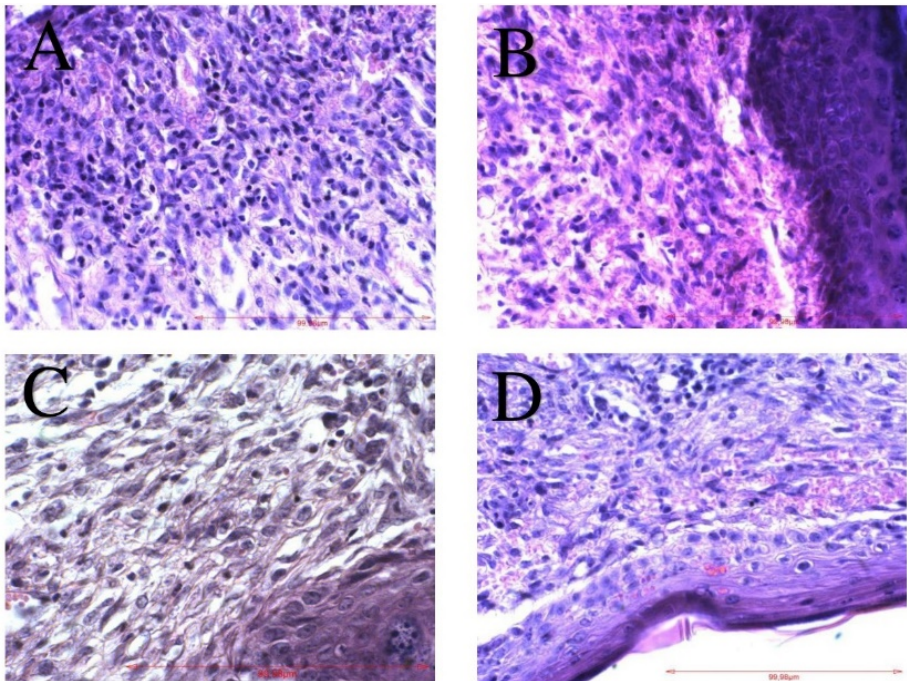


Figure 3. Histological morphology of healed wounds in animals from the four experimental groups on day 7 (H&E staining, $\times 400$). **A:** In the negative control group, the histological section reveals irregular formation of granulation tissue, accompanied by an abundance of inflammatory cells, and the presence of some observed blood vessels. **B:** In the Tetracycline group, fewer inflammatory cells are present compared to the negative control group, and new blood vessel can be seen. **C:** The histological section of the ZnONPs treated group demonstrates a high number of newly formed blood vessels and notably reduced inflammatory cells compared to the other two control groups. **D:** In the AgNPs group, there is a lower presence of inflammatory cells in comparison to the negative control group, and there is observable formation of new blood vessels.

Discussion

S. aureus has emerged as a prominent causative agent of skin and soft tissue infections, particularly in surgical and chronic wound settings (Linz *et al.*, 2023; Serra *et al.*, 2015). The surge in drug-resistant strains prompts a need for innovative therapies beyond conventional antibiotics (Foster, 2017). Exploring the microbial actions of nanoparticles, particularly Silver, Gold, and Zinc oxide, highlights their significant antibacterial potential (Hartemann *et al.*, 2015). While *in vitro* studies provide insights into nanoparticle antimicrobial efficacy, *in vivo* research evaluates practical applications. The dominance of laboratory studies necessitates extensive investigations to validate nanoparticle antimicrobial effects in clinical scenarios (Sirelkhatim *et al.*, 2015).

AgNPs, in particular, are widely used in wound management due to their exceptional antibacterial properties (Ahmadi & Adibhesami, 2017). Despite well-documented antibacterial effects of Zinc Oxide, their role in wound closure lacks adequate exploration (Pati *et al.*, 2014).

This study specifically explores the comparative impact of AgNPs and ZnONPs on treating infected wounds. The nuanced comparison between AgNPs and ZnONPs provides valuable insights into their differential effectiveness, laying the groundwork for future therapeutic advancements.

Compelling findings from prior research robustly affirm the efficacy of these particles in combating *S. aureus* infections (Etheridge *et al.*, 2013; Sirelkhatim *et al.*, 2015). The results regarding drug sensitivity in the present study revealed that AgNPs, compared to ZnONPs, were more successful in inhibiting the growth of *S. aureus* at lower concentrations. This indicates a higher efficacy of AgNPs compared to ZnONPs. In 2016, Panáček *et al.* investigated the antibacterial properties of AgNPs against *S. aureus*, revealing MIC of approximately 6.71 µg/ml with a particle size of 21 nanometers, aligning closely with our study (Panáček *et al.*, 2006). Following Panáček's approach, Martinez-Castanon *et al.* conducted a study in 2014, reporting a slightly different MIC for AgNPs at 16.67 µg/ml. Discrepancies in MIC values may be attributed to variations in the size of AgNPs (Martinez-Gutierrez *et al.*, 2010). Additionally, in 2022, Mendes *et al.* explored the impact of ZnONPs on *S. aureus*, suggesting their potential bacteriostatic effects (Mendes *et al.*, 2008).

The wound characteristics, including area, diameter, and macroscopic appearance, showed improvement in mice. On the seventh day, the treatment groups with ZnONPs and AgNPs exhibited a significant reduction in wound area compared to the negative control group. Although these values were lower than the tetracycline group, the difference was not statistically significant. Various studies have highlighted the ability of AgNPs to reduce fibroblast production time, leading to faster wound contraction and closure (Kwan *et al.*, 2011; Bold *et al.*, 2022).

Furthermore, Pati *et al.* demonstrated the efficacy of ZnONPs in enhancing the improvement of skin infection (Pati *et al.*, 2014). Chhabra *et al.*'s study in 2015, on rats, further supported the role of ZnONPs in accelerating wound contraction and closure (Chhabra *et al.*, 2016). These combined findings underscore the significant contribution of both nanoparticles to the complex mechanisms involved in wound healing.

The results of our study highlight the superior efficacy of ZnONPs in promoting re-epithelization, especially on the seventh day, surpassing the impact of AgNPs. However, as wound healing progresses from days 7 to 21, a noticeable reduction in epithelium thickness occurs, approaching levels close to that of the natural epithelium. This trend is more pronounced in ZnONPs group exhibiting a greater rate of return to natural epithelium size compared to other groups. As a results of Aloe *et al.* study in 2016, ZnONPs were found to change the rate of re-epithelization and improved wound healing *in vitro* (Aloe *et al.*, 2016), which confirms the findings of our study.

The study found that ZnONPs were highly effective in promoting angiogenesis, leading to enhanced tissue remodeling with a significant increase in newly formed blood vessels on day 7. This aligns with previous studies by Augustine *et al.* and Barui *et al.*, highlighting the angiogenic effects of ZnONPs (Augustine *et al.*, 2014; Barui *et al.*, 2012). Notably, the decline in angiogenesis levels from days 7 to 21 was more pronounced in the ZnONPs group compared to other groups, indicating a superior impact on tissue healing. This supports the potential of ZnONPs in influencing angiogenesis throughout the wound healing process.

Moreover, our study indicates that both AgNPs and ZnONPs modulate tissue remodeling by reducing

inflammatory responses, presenting a potential anti-inflammatory role in wound healing. Mice treated with ZnONPs and AgNPs exhibited a notable reduction in inflammatory cells compared to control mice, affirming the anti-inflammatory properties of ZnONPs and AgNPs. This aligns with studies by Pati et al. in 2016 and Aloe et al. in 2016, which reported ZnONPs' anti-inflammatory activity through inhibition of pro-inflammatory agents (Aloe *et al.*, 2016; Pati *et al.*, 2014). In 2024, Elhabal et al. demonstrated that ZnONPs significantly reduce inflammation and enhance wound healing in rat models, as confirmed by histopathological analysis (Elhabal *et al.*, 2024). Furthermore, a study by Bold and colleagues in 2022 demonstrated that AgNPs contribute to wound healing through anti-inflammatory action and reduction in polymorph nuclear cells (Bold *et al.*, 2022). This study corroborates our current findings, as we observed that the permeability of inflammatory cells in the AgNPs group is significantly lower than the negative control group. In a study by Wasef et al. (2020), AgNPs were shown to promote faster wound healing and reduce inflammation compared to silver sulfadiazine, with better antibacterial effects, lower silver deposition in the liver, brain, and kidney, and improved histological outcomes in a murine burn model (Wasef *et al.*, 2020).

This study has a few limitations. It used specific types of nanoparticles that might not represent those commonly used in clinics. The research looked at short-term effects on wound healing, so long-term results and possible toxic effects are still unknown. It only studied wounds infected with *S. aureus*, so the results might not apply to other infections, including those caused by multidrug-resistant (MDR) strains. Also, it didn't fully examine the potential harmful effects of the nanoparticles on the body.

Conclusion

In conclusion, our detailed study of AgNPs and ZnONPs for treating *S. aureus*-infected wounds reveals interesting details about their roles in wound healing. Both types of nanoparticles demonstrate significant anti-inflammatory properties, effectively reducing inflammatory responses. However, AgNPs outperform in inhibiting bacterial growth at lower concentrations, underscoring their strong antibacterial effects. On the other hand, ZnONPs excel in

promoting re-epithelization, and angiogenesis. Their impressive ability to enhance tissue remodeling, support blood and vessel formation positions them as promising agents for advanced wound healing. This comparative analysis emphasizes the potential for customized approaches in wound management, taking into account the unique strengths of AgNPs and ZnONPs. Future research and clinical applications could benefit from harnessing the specific attributes of each nanoparticle type to optimize therapeutic outcomes across various wound healing scenarios.

Acknowledgements

We would like to thank from Prof. Malahat Ahmadi and Ali Kazemnia for technical assistance in the Department of Microbiology.

Conflicts of interest

The authors declare that there is no conflict of interest.

References

- Abramov Y., Golden B., Sullivan M., Botros SM., Miller JJR., Alshahrour A., et al. Histologic characterization of vaginal vs. abdominal surgical wound healing in a rabbit model. *Wound Repair Regen*, 2007; 15(1): 80-6.
- Ahmadi M. and Adibhesami M. The effect of silver nanoparticles on wounds contaminated with *Pseudomonas aeruginosa* in mice: an experimental study. *Iran J Pharm Res: IJPR*, 2017; 16(2): 661.
- Aloe C., Feltis B., Wright P. and Macrides T. Potential for enhanced wound healing with ZnO nanoparticles. *Front, Bioeng, Biotechnol*, Conference Abstract: 10th World Biomaterials Congress, 2016.
- Augustine R., Dominic EA., Reju I., Kaimal B., Kalarikkal N. and Thomas S. Electrospun polycaprolactone membranes incorporated with ZnO nanoparticles as skin substitutes with enhanced fibroblast proliferation and wound healing. *Rsc Advances*, 2014; 4(47): 24777-85.
- Barui AK., Veeriah V., Mukherjee S., Manna J., Patel AK., Patra S., et al. Zinc oxide nanoflowers make

- new blood vessels. *Nanoscale*, 2012; 4(24): 7861-9.
- Baumans V. and Van Loo P. How to improve housing conditions of laboratory animals: The possibilities of environmental refinement. *Vet J*, 2013; 195 (1): 24-32.
- Chhabra H., Deshpande R., Kanitkar M., Jaiswal A., Kale VP. and Bellare JR. A nano zinc oxide doped electrospun scaffold improves wound healing in a rodent model. *RSC Advances*, 2016; 6(2): 1428-39.
- Daghdari SG., Ahmadi M., Saei HD. and Tehrani AA. The effect of ZnO nanoparticles on bacterial load of experimental infectious wounds contaminated with *Staphylococcus aureus* in mice. *Nanomed J*, 2017; 4(4): 232-236.
- Elhabal SF., Abdelaal N., Saeed Al-Zuhairy SA., Elrefai MF., Elsaied Hamdan AM., Khalifa MM., Hababeh S., et al. Green synthesis of zinc oxide nanoparticles from *althaea officinalis* flower extract coated with chitosan for potential healing effects on diabetic wounds by inhibiting TNF- α and IL-6/IL-1 β signaling pathways. *Int J Nanomedicine*, 2024; 19: 3045-70.
- Etheridge ML., Campbell SA., Erdman AG., Haynes CL., Wolf SM. and McCullough J. The big picture on nanomedicine: the state of investigational and approved nanomedicine products. *Nanomed*, 2013; 9(1): 1-14.
- Foster TJ. Antibiotic resistance in *Staphylococcus aureus*. Current status and future prospects. *FEMS Microbiol Rev*, 2017; 41(3): 430-49.
- Hartemann P., Hoet P., Proykova A., Fernandes T., Baun A., De Jong W., et al. Nanosilver: Safety, health and environmental effects and role in antimicrobial resistance. *Mater Today*, 2015; 18(3): 122-3.
- Jiang B., Larson JC., Drapala PW., Pérez-Luna VH., Kang-Mieler JJ. and Brey EM. Investigation of lysine acrylate containing poly (N-isopropylacrylamide) hydrogels as wound dressings in normal and infected wounds. *J Biomed Mater Res B Appl Biomater*, 2012; 100(3): 668-76.
- Kwan KH., Liu X., To MK., Yeung KW., Ho C-m. and Wong KK. Modulation of collagen alignment by silver nanoparticles results in better mechanical properties in wound healing. *Nanomed*, 2011; 7(4): 497-504.
- Linz MS., Mattappallil A., Finkel D. and Parker D. Clinical impact of *Staphylococcus aureus* skin and soft tissue infections. *Antibiotics*, 2023; 12(3): 557.
- Martinez-Gutierrez F., Olive PL., Banuelos A., Orrantia E., Nino N., Sanchez EM., et al. Synthesis, characterization, and evaluation of antimicrobial and cytotoxic effect of silver and titanium nanoparticles. *Nanomed*, 2010; 6(5): 681-8.
- Mendes CR., Dilarri G., Forsan CF., Sapata VD., Lopes PR., de Moraes PB., et al. Antibacterial action and target mechanisms of zinc oxide nanoparticles against bacterial pathogens. *Scientific Reports*, 2022; 12(1): 2658.
- Bold BE., Urnukhsaikhon E. and Mishig-Ochir T. Biosynthesis of silver nanoparticles with antibacterial, antioxidant, anti-inflammatory properties and their burn wound healing efficacy. *Frontiers in Chemistry*, 2022; 10: 972534.
- Mihu MR., Sandkovsky U., Han G., Friedman JM., Nosanchuk JD. and Martinez LR. The use of nitric oxide releasing nanoparticles as a treatment against *Acinetobacter baumannii* in wound infections. *Virulence*, 2010; 1(2): 62-7.
- Mohanty S., Mishra S., Jena P., Jacob B., Sarkar B. and Sonawane A. An investigation on the antibacterial, cytotoxic, and antibiofilm efficacy of starch-stabilized silver nanoparticles. *Nanomed*, 2012; 8(6): 916-24.
- Panáček A., Kvítek L., Prucek R., Kolář M., Večeřová R., Pizúrová N., et al. Silver colloid nanoparticles: synthesis, characterization, and their antibacterial activity. *J PHYS CHEM B*, 2006; 110(33): 16248-53.

- Pati R., Mehta RK., Mohanty S., Padhi A., Sengupta M. and Vaseeharan B. Topical application of zinc oxide nanoparticles reduces bacterial skin infection in mice and exhibits antibacterial activity by inducing oxidative stress response and cell membrane disintegration in macrophages. *Nanomed*, 2014; 10(6): 1195-208.
- Raghupathi KR., Koodali RT. and Manna AC. Size-dependent bacterial growth inhibition and mechanism of antibacterial activity of zinc oxide nanoparticles. *Langmuir*, 2011; 27(7): 4020-8.
- Serra R., Grande R, Butrico L., Rossi A., Settimio U.F, Caroleo B., et al. Chronic wound infections: the role of *Pseudomonas aeruginosa* and *Staphylococcus aureus*. *Expert Rev Anti Infect Ther*, 2015; 13(5): 605-13.
- Sirelkhatim A., Mahmud S., Seeni A., Kaus NHM., Ann LC., Bakhori SKM., et al. Review on zinc oxide nanoparticles: antibacterial activity and toxicity mechanism. *Nano-micro letters*, 2015; 7: 219-42.
- Vendrame S., Alaba T., Marchi N., Tsakiroglou P. and Klimis-Zacas D. In vitro and in vivo evaluation of bioactive compounds from berries for wound healing. *Curr Dev Nutr*, 2024: 102078.
- Wasef LG., Shaheen HM., El-Sayed YS., Shalaby TI., Samak DH., Abd El-Hack ME., et al. Effects of silver nanoparticles on burn wound healing in a mouse model. *Biol Trace Elem Res*, 2020; 193: 456-65.
- Ziv-Polat O., Topaz M., Brosh T. and Margel S. Enhancement of incisional wound healing by thrombin conjugated iron oxide nanoparticles. *Biomater*, 2010; 31(4): 741-7.



ارزیابی مقایسه‌ای نانوذرات نقره و اکسید روی در ترمیم زخم‌های آلوده به استافیلوکوکوس اورئوس: مطالعه پیش بالینی

شبنم گلبوی داغداری^{۱*}، علی اصغر تهرانی^۲

^۱گروه میکروبیولوژی، دانشکده دامپزشکی، دانشگاه ارومیه، ارومیه، ایران

^۲گروه پاتوبیولوژی، دانشکده دامپزشکی، دانشگاه ارومیه، ارومیه، ایران

تاریخ دریافت: ۱۴۰۳/۰۴/۳۰ اصلاح نهایی: ۱۴۰۳/۰۶/۲۰ تاریخ پذیرش: ۱۴۰۳/۰۷/۲۹

چکیده

زمینه و هدف: عفونت‌های پوست و زخم که توسط *استافیلوکوکوس اورئوس* ایجاد می‌شوند، به دلیل افزایش مقاومت آنتی‌بیوتیکی نیازمند راهکارهای درمانی جایگزین هستند. این مطالعه با هدف مقایسه و ارزیابی تأثیر نانوذرات اکسید روی (ZnONPs) و نانوذرات نقره (AgNPs) در محدوده ۲۰ تا ۳۰ نانومتر بر روند ترمیم زخم‌های عفونی انجام شد.

مواد و روش‌ها: چهل و هشت موش نر به‌طور تصادفی به چهار گروه تقسیم شدند. زخم‌های تمام ضخامت پوستی در پشت حیوانات تحت بیهوشی ایجاد شد و سپس با سوسپانسیون باکتریایی *استافیلوکوکوس اورئوس* با غلظت 10^8 CFU/ml آلوده گردیدند. درمان‌های موضعی شامل ۴۰ میکرولیتر ZnONPs، ۴۰ میکرولیتر AgNPs، تتراسایکلین و سرم نمکی در بستر زخم‌ها اعمال شد. نظارت ماکروسکوپی و بررسی‌های هیستوپاتولوژیک در روزهای ۷، ۱۴ و ۲۱ برای ارزیابی بازسازی اپیتلیوم، التهاب و رگ‌زایی انجام شد. اثر بخشی ضدباکتریایی با تعیین MIC سنجیده شد و برای تحلیل آماری از نرم‌افزار SPSS استفاده گردید.

یافته‌ها: نتایج MIC نشان‌دهنده تفاوت معنادار در فعالیت ضدباکتریایی بود، به‌طوری‌که AgNPs با غلظت ۳/۹۱ میکروگرم/میلی‌لیتر و ZnONPs با غلظت ۱۲۵ میکروگرم/میلی‌لیتر نشان دادند که AgNPs در غلظت‌های پایین‌تر از کارایی بالاتری برخوردار است. در بررسی ماکروسکوپی زخم‌ها، هر دو نانوذره AgNPs و ZnONPs تسریع قابل توجهی در بسته شدن زخم‌ها نشان دادند که به‌طور معناداری از گروه کنترل منفی ($p < 0.05$) پیشی گرفتند. با این حال، در تحلیل‌های هیستوپاتولوژیک تمایز دقیقی مشاهده شد؛ هرچند که هر دو نانوذره به‌طور مشابهی در کاهش التهاب مؤثر بودند، ZnONPs اثرات بهتری در بازسازی اپیتلیوم و رگ‌زایی بدون ایجاد سمیت سلولی نسبت به سایر گروه‌ها نشان دادند.

نتیجه‌گیری: این مطالعه نتیجه‌گیری می‌کند که AgNPs عوامل ضدباکتریایی قوی هستند، در حالی که ZnONPs به‌طور قابل توجهی به بهبود ترمیم زخم کمک می‌کنند. تحلیل مقایسه‌ای بین این دو نانوذره بینش‌های ارزشمندی در رابطه با مدیریت زخم فراهم می‌آورد که نقاط قوت خاص هر نانوذره را مد نظر قرار می‌دهد. تحقیقات و کاربردهای بالینی آینده می‌توانند از این نتایج درمانی در پژوهش‌های مختلف ترمیم زخم بهره‌مند شوند.

واژه‌های کلیدی: *استافیلوکوکوس اورئوس*، نانوذرات اکسید روی، نانوذرات نقره، ترمیم زخم

شبنم گلبوی داغداری، علی اصغر تهرانی. ارزیابی مقایسه‌ای نانوذرات نقره و اکسید روی در ترمیم زخم‌های آلوده به *استافیلوکوکوس اورئوس*: مطالعه پیش بالینی. مجله طب دامپزشکی جایگزین. ۱۴۰۳؛ ۷(۲۲): ۱۳۲۱-۱۳۳۲.

* نویسنده مسئول: گروه میکروبیولوژی، دانشکده دامپزشکی، دانشگاه ارومیه، ایران.