

Ultrasonographic measurements of prostatic dimensions in adult Iranian mix breed dogs

Vali, R.*

Department of Clinical Sciences, School of Veterinary Medicine, Kazerun branch, Islamic Azad University, Kazerun, Iran.

* **Corresponding Author:** R.Vali, Department of Clinical Sciences, School of Veterinary Medicine, Kazerun Branch, Islamic Azad University, Kazerun, Iran, *Email* : Rohamvali@gmail.com

(Received: June 10, 2018; Accepted: August 20, 2018)

Abstract

The prostate gland is located ventral to the colon and caudal to the neck of the urinary bladder, in an abdominal or pelvic position. Diagnostic ultrasound can be used as a precise, non-invasive and reliable method for assessing prostate in dogs. In this research, 10 adult male Iranian mix breed dogs with an age average of 7.45 ± 1.83 years and an average weight of 21.35 ± 5.57 kg with clinical symptoms of prostatitis were selected. Sagittal and transverse ultrasound images was performed by using a 5 MHZ convex transducer. In the obtained images desired parameters such as length, width and height of the prostate gland were measured. Measurements of this study may be different from those reported in other breeds, so it can be used as reference values for diagnosis of prostate diseases in Iranian mix breed dogs.

Key words: *Ultrasonographic measurements, prostate, Iranian mix breed dogs*

Introduction

The prostate gland is located ventral to the colon and caudal to the neck of the urinary bladder, in an abdominal or pelvic position (Debiak and Balicki, 2009). Its size varies with the weight and breed of the dog e.g. it is physiologically bigger in breeds like Westies and Scottish Terriers than others (Kealy *et al.*, 2011). During the dog's life, the development of the prostate may be divided into three periods. The first begins at embryogenesis and ends at the age of 2 to 3 years of age. The second phase begins in the young adulthood and ends around 12 to 15 years of age: it is a clear androgen-dependant phase which is characterized by an exponential hypertrophic development (Verstegen, 2001). It is commonly accepted that, after 5 years of age, most dogs (> 60%) show a certain degree of prostatic hypertrophy (Berry *et al.*, 1986). The prostate is clearly enlarged and hypertrophic in nearly 100% of dogs around the age of 10 to 12 years. The position of the prostate changes slowly as it increases in size (Paclikova *et al.*, 2006; Parry *et al.*, 2006; Bradbury *et al.*, 2009). It is located in the pelvis in young dogs, and becomes more abdominal and then fully abdominal after 8-12 years (Zohil *et al.*, 1995). The third phase is

a senile involution which begins when, in very old dogs, the production of androgens slowly begins to decrease (Verstegen, 2001). Benign enlargement of the prostate gland associated with glandular hyperplasia or squamous metaplasia has been shown to start in dogs as early as 2 years of age. It is often considered as a common finding related to age but can lead to urologic and digestive disorders (Olson *et al.*, 1987). Therefore, identification and characterisation of BPH is important. In one study, 95% of intact beagles over 9 years of age were affected. Prostate enlargement may be symmetrical or asymmetrical or associated with loss of the bilobed shape in transverse section. The diagnosis of prostatic disorders requires a gland assessment by physical and imaging examinations. The ultrasonographic appearance of the prostate gland provides information on the shape, dimensions, lobular structure, and echotexture of the gland parenchyma (Atalan *et al.*, 1999). It also shows the prostate urethra and is feasible for an assessment of the gland capsule and adjacent tissues. The most widely applied diagnostic tool to scan the prostate gland is transabdominal ultrasound (Ruel *et al.*, 1998). When the prostate is in pelvic location, the presence of the pubic bone impairs the ultrasonographic approach. The use of a curved array transducer and scanning the dog in a standing position can facilitate visualization of the gland. A 5-7 MHz frequency probe is commonly used. The normal prostatic contour is well-delimited by a thin, hyperechoic capsule (Atalan *et al.*, 1999^a). As observed this happens almost in most of the breeds of dogs; therefore, this study is to assess the prostatic gland, echotexture, location and size in Iranian mix breed dogs.

Materials and methods

Ten adult Iranian mix breed male dogs aged 6.90 ± 2.09 years with the weight average of 23 ± 4.47 cm were used in this study. All the dogs were prepared for the examinations which include physical, abdominal and rectal examination which their results were recorded for each dog. The dogs were sedated with acethylpromazine 2 mg/kg B.w.t given intramuscularly. After cleaning and washing, hair was clipped and shaved on both sides of prepuce. Transabdominal ultrasonography was performed by using a 5 MHz convex transducer (BK Medical minifocus). Coupling gel was applied on the skin to improve contact. For each dog, sagittal and transverse images of the prostate gland were obtained. True sagittal position was confirmed by observation of the hypoechoic urethral tract.

Ultrasonographic Measurements

In sagittal and transverse images the following parameters were measured:

1.Length: The length is well measurable on the sagittal images and was defined as the maximum diameter of the gland along the urethral axis (Figure 1).

2.Height: The height of the prostate is measureable on both sagittal and transverse images and defined as the diameter of prostate on a line separating the two lobes of the gland (Figure 1).

3.Width: the width is measureable on the transeverse images and was defined as the maximum diameter perpendicular to the axis of the height (Figure 2). All images should be provided where the transducer is perpendicular to the skin to avoid oblique sections of the prostate.

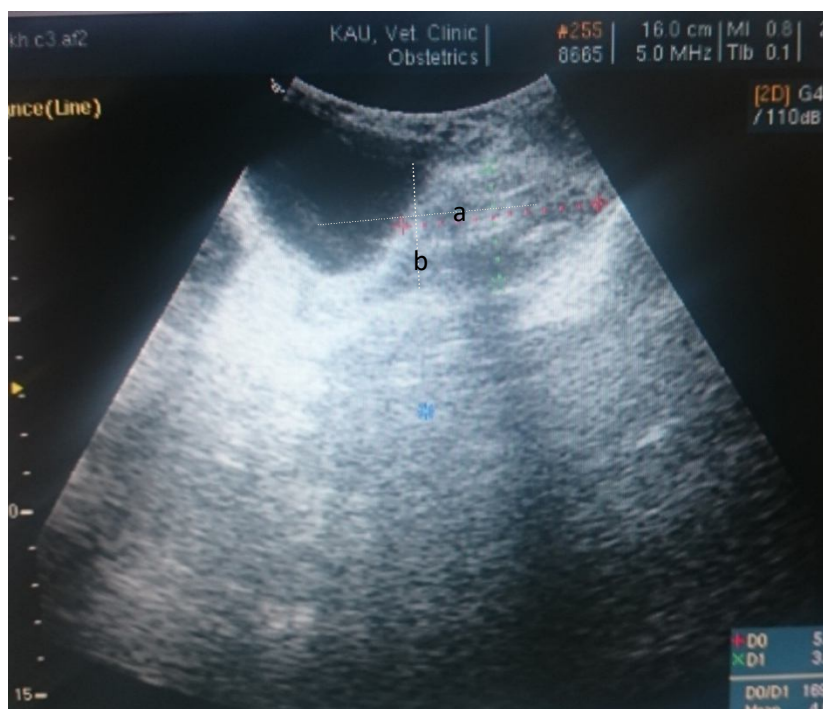

Figure 1. Sagittal ultrasonographic image from the prostate indicating the measured parameters

Parameters: a = Length, b = Height

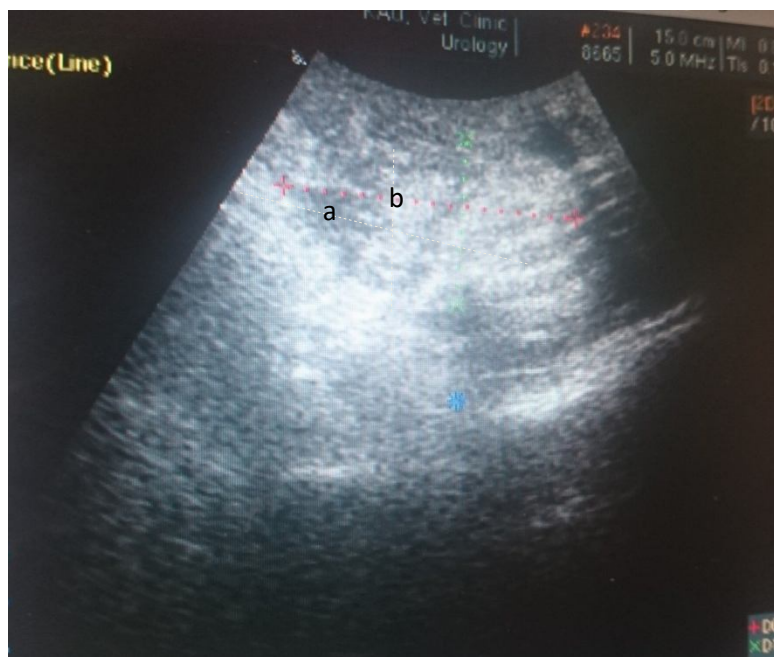


Figure 2. Transverse ultrasonographic image from the prostate indicating the measured parameters

Parameters: a = Depth, b = Height

Results

As it could be observed in the images the shape, echotexture and symmetry of the prostate gland are less changed.

Table 1 summarizes the results of measurements in both sagittal and transverse images from the prostate gland of all the dogs that describe the location and size of the prostate. In Table 2 the results of this study are compared with that of other reports.

Table1. Ultrasonographic Prostatic measurements in 10 adult Iranian mix-breed dogs

Parameter(cm)	Mean \pm SD	Min Max
Prostatic Length(cm)	6.23 \pm 0.82	4.858.28
Prostatic Height(cm)	4.08 \pm 0.33	3.155.5
Prostatic Depth(cm)	5.11 \pm 0.60	3.997.20

Table2. A comparison of the results of this study and other reports

Prostatic length(cm)	prostatic height(cm)	prostatic depth(cm)	Reference
6.23 \pm 0.82	4.08 \pm 0.33	5.11 \pm 0.06	This study
3.4 \pm 1.10	2.8 \pm 0.08	3.3 \pm 0.09	Ruel et al. (1998)
5.4 \pm 1.30	2.34.3 \pm 1.11	-	Atalan et al. (1999)
3.35 \pm 0.4	2.78 \pm 0.5	3.42 \pm 0.53	Ghadiri et al.(2013)

Discussion

There are plenty of published studies on radiographic and ultrasonographic measurements of prostate gland in humans and dogs (Atalan *et al.*, 1999^a; Atalan *et al.*, 1999^b; Ruel *et al.*, 1998; Nair *et al.*, 2012; Ghadiri *et al.*, 2013). Several hypotheses are formed on the causes of the prostate diseases; one suggests that *benign* prostatic hyperplasia mainly affects older dogs than young ones (Berry *et al.*, 1986). According to this theory, B.P.H is an age related disease observed in most breeds (Johnston *et al.*, 2000). Atalan *et al.* (1999) measured prostatic dimensions in different breeds of dogs with both radiography and ultrasonography methods, then the comparison of the results were made (Atalan *et al.*, 1999). According to these authors, ultrasonography is more accurate in differentiation of soft tissues and fluids. They also reported that the amount of prostatic length and width were 5.4 ± 1.30 , 4.3 ± 1.11 respectively (Atalan *et al.*, 1999). Ruel *et al.* (1998) evaluated the prostate in 100 healthy adult intact male dogs. They compared prostatic parameters with parameters related to body size such as height and weight. They found Significant positive correlations between all prostatic parameters and parameters related to body size and age (Ruel *et al.*, 1998). The amount of prostatic length and width in mentioned study were 3.4 ± 1.1 cm and 3.3 ± 0.9 cm (Ruel *et al.*, 1998). Ghadiri *et al.* (2013) measured the prostatic dimensions in 10 intact male dogs referred to veterinary teaching hospital that required euthanasia for reasons other than prostatic disease. Their body weights ranged 16-23 kg and their age range was between 2 to 4 years of age (Gadiri *et al.*, 2013). The findings of the present study slightly differed from the findings of the studies like Ruel *et al.* (1998) and Ghadiri *et al.* (2013). This current study obtained greater prostatic length and width compared to the above-mentioned studies. These differences were probably due to differences in breed, age and number of dogs. However; the findings of Atalan *et al.* (1999) are in agreement with the results obtained in this current study. Debiak and Balicki (2009) evaluated the prostate gland size and location in 33 male dogs of various breeds. They showed that the application of transabdominal imaging technique produced images with good quality details from the cranial prostate region in all the examined animals from the cases with a normal size of the prostate gland (Debiak and Balicki, 2009). Zohil *et al.* (1995) compared two techniques of ultrasound imaging for prostate gland scanning. They reported that when the prostate is not enlarged and is located in pelvis area, transrectal ultrasonography well show the changes in echotexture and capsule of prostate gland, while enlarged prostate were observed in abdominal portion and well

observed with transabdominal ultrasonography (Zohil *et al.*, 1995). Transabdominal ultrasonography was used in this study based on the age average of the dogs (over 6 years old) and prostatic dimensions and changes were recorded.

In conclusion, measurements of this study may be different from those reported in other breeds, so it can be probably used as a template for diagnosis of prostate-related diseases such as benign prostatic hyperplasia in Iranian mix breed dogs.

References

- Atalan G., Barr FJ. and Holt PE. Comparison of ultrasonographic and radiographic measurements of canine prostate dimensions. *Veterinary Radiology and Ultrasound*, 1999a;40: 408-412.
- Atalan G., Holt PE., Barr FJ. and Brown PJ. Ultrasonographic estimation of prostatic size in canine cadavers. *Research in Veterinary Science*, 1999b; 67:7-15.
- Berry SJ., Coffey DS. and Ewing LL. Effects of aging on prostate growth in beagles. *American Journal of Physiology*, 1986; 250: R 1039-46.
- Bradbury CA., Westropp JL. and Pollard RE. Relationship between prostatomegaly, prostatic mineralization, and cytologic diagnosis. *Veterinary Radiology and Ultrasound*, 2009; 50(2): 167-71.
- Debiak P. and Balicki I. Diagnostic imaging of the canine prostate gland subject to its location and size. *Bulletin of the Veterinary Instiyute in Pulawy*, 2009; 53: 313-317.
- Ghadiri A., Avizeh R., Baniadam A. and Ranjbar A. Comparison of Transabdominal and Transrectal Ultrasonography of the Prostate Gland in Dogs. *Iranian journal of veterinary surgery*, 2013; 8(2): 43- 48.
- Johnston SD., Kamolpatana K., Root- Kurshtitz MV. and Johnston GR. Prostatic Disorders of the dog. *Animal Reproduction Science*, 2000; 60-61 : 405-415.
- Kealy KJ., McAllister, H. and Graham JG. *Diagnostic Radiology and Ultrasonography of the Dog and Cat*, 5th Ed Saunders, an imprint of Elsevier Inc, 2011; PP:175-181.
- Nair DR., Ghosh KNA. and Harshan HM. Estimation of prostatic size in dogs using transabdominal ultrasonography, 2012;33 (2): 79- 81.
- Olson PN., Wrigley RH., Thrall MA. and Husted PW. Disorders of the canine prostate gland: Pathogenesis, diagnosis and medical therapy. *Compendium Continuing Education Practice Veterinary*, 1987; 9: 613-623.
- PacIlkova K., Kohout P. and Vlasin M. Diagnostic possibilities in the management of canine prostatic disorders. *Veterinarni Medicina*, 2006; 51:1-18.
- Parry NMA. Inflammatory diseases of the canine prostate gland. *UK Veterinary Small Snimal Medicine*, 2006;11(8), 1- 4.

Ruel Y., Barthez PY., Mailles A. and Begon D. Ultrasonographic evaluation of the prostate in healthy intact dogs. *Veterinary Radiology and Ultrasound*, 1998; 39(3): 212-216.

Verstegen JP. Conditions of the male In. G. Simpson, G. England and M. Harvey.
“BSAVA. Manual of Small Animal Reproduction and Neonatology”. BSAVA. Ed, 2001; PP: 71-82.

Zohil AM. and Castellano C. Prepubic and transrectal ultrasonography of the canine prostate: A comparative study. *Veterinary Radiology and Ultrasound*, 1995; 36: 393-396.