

Radiographic study of navicular bone in hind feet of sound Dareh-shori horses

RohamVali*

Department of Clinical Sciences, School of Veterinary Medicine, Kazerun branch, Islamic Azad University, Kazerun, Iran.

* Corresponding Author's E.Mail : Rohamvali@gmail.com

(Received: May 2, 2017; Accepted: October 27, 2017)

Abstract

Navicular abnormalities has long been considered one of the most common causes of fore limb lameness. Radiographic evaluation is one of the most valuable, economic, and initial diagnostic tools used in the evaluation of equine lameness. This is dictated by the knowledge of the veterinarian and quality of radiographic equipment. This study was conducted to estimate radiological factors refers to hind feet. According to this purpose six clinically normal Dareh-shori horses were used in this study. After cleaning and washing the horses hooves, hand-made block placed under the following limb, both hind feet were radiographed with the limb in vertical position. The obtained measurements and values in this study were as: Proximal-distal border length of the navicular bone (lateral) = 14.33 ± 0.85 mm; Lateral-Medial Border length of the navicular bone = 43.19 ± 4.36 mm; Proximal-distal border length of the navicular bone(Dorso palmar) = 25.75 ± 3.78 mm. Measurements of this study may be different from those reported in other breeds, so it can be used as reference values for diagnosis of navicular abnormalities in hind feet of Dareh-shori horses.

Key words: Radiographic measurements, Hind feet, Dareh-shori horses, Navicular bone

Introduction

The navicular is a small bone that sits deep within the hoof at the back junction of the coffin bone and the short pastern bone (Butler et al., 2008; Shively, 1977). It is an element of the distal interphalangeal joint between the middle and distal phalanx within the hoof (Butler et al., 2008; Kazer-Hotz and Ueltschi, 1992; Shively, 1977). Despite its small size, it plays an important role in the movement of the limb. It is a bone pad on which the deep digital flexor tendon slides. It also stabilizes the distal interphalangeal joint (Dyson et al., 2011; Quickand Rendano, 1977). Navicular lameness leads to significant financial losses and often ends the career of the horse (Rose, 1996). The causes of navicular disease are still not fully understood, and treatment usually only slows down the progression of the disease (Rijkenhuizen, 2006; Rose, 1996). An additional difficulty is that the clinical symptoms of altered navicular bone are diverse. Radiographs of horses with diagnosed navicular syndrome (NS) frequently show four types of changes: cavities on the flexor surface, distal border fragments, enlarged synovial fossa and osteophytes (Claerhoudt et al., 2011; Biggiand Dyson, 2011). These lesions may occur independently or, in some cases, collectively. Poor trimming, shoe selection, or inappropriate shoe attachment are well-known causes of lameness, and navicular disease is fairly common in the domesticated horse (Kummer et al., 2005). However, it is also seen in wild horse populations. Those who advocate “barefoot trimming” of domestic horses propose that in nature, a horse’s hoof is designed to expand and contract as the horse moves (Ovnicek et al., 2003; Rose, 1996). This expanding and contracting act as an auxiliary blood pump, and aids the circulation of blood to the lower extremities. When an inflexible metal shoe is improperly attached to the hoof, the hoof

can no longer work as designed, and blood flow is inhibited (Ovniczek et al., 2003). Dareh-shori horse is one of the indigenous Persian (Persian-Arabic) horses. This horse is recognized as one of the best races for free horse-riding and long-distance races (Vali and Ahmadi-Rahnemon, 2017). Lateromedial (LM) and dorsoplantar (DP) views of the distal limb are very helpful in assessing the hoof with all the structures in it. Radiography is often the first method used for supporting a clinical diagnosis of navicular abnormalities (Butler et al., 2004; Kummer et al., 2005). At least lateromedial and dorsoplantar projections required to fully evaluate the equine navicular bone (Kummer et al., 2004). This study measured the distances in order to establish a database of normal values in Dareh-shori horses to compare with the results of other reports.

Materials and methods

Six apparently healthy Dareh-shori horses aged 5.25 ± 1.72 years and the mean height of 141 ± 8.15 cm were used in this study. All of the horses had no previous history of lameness and they were all clinically sound and the feet showed no abnormality or distortion. The sole and wall were cleaned using a hoof pick and wire brush. A straight stiff wire marker, of known length (20 mm), was taped to the dorsal hoof wall. The horse's feet were radiographed standing on a flat wooden block 70 mm thick incorporating a metal ground line. Both hind feet were radiographed with the limb in vertical position. Radiographs were made using a portable X-ray unit with 5 mAs, 80 kVp exposure factors.

Radiographic Measurements

Dorsoplantar and lateromedial Radiographs were fixed onto a horizontal viewing box and lines were drawn with a fine tipped pen. Following measurements were made from each radiograph (Figure1,2).

1. Proximal-distal border length of the navicular bone in lateral projection, after correcting for magnification according to the M.C.F formula.
2. Lateral-Medial Border length of the navicular bone after correction for magnification according to the M.C.F formula.
3. Proximal-distal border length of the navicular bone in Dorsoplantar projection.

M.C.F= Actual length of marker / radiographic length of marker so the true distance = length measured radiographically x M.C.F

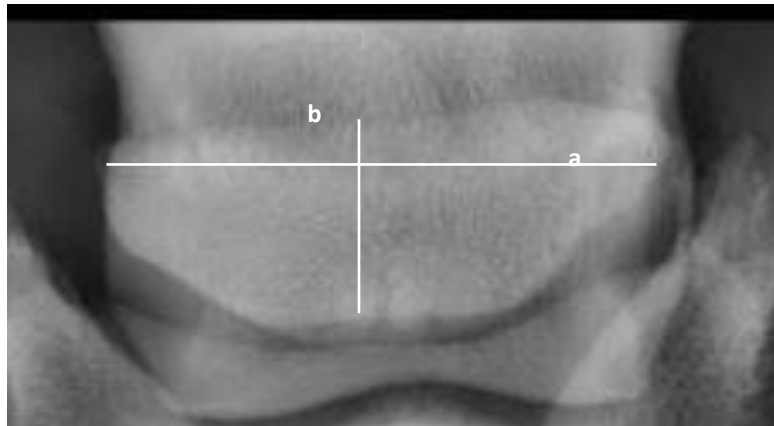


Fig.1.Dorsoplantar radiograph from the hind distal phalanx of a normal horse that indicating the measured parameters of navicular bone

Parameters: a = Lateral-Medial Border length of the navicular bone

b = Proximal-distal Border length of the navicular bone

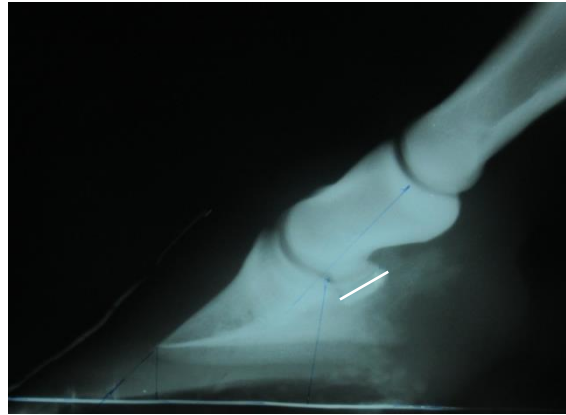


Fig.2. Lateromedial radiograph from the hind distal phalanx of a normal horse that indicating the Proximal-distal border length of the navicular bone (navicular width).

Results

Table 1 summarise the results of Measurements of navicular bone in both lateromedial and dorsoplantar radiographs from the hind feet of all horses that describe the position of navicular bone in relation to the distal interphalangeal joint. No significant differences was found between left and right feet obtained in this study. In Table 2 the results of our study compared with that of other reports.

Table1. Radiographic measurements of navicular bone from the hind feet of 6 normal Dareh-shori horses

Parameter	Mean		SD		Min		Max	
	LT	RT	LT	RT	LT	RT	LT	RT
Proximal-distal border length of the navicular bone(lateral)(mm)	14.66	14	0.82	0.89	14	13	16	15
Lateral-Medial Border length of the navicular bone (DP) (mm)	44	42.83	3.34	5.38	40	37	48	49
Proximal-distal Border length of the navicular bone (DP) (mm)	25.50	26	3.93	3.63	20	20	29	29

Table2.Morphometric comparison between this study and other reports

Types of horses	Mean ± SD(mm)	Reference
Greatest breadth of the navicular bone		
Dareh-shori	43.19± 4.36 (Hind feet)	This study
Dareh-shori	44.85± 3.6 (front feet)	Vali et al. (2017)
Saddle horses	56.8± 4.7	Komosa et al. (2013)
Harness horses	60.5± 3.7	Komosa et al. (2013)
Ponies	51.1± 6.2	Komosa et al. (2013)
Greatest thickness of the navicular bone		
Dareh-shori	14.33± 0.85	Tis study
Dareh-shori	14.75±1.4	Vali et al. (2017)
Saddle horses	14.6 ± 1.2	Komosa et al. (2013)
Harness horses	15.7± 1.0	Komosa et al. (2013)
Ponies	13.4 ± 1.4	Komosa et al. (2013)
Warmblood horses (40)	17 ± 1.5	Kumer et al. (2005)

Discussion

There are published studies on radiographic and morphometric measurements of navicular bone in front feet of horses (Dyson et al., 2011; Gabriel et al., 1998; Komosa et al., 2013; Kummer et al., 2005; Pares Casanova and losano, 2015; Vali and Miri, 2017). While few radiographic studies have been reported on navicular bone measurements in hind feet (Gabriel et al., 1998). Several hypotheses are on the causes of the navicular diseases, one suggests that ND mainly affects horses whose hooves are too small in relation to their weight (Dikk, 1995; Gabriele et al., 1998; Kummer et al., 2005). According to this theory, a small hoof capsule contains a navicular bone which is too small to withstand the pressure exerted on it. This pressure is exerted via the DDFT, which slides over the area and stretches to the solar surface of the distal phalanx. Gabriel et al studied the parameters in front and hind feet of 95 mix breeds. According to these authors, In ponies, navicular bone measurements were smallest for light ponies and regularly increased with body size, but in horses, navicular bone dimensions were smallest for the athletic halfbred,

intermediate for draft horse, thoroughbreds and sedentary halfbreds and largest for heavy halfbreds (Dikk et al., 2001; Gabriel et al., 1998). According to Gabriel et al., during a morphometric study on navicular bone size and its relation with age they found that, there is a positive relationship between the age of horse and size of bone (Gabriel et al., 1998). In another comparative morphometric study on navicular bone, they indicated that the values of navicular bone in front feet is greater than the hind feet (Gabriel et al., 1997). The finding of our study was in close agreement with Gabriel et al. In present study the lowest recorded for the bone width belongs to the youngest horse. In the previous study, which was performed on front feet of Dareh-shori horses, breadth of the navicular bone showed higher values (Vali and Miri, 2017). Dareh-shori horses have small hoof size when compared with other type of horses (Vali and Ahmadi-Rahnemon, 2017). The measurement of Breadth of navicular bone in this study is in close agreement with the results of Gabriel. (Gabriel et al., 1998). According to Komosa et al., 2013, the mean breadth of navicular bone measurements from front feet of ponies horses was 51.1 ± 6.2 mm (Komosa et al., 2013). In our study the mean Breadth is 43.19 ± 4.36 mm. Another parameter that measured in this study is thickness of the navicular bone. The amount of this parameter is close to the result of Komosa study on saddle horse (Komosa et al., 2013). In current study thickness of navicular bone is about 14.33 ± 0.85 mm. However, the finding obtained in this study was different from kummer et al, 2005. According to Kummer et al. (2005), the mean thickness of navicular bone from front feet of Warmblood horses were 17 ± 1.5 mm (Kummer et al., 2005). Differences between the two studies may be related to breed or type of horses. Table 2 shows a morphometric comparison between the results of this study and that of other reports (table 2).The differences between left and right feet were not statistically

significant ($P>0.05$). Generally, differences in parameters measured in this study may be due to variations in hoof size and shape, horse type or breed as a consequence of navicular abnormalities.

References

Biggi, M. and Dyson S. (2011). High-field magnetic resonance imaging investigation of distal border fragments of the navicular bone in horses with foot pain. *Equine Veterinary Journal*, 43: 302-308.

Butler, J.A. Colles C.M. Dyson S.J. Kold S.E. and Poulos W. (2008). Foot, Pastern and Fetlock. In: *Clinical Radiology of the Horse*. West Sussex: Wiley-Blackwell, 53-128.

Claerhoudt, S., Pille F., Vanderperren K., Hauspie S., Duchateau L., Vandervekens E. and Saunders J.H. (2011). Association between navicular bone fragmentation and shape in Belgian Warmblood horses. *Veterinary and Comparative Orthop. Traumatology*, 24: 132-136.

Dikk, J. and Broekvanden, J.(1995). Role of navicular bone shape in the pathogenesis of navicular disease: a radiological study. *Equine Veterinary Journal*, 27: 390-393.

Dikk, J. Beltand A.J.M. and Broekvanden J. (2001). Relationships of age and shape of the navicular bone to the development of navicular disease: a radiological study. *Equine Veterinary Journal*, 33: 172-175.

Dyson, S. Murray R. Schramme M. and Blunden T.(2011). Current concepts of navicular disease. *Equine Veterinary Education*, 23: 27-39.

Gabriel A., Jolly S. Detileux J. Dessy-Doize C. Collin B. and Reginster J.Y. (1998). Morphometric study of the navicular bone: variations with breeds and types of horse and influence of exercise. *Journal of Anatomy*, 193: 535-549.

Gabriel, A. Yousfi S, Detilleux J, Dessy-Doize! C. and Collin B. (1997). Morphometric study of the equine navicular bone: comparisons between fore and rear limbs. *Journal of Veterinary Medicine, Series A* 44: 579-594.

Kazer-Hotz, B. and Ueltschi G. (1992). Radiographic appearance of the navicular bone in sound horses. *Veterinary Radiology and Ultrasound*, 33: 9-17.

Komosa, M. Purzyc H. and Fryckowlak H. (2013). Changes in Navicular Bone (os sesamoideum distale) Shape in Horses as a Result of Pathological Alterations. *Folia Biologica (Kraków)*, 61: 1-10.

Kummer, M. Gayer H. Imboden I. Auer J. and Lischer C. (2005). The effect of hoof trimming on radiographic measurement on the front feed of normal warmblood horses. *Veterinary Journal*, 172: 58-66.

Kummer, M. Lischer, C. Vargas J. and Hugelshofer J. (2004). Evaluation of a standardised radiographic technique of the equine hoof. *Schweizer Archiv f r Tierheilkunde*, 11: 507-514.

Ovnicek, G. Page B. and Trotter G.W. (2003). Natural balance trimming and shoeing: its theory and application. *The Veterinary Clinics of North America Equine Practice*, 19: 353-377.

Pares Casanova, P.M. and Lozano S. (2015). Morphometry of equine distal sesamoid bone on clinically normal horses. *Journal of Dairy, Veterinary & Animal Research*, 2(1): 1- 4.

Quick, C.B. and Rendano V.T. (1977). Equine radiology; the pastern and foot. *Modern Veterinary Practice*, 58: 1022-1027.

Rijkenhuizen, A. B. M. (2006). Navicular disease: A review of what's new. *Equine Veterinary Journal*, 38: 82-88.

Rose, R. J.(1996). Navicular disease in the horse. *Journal of Equine Veterinary Science*, 16: 18-24.

Shively, M.J. (1997). Normal radiographic anatomy of the equine digit. *Southwest Veterinarian*, 30: 193-199.

Vali, R. and Ahmadi-Rahnemon A. (2017). Radiographic evaluation of hoof parameters related to laminitis in clinically normal Dareh-shori horse. *Journal of Alternative Veterinary Medicine*, 1(1): 43-48.

Vali, R. and Miri A. (2017). Reference radiographic measurements for navicular bone of Dareh-shori horses. *Online Journal of Veterinary Research*, 21(7): 428-432.