

Internal Helminthes parasite Isolated from some cyprinid fish in Shapour River and Seyyed Hossein Spring

Golchin Manshadi, A.R.^{1*} ;Mohamadi, A.²

¹Department of Aquatic Animal Health, Faculty of Veterinary Medicine, Kazerun Branch, Islamic Azad university, Kazerun, Iran;²Gratuated from Faculty of Veterinary Medicine, Kazerun Branch, Islamic Azad university, Kazerun, Iran;

*Corresponding author: A.R. Golchin Manshadi, Department of Aquatic Animal Health, Faculty of Veterinary Medicine, Kazerun Branch, Islamic Azad University, Kazerun, Iran, Email: golchinalireza@yahoo.com.

Summary

In this study, 38 fish in four species of Shapour River and Seyyed Hossein Spring were caught in 2016, including: *Alburnus mossulensis*(kuli), *Cyprinion macrostomum*(Lotak), *Capoeta barroisi persica*(Siah mahi) and *Garra rufa* (Doctor fish)and they were studied internal helminthes parasites. Totally, four parasites were isolated and recognized, including: two Digenea (*Allocreadium* sp. and *Haplorchis* sp.),one Cectoda (*Bothriocephalus* sp.),one Nematoda (*Rhabdochona* sp.)The results showed that the highest percent of parasitic infection was for *Allocreadium* sp. and the least amount was reported for *Haplorchis* sp. Moreover, kuli and Siah mahi had the highest and lowest percent of parasitic infection, respectively. There wasn't any meaningful relationship between fish species and frequency of infection ($P>0/05$). However significant relationship was detected between sex and frequency of infection ($P\leq0/05$).

Keywords: *Internal Helminthes, Seyyed Hossein Spring, Shapour River, Cyprinid Fish, Kazerun*

Introduction

Parasites in fish have been a great concern since they often produce disease conditions in fish which will lead to reduced growth, increase in the fishes' susceptibility to other diseases as well as fish loss. Parasites may be the cause of growth reduction, fatality, delayed puberty or infertility in the fish and they are often the reason for microbial, viral and fungal diseases. In some cases, parasites are the cause of high fatality of the fish (Abbasi, 2003).Studies on parasites of Iranian fish species date back to 1949, when Bychowsky reported three Dactylogyrus species and one Ancyrocephalus on the gills of fishes in Karkheh River. Since then other researchers reported more parasites from Iranian freshwater fish. Iranian freshwater fish habitats can be categorized according to three different faunal regions: the Ponto-Caspian Territory of northern Iran, as a part of the Palaearctic zone; southeastern Iran that is greatly influenced by the Indian faunal region, and southwestern Iran that falls within the Mesopotamian intermediate faunal region (Figure 1). Various studies have been conducted with respect to the study of parasite infection of freshwater fish in Mesopotamian and the other areas in Iran (Pazooki and Masoumian,2012). The most important studies in this area are as: Mortezaei et al. (2000) on parasite infection of freshwater fish in Hoorolazim and Shadegan Suns, Farahnak et al. (2002) in Khuzestan Basins, Abbasi et al. (2003) and Barzegar et al. (2004) studying parasites of the Behesht Abad River, and Raissy et al. (2009) in identifying the parasites of 3 kinds of

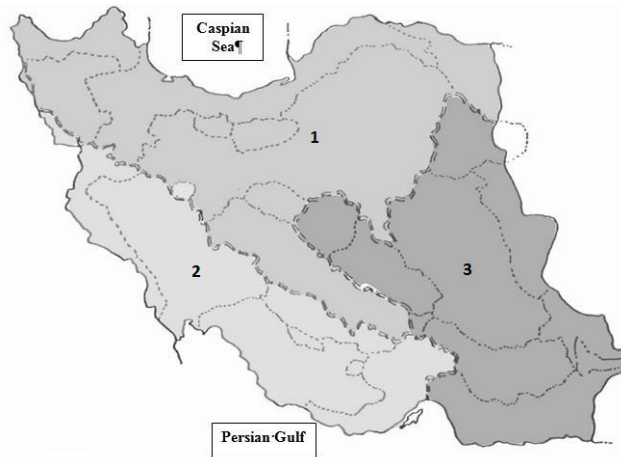


Figure 1. Iranian freshwater fishes' fauna regions; 1: Ponto-Caspian Territory, 2: Mesopotamian Intermediate Fauna Region, 3: Indian Fauna Region (Pazooki and Masoumian,2012)

Barbus capito in Kiar and Behesht Abad Rivers in Chahar Mahal and Bakhtiari Basins. The importance of the identification of the parasites is that, on one hand, a large group of animals are studied and different kinds of parasites as infecting a host could be recognized and on the other hand, they can infect the farmed fish, as well.

Shapour River originates from Ranjan Spring and connects Sasan Spring in Tange Chowgan area and flows toward Bushehr. In Bushehr, this river touches Dalaki River and then finally joins Persian Gulf called Hilla River. Shapour River is very vital in Kazerun, providing this area's water which is consumed for agriculture. Seyyed Hossein Spring is located twenty-three kilometers away in Kazerun Road. The fish species in this river have nutritional value and are caught recreationally or for eating, thus recognizing their parasite gamut is very essential and this study has been carried out accordingly. This study, therefore, aimed at detecting the occurrence of parasites in fish in Shapour River and Seyyed Hossein Spring, Kazerun Province, with regard to the importance of native fish population in the river.

Material and Methods

Early morning, a total of 38 fish including kuli, Lotak, Siah mahi and Doctor fish were caught using gillnet and Sachuk Net and they were transferred alive to the Laboratory of Parasitology, Faculty of Veterinary Medicine, Islamic Azad University, Kazerun and were kept in the aquarium. The fish were anaesthetized using 170 ppm powder of *Eugenia* sp. (Rastiannasab et al., 2014). Immediately after anesthesia, they were identified based on recognition keys of Berg (1964), and Coad (1992). The methods and techniques used for collection, relaxation, fixation, staining and mounting of helminthes are basically those described by Hanek and Fernando (1972) and Roberts (2001). Fish were dissected for internal examination and studied for cysts and endoparasites in the muscles and visceral organs. Abdominal cavity of each fish was washed with a 0.6% saline solution for abdominal parasites.

Then the gastrointestinal tract was dissected for examination. Intestine cut open longitudinally, the contents were washed was removed, placed in a petri dish, and examined for helminthes using an Olympus SZ Series 51stereomicroscope. Nematodes were washed in saline (0.6%-0.8%) and fixed in hot 76% ethylalcohol and cleared in Glycerin or in hot lactophenol. For permanent preservation mounted on azocarmin stains. All Nematodes were identified. Using descriptions identification keys Yamaguti (1961), Gussev (1985) and Moravec (1994). Acanthocephalans were isolated from dissected Fish hosts then fixed in 70% ethanol then stained in Mayer's carmine or azocarmin. After staining, dehydrated in alcohol series, for clearing were placed in xylol and finally mounted in Canada balsam. Then the parasite was identified, according to morphological characteristics and followed the key to the families and subfamilies of Acanthocephala (Amin, 1987). All isolated nematodes and acanthocephalans specimens in each individual fish were identified and counted. In this study, the data were processed using SPSS 18 software. The frequency and Pearson Chi-Square test were used to compare the infection among different kinds of fish species and the infectious frequency and between sex and the infectious frequency.

Results

Totally, four internal parasites were isolated from the intestine , gall bladder ana air sac of four fish species caught in the river(Table 1). They were identified for their genus, including one Digene (*Haplorchis* sp., frequency 6.5 % and *Allocreadium* sp. frequency 48.8 %), one cestode (*Bothriocephalus* sp., frequency 12.9%), and one Nematode (*Rhabdochona* sp., frequency 32.3 %). Therefore as the results showed, *Allocreadium* sp. demonstrated the highest and *Haplorchis* sp. presented the lowest frequencies(**Diagram 2**). The highest infection was detected in kuli with 40 % frequency and the least infection was observed in Siah mahi with 10 percent frequency(**Diagram 1**). The average intensity of infection in Siah mahi with 0.33 ± 0.48 , Lotak with 0.4 ± 0.54 , kuli with 0.8 ± 0.42 and Doctor fish with $0.6 (\pm 0.54)$ was calculated (**Diagram 3**). Using Pearson Chi-Square test showed that no meaningful relationship was detected between fish species and frequency of infection($P > 0/05$). However there was significant relationship between sex and frequency of infection ($P \leq 0/05$).

Table 1. Isolated internal helminthes of the fish in Shapour River and Seyyed Hossein Spring based on the infected organ and its host

Parasite	Infected Organ	Fish Species
<i>Allocreadium sp.</i>	Intestine and Gall Bladder	<i>Capoeta barroisi persica</i>
<i>Haplorchis sp.</i>	Air sac	
<i>Rhabdochona sp.</i>	Intestine	<i>Albus mossulensis</i>
<i>Allocreadium sp.</i>		
<i>Bothriocephalus sp.</i>		
<i>Rhabdochona sp.</i>	Intestine and Gall Bladder	<i>Cyprinion macrostomum</i>
<i>Allocreadium sp.</i>		
<i>Haplorchis sp.</i>	Air sac	<i>Garra rufa</i>
<i>Rhabdochona sp.</i>	Intestine	
<i>Allocreadium sp.</i>		

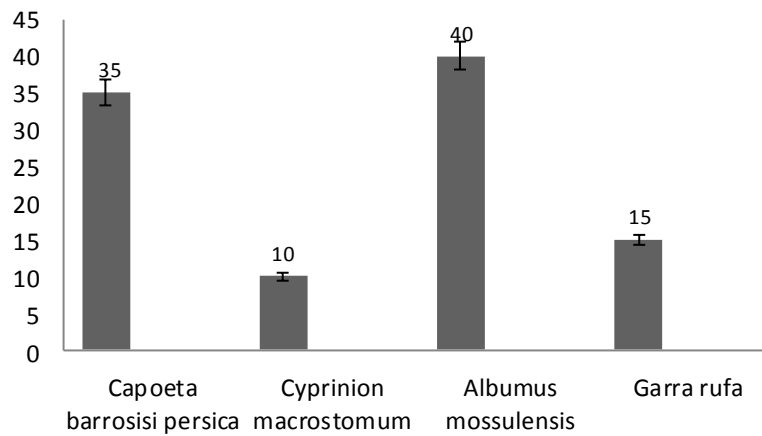


Diagram 1. Infection Percent of the Fish Caught in Shapour River and Seyyed Hossein Spring to internal helminthes

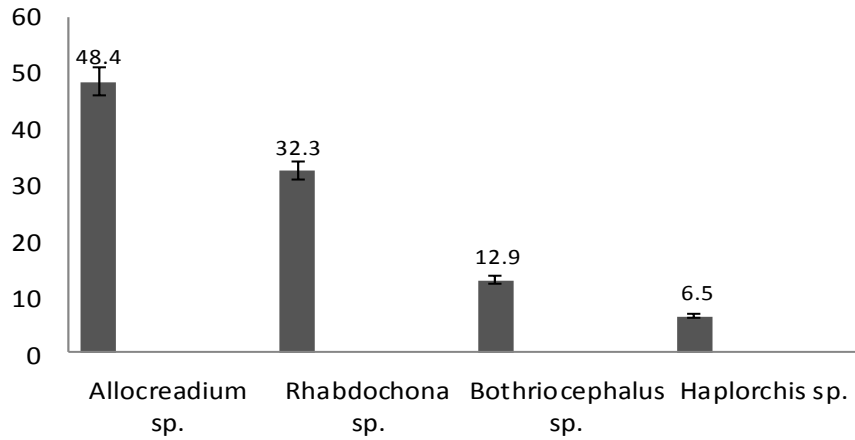


Diagram 2. Infection Frequency Percent of the Isolated Internal Helminthes of the Cyprinid Fish in Shapour River and Seyyed Hossein Spring

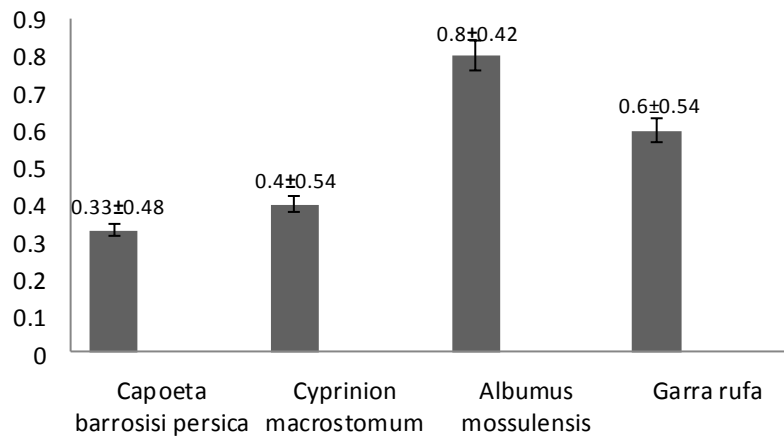


Diagram 3. The Average Intensity of the Infected Fish to Internal Helminthes in Four Studied Groups

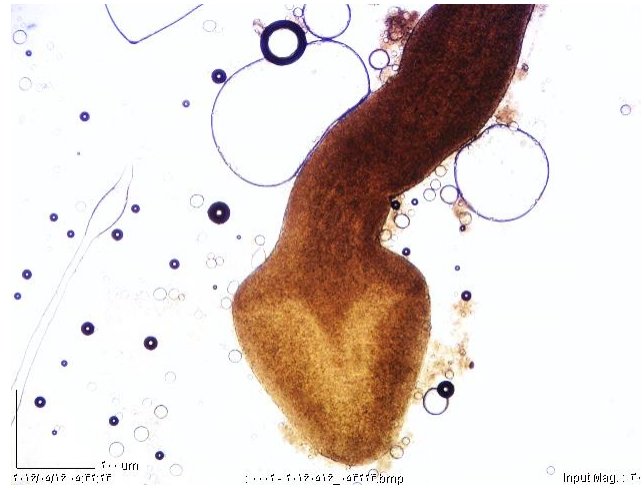

Figure 2. *Bothriocephalus* sp. ($\times 3000$)

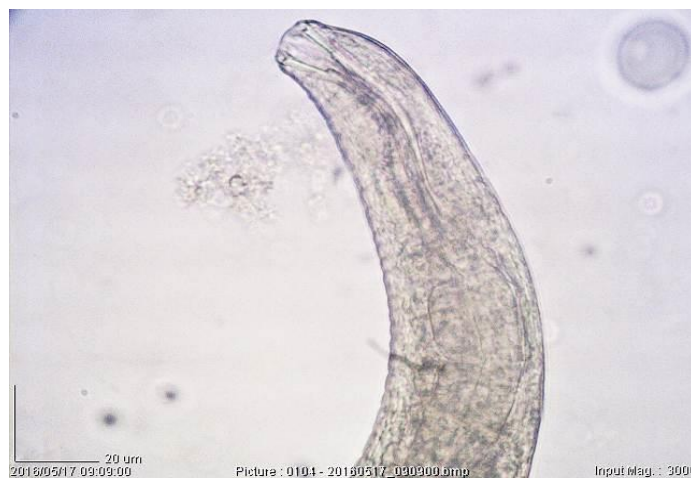

Figure 3. *Rhabdochona* sp. ($\times 3000$)

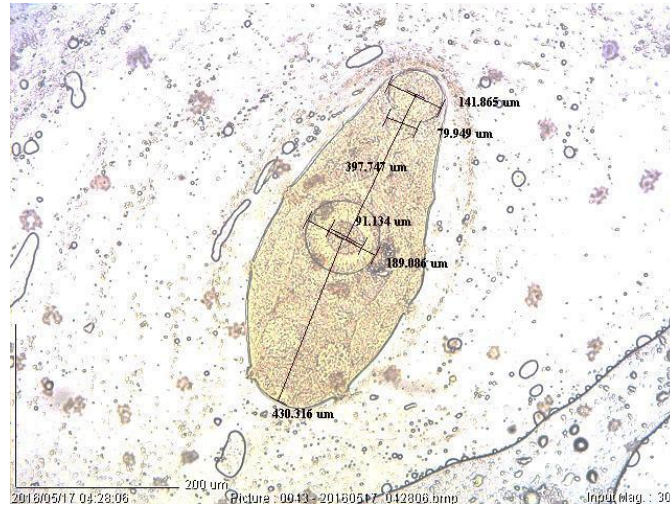


Figure 4. *Allocreadium* sp. ($\times 3000$)

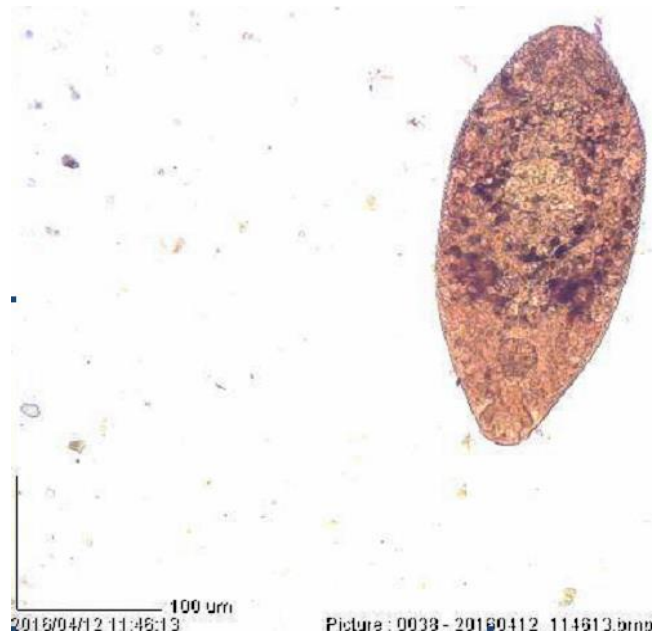

Figure 5. Metacercaria of the *Haplorchis* sp. ($\times 3000$)

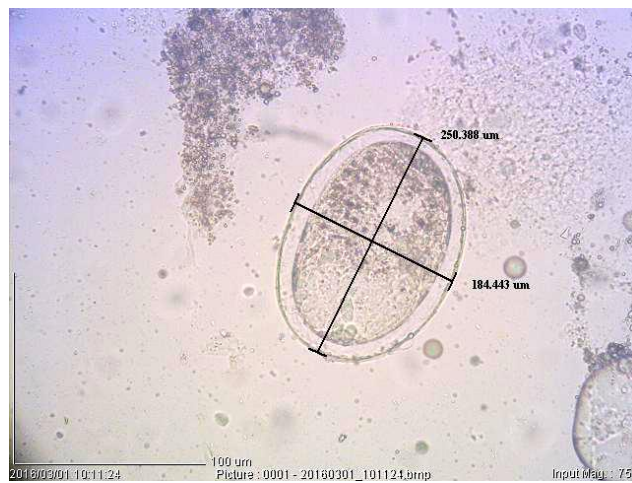


Figure 6. Cystic Stage of the *Haplorchis* sp. ($\times 3000$)

Discussion

Throughout the time, a balanced condition would be developed among parasites and the host in natural environments, but in high fish density in cultural and environmental stressful conditions, parasites would make many problems for the reproduction (Bush et al., 2001) and despite parasitic infection of the fish, no clinical signs of the disease were observed which confirm the balance of parasite and the host in natural environments. Aquaculture development in today's world and economy of various countries has an important role in the human food supply.

One of the main conditions for suitable production is fish health and prevents disease among them, including parasitic diseases that affect the behavior of fish growth and reduce marketable yields. So recognizing these factors is essential to eliminate or minimize these problems (Seyed Mortezaei et al., 2000). Among the large number of parasites recorded from different parts of the world, research on parasites in Iranian freshwater fish is very new. Many fish parasites from different parts of the country were expected, but only 247 species have been reported so far. The parasites, recorded from the Mesopotamian part of Iran, some new hosts were reported as well as some endemic and introduced species (Pazooki and Masoumian, 2012). During this study two Digenea, one Cestod, one Nematod were identified. *Allocreadium isoporum* has already been reported from the intestine of *Alburnoides bipunctatus* from the Gorgan Roud River (Jalali, 1998), *Leuciscus cephalus* from the Zayandeh Roud River (Williams et al., 1980) and *Allocreadium pseudaspis*, *barbulus barbulus* and *Capoeta damascina* (Raissy et al., 2011). This parasite may be pathogenic in cultured fishes (Woo, 2006). This study revealed that kuli, Lotak and Doctor fish, from Shapour River and Seyyed Hossein Spring were infected with *Rhabdochona* sp. which was originally described by Moravec (1994) from the intestine of *Varocorhinus capoeta* in freshwater in Azerbaijan. This parasite lives in intestine, liver, abdominal area, muscles and blood vessels and also was isolated by from *pike* and *Barbus spp.* (Eslami et al., 1972), *Chalcalburnus chalcoides* (Pazooki and Masoumain, 1999), *Silurus glanis* (Jalali, 1998), *Capoeta capoeta* from Freshwater Fishes of Northwest Iran (Pazooki et al., 2007) and was reported by Pazooki and Aghlmandi (2002), Syed Mortezaei et al. (2007) (*R. denudata* and *R. fortunatowi*) from Khuzestan, Raissy et al. (2011) (*Rhabdochona denudata*) from Armand River, Mohajeri et al. (2017) from Dalaki River. Among cestodes *Bothriocephalus* sp. was isolated from kuli, which this parasite has not been reported from mentioned fish until now. This cestode is the most dangerous warm water fish parasites that severe infection with the parasite causes intestinal obstruction or perforation it. Fortunately, the chemical treatment of contaminated fish can be fought to the cestode. However, due to the large Volume of water in the dam and the use of water as a source of drinking water can't action this affair (Jalali 1998). Also *Bothriocephalus* sp. was reported in many freshwater source such as: Mokhayer, 1981 from Sefid-Rood River; Masoumian et al. (2002); Raissy et al. (2011) from Armand River and Hosseinifard (2011) in Alborz dam. *Haplorchis* sp. was another internal parasite which isolated from air sac of Lotak and *Siah mahi*. The fish can be infected as the second host and this cycle is completed at the time that the fish are eaten by the final host including rats, penguins, birds and mammals and they become mature. Some human infections have also been reported by this parasite. For the first time, this parasite was detected in Asia (Chen, 1942) and later, it was reported in Mexico, Australia, Croatia and Turkey (Evans and Yildiz, 2005; Scholz and Salgado-Maldonado, 2000; Gjurcevic et al., 2007; Lester, 2001). Mood et al. (2010) identified this parasite in some imported aquarium fish. Recently Alamdari et al. (2017) reported it in the gill of Lotak and *Siah mahi* from Shapour River and Seyyed Hossein Spring.

Conclusion

The results showed that varieties of nematodes, ceatodes and trematodes were distributed in different ecosystems and climates, as well as in zoogeographic features of native fishes. It would be interesting to consider

parasites may survive in different climates. Between fish Kuli showed the highest percentage of infection whereas Lotak had the lowest infection frequency. Also *Haplorchis* sp. was reported for the first time from air sac of fresh water fish.

References

Abbasi K, Moradkhah S and Rahimi R.(2003). Identification and study of Black River fish distribution of Siah Darvishan Anzali Wetland, Bony fish research center of Khazar Sea. Research and development Magazine, 19(1):27-39.

Alamdari A, Golchin Manshadi AR, Tarahomi M.(2017). External Parasitic Worms and Protozoans of the Fish Caught in Shapour River and Seyyed Hossein Spring in Kazerun, Iran. Journal of Alternative Veterinary Medicine, 1(1):24-36.

Amin OM, Abdullah MAS and Mhaisen FT.(2003). Neoechinorhynchus (Neoechinorhynchus) *zabensis* sp. n. (Acanthocephala: Neoechinorhynchidae) from freshwater fish in northern Iraq. Folia parasitologica, 50: 293–297.

Barzegar M, Asadollah S, HemmatZadeh A, Jalali Jafari B and Rahnama R.(2004). Fish parasites of Behesht Abad River (Chahar Mahal and Bakhtiari Province). Journal of Comparative Pathology, 1(1): 67-74.

Berg LS. (1964). Freshwater Fishes of USSR and adjacent countries, Vol,3 (English version). Nauka, Mos, pp: 926-1382.

Bush OB, Ferandez JE, Esch GW and Seed JR.(2001). Parasitism, the diversity and ecology of animal parasites. Cambridge university press, p: 652.

Bychowsky BE.(1949). Monogenetic trematodes of some fish of Iran collected by E.N. Pavlowsky, Trudi Zoologicheskovo Instituta Akademiya, 8(4): 870-878.

Chen HT.(1942). The metacercaria and adult of *Centrocestus formosanus* (Nishigori, 1924) with notes on the natural infection of rats and cats with *C. armatus* (Tanabe, 1922). Journal of Parasitology, 28(2):285-98.

Coad BW.(1992). Freshwater Fishes of Iran. A checklist and bibliography Ichthyology Section. Canadian museum of Nature, Ottawa, Ontario, Canada, pp: 66-90.

Eslami A, Anvar M and Khatibi SH.(1972). Incidence and Intensity of Helmithoses in Pike (*Esox lucius*) of Caspian Sea (North of Iran). Riv. It. Piscic. Ittio. A., VII , 1: 32-41.

Evans BB and Lester RJG.(2001). Parasites of ornamental fish imported into Australia. Bulletin of the European Association of Fish Pathologists, 21(2):51-55.

Farahnak A, Mobedi I and Tabibi R.(2002). Fish anisakidae helminthes in Khuzestan province, South West of Iran. Iranian Journal of Public Health, 31(2): 129-132.

Fernando CH, Furtado JI, Gussev AV Kakong SA and Hanek AV.(1972). Methods for the study of fresh water fish parasites. University of Waterloo, Biology series, p: 76.

Gjurcevic E, Petrinc Z, Kozaric Z, Kuzir S, Gjurcevic Kantura V, Vucemilo M and Dzaja P.(2007). Metacercariae of *Centrocestus formosanus* in goldfish (*Carassius auratus* L.) imported into Croatia. Helminthologia, 44(4): 214-216.

Golchin Manshadi AR, Mashayekhi A, Tarahomi M.(2016). Identification of parasites in river fish Shapur Kazeroun, Fars, Journal of Paguhesh-Sazandegi, 113: 82-91.

Gussev AV.(1985). Parasitic metazoans (In Russian), In O.N. Bauer (ed); Key to the Parasites of freshwater fishes of the USSR. Vol. 3. Nauka, Leningrad..

Hosseinfard SM.(2011). *Bothriocephalus gowkongensis* in the *Neogobius fluviatilis* Fish of Alborz Dam from Iran. World J Fish Mar Sci , 3(3): 260–262

Jalali B.(1998). Freshwater fish parasites and parasitic diseases in Iran, 1st Edition, Deputy Proliferation and Aquaculture Fisheries Organization, Tehran, Iran, pp: 229-301.

Lom J and Dykova I.(1992). Protozoan parasites of fishes (developments in aquaculture and fisheries science), Elsevier Science, Amsterdam, P: 316 .

Masoumian M, Setareh J and Mokhayer B.(2002). Survey on parasitic infection of *Rutilus rutilus caspicus* from Southern part of Caspian Sea. Journal of Iranian Fisheries Sciences, (10)4. (in Persian).

Mokhayer B.(1981). Survey on parasites of fishes from Sefid-Rood River. Journal Faculty Veterinary Medicine. Tehran University, (36)4. (in Persian).

Mohajeri Borazjani J, Bagherpour A, Soleymani A, Mobedi I.(2017). Helminthes parasite Isolated from a cyprinid fish, (*Capoeta barroisi* (Lortet, 1894)) in Dalaki River, Boushehr province, Iran, Iranian Journal of Aquatic Animal Health, 3(1) 90-100

Mood SM, Ebrahimzadeh Mousavi HA, Mokhayer B, Ahmadi M, Soltani M and Sharifpour I.(2010). *Centrocestus formosanus* metacercarial infection of four ornamental fish species imported into Iran. Bulletin of the European Association of Fish Pathologists, 30(4):146-149.

Moravec F.(1994). Parasitic nematodes of fresh water fishes of Europe.Kluwes Academic Published. London, 473 Pp.

Pazooki J and Aghlmandi F.(2002). Pollution of *Vimba vimba persa* of Southern Caspian Sea to Trematode digen. Iranian Sci Fish J, 11(2):96.

Pazooki, J and Masoumian M.(1999). Nematodes from Freshwater Fishes of Guyilan and Mazandaran Provinces. Journal of Pajouhesh Sazandegi., 51: 93-99 (in Persian).

Pazooki J, Masoumian M, Yahyazadeh M and Abbasi J.(2007). Metazoan Parasites from Freshwater Fishes of Northwest Iran. Journal of Agricultural Sciences and Technology, 9:25-33.

Pazooki J, Masoumian M.(2012). Synopsis of the Parasites in Iranian Freshwater Fishes, Iranian Journal of Fisheries Sciences, 11(3) 570-589.

Raissy M, Ansari M, Jalali B.(2009). Identification of parasites of black fish in Kiar and Behesht Abad Rivers, Chahar Mahal Bakhtiari province, and the 1st report of *Lamproglena chinensis* in Iran. Veterinary Pathobiology, 1(1): 18-22.

Raissy M, Ansari M.(2011). Parasites of Some Freshwater Fish from Armand River, Chaharmahal va Bakhtyari Province, Iran, Iranian J Parasitol, 7(1) :73-79

Rastiannasab A, Hosseini SA, Sharif Rohani M, Gandomkar H, Nekoyiefard A and Gorjipour E.(2014). The control of recovery process with clove tree (*Eugenia caryophyllata*) in rainbow trout (*Oncorhynchus mykiss*). Iranian Journal of Fisheries Sciences, 23(1): 117-123.

Roberts RJ.(2001). Fish Pathology.U.K.:W.B.Saunders, 472P.

Scholz T and Salgado-Maldonado G.(2000). The introduction and dispersal of *Centrocestus formosanus* (Nishigori, 1924) (Digenea: Heterophyidae) in Mexico: A review. American Midland Naturalist,143: 185-200.

Seyed Mortezaei SR, Mobedi A, Farahnak A.(2000). Pollution of some fresh water fish to Helminth parasites in Khuzestan watershed. Iranian Sci Fish J, 9(1):25.

Seyed Mortezaei, S.R., Pazooki, J. and Masoumian M.(2007). Nematodes from fresh water fishes of Khuzestan province. Pajouhesh & Sazandegi , 77: 2-10. (in Prsian).

Williams JS, Gibson DL and Sadighian A.(1980). Some helminthes parasites of Iranian freshwater fishes. Journal of Natural History, 14: 685-699.

Woo PTK.(2006). Fish diseases and disorders, protozoan and metazoan parasites. CAB international, UK, pp: 32-245.

Yamaguti S.(1961). Systema halmithum, Vol. III, the Nematodes of Vertebrates, Part I, Interscience publishers.

Yildiz HA.(2005). Infection with metacercariae of *Centrocestus formosanus* (Trematoda:Heterophyidae) in ornamental fish imported into Turkey. Bulletin of the European Association of Fish Pathologists, 25(5):244-246.