

The Protective Effects of Alcoholic Ginger Extract on Histological Changes of Testis in Doxorubicin-Treated Wistar Rats

Juibar, F.¹; Mokhtari, M.^{1*}; Dianatipour, M.²; Shariati, M.¹

¹ Department of Biology, Kazerun Branch, Islamic Azad University, Kazerun, Iran; ² Department of Genetics, Faculty of Medicine, Shiraz University of Medical Sciences, Shiraz, Iran

* **Corresponding Author:** M. Mokhtari, Department of Biology, Kazerun Branch, Islamic Azad University, Kazerun, Iran, *Email:m.mokhtari246@yahoo.com*

(Received: June 17, 2017; Accepted: September 15, 2017)

Abstract

Doxorubicin (DOX) has a wide spread use in cancer chemotherapy and *Zingiber officinale* (ginger) has androgenic property and effects on fertility. The aim of the present study was to investigate the protective effects of Alcoholic extract of ginger on reproductive toxicity induced by DOX in male rats. In this experimental study, 56 adult Wistar male rats were randomly divided into 7 groups of 8. The extract was orally administered an hour after intraperitoneal injection of DOX. DOX injection was carried out once a week for four weeks. On the day 29, testes were removed, fixed, sectioned, stained and examined histologically by light microscope. According to the findings, DOX caused an increase in interstitial space and deformation of cells in DOX group. Conversely, the number of spermatids, and leydig cells were significantly ($p < 0.05$) decreased compared to the control group. Moreover, concomitant consumption of ginger alcoholic extract and DOX significantly ($p < 0.05$) improved the induced toxicity. It was concluded that ginger alcoholic extract could prevent DOX toxic effect on testicular structure and therefore improve male reproductive activities

Keywords: doxorubicin, *Zingiber officinale*, testis, rat

Introduction

In recent years, infertility and its related problems have become an important issue in couple's life (Ebisch, 2007). Failure in pregnancy has affected about 80 million people in the world (Vayena, 2002). Factors such as toxins and anticancer drugs also adversely affect spermatogenesis and thus, increase the prevalence of infertility (Badia, 2008).

Obviously, use of chemotherapeutic drugs can damage healthy tissues such as testes. Damage to testes, following anti-cancer chemotherapy, can lead to infertility. DOX, widely used in chemotherapy, decreases male fertility due to the induction of sperm apoptosis. In addition, DOX is an intracellular oxidative stress inducer, and can cause biochemical and physiological abnormalities that ultimately culminate in cytotoxicity.

Medicinal plants have attracted various fields to treat different diseases since they have diverse properties and fewer side effects and can replace chemical drugs. *Zingiber officinale* (ginger) is an edible plant, spice or herb. It belongs to *Zingiberaceae* family and is similar to the orchid. It is native to South Asia and widely grows in Indo-pak subcontinent, which is one of the largest ginger producing regions (Iwami, 2011). Fresh ginger contains 3.2% protein, 9.0% fat, 2.1% minerals, 4.2% fiber, 12.3% carbohydrate, and 9/80% moisture. Inorganic materials in ginger include iron, calcium, and phosphorus. Rhizome powder contains 3 to 6% oil, 9% protein, 60 to 70 percent carbohydrates, 3 to 8% fiber, 9 to 12% water, and 2 to 3% volatile oil. Also, various vitamins such as thiamin, riboflavin, niacin, and vitamin C are found in Ginger (Feng, 2011).

In traditional medicine, ginger is used in the treatment of various diseases such as rheumatism, fever, dementia, hypertension, vomiting, constipation, pain, infection, asthma, diabetes, etc. Apparently, it is anti-apoptotic, powerful antioxidant (to prevent free radical production), anti-inflammatory and sexual enhancer (Rehman, 2011). Moreover, ginger can be effective in antitumor, antioxidant, spermatogenesis, and libido enhancement therapies (Prasanna, 2007). Gingerols present in ginger are involved in destroying free radicals and are anti-serotonergic and inhibitors of prostaglandin production (Amin, 2006).

In a study by Khaki and some other researchers (2009), it was shown that serum testosterone levels were increased in the experimental group that received ginger (100 mg/kg/daily). His research showed that *Z. Officinale* seemed to confer a protective antioxidant defense capacity on the treated rats as evidenced by a significant reduction in the malondialdehyde (MDA) level. Ginger oil has a strong protective effect on DNA damage and can improve sperm quality and hence increase fertility rate in men (Memudu, 2017).

Kamtchouing and his colleagues (2000) examined possible androgenic effects of aqueous extract of ginger root. A daily dosage of ginger root extract (600 mg/kg) was administered orally to male Wistar rats for 28 consecutive days. It was shown that compared to control group, ginger root extract caused a significant increase in testicular weight, and it increased levels of testosterone and cholesterol in the testicles and α -glucosidase in the epididymis.

In a study, it was demonstrated that interperitoneal injection of DOX induced testicular weight loss, tubular atrophy, and a sharp decline in the number of sexual cells in rats (Manabe et al., 1997). It has been revealed that in addition to impairing spermatogenesis and reducing sperm count, DOX could increase oxidative stress and reduce antioxidant activity as well (Yeh et al., 2007).

In the present study, therefore, the effects of ginger as a powerful antioxidant and a booster of libido were examined on preventing or reducing DOX induced complications, including abnormalities in the structure and function of testes.

Materials and Methods

In this experimental study, 56 adult male Wistar rats weighing approximately 240 ± 10 g and about 3-4 months old were kept in standard laboratory conditions and exposed to a constant 12 hour light: 12 hour dark lighting schedule. The animals were housed in clear polypropylene cages lined with wood chip beddings. They were fed with standard pellet diet and water was made available at all times.

56 adult Wistar male rats were further randomly divided into 7 groups of 8: the control, the sham and experimental groups. The experimental group 1 received 3 mg/kg.bw DOX, experimental groups 2 and 3 received 500 and 1000 mg/kg. bw ginger extract, and experimental groups 4 and 5 received 500 and 1000 mg/kg extract+ 3 mg/kg DOX, respectively. All experimental procedures were done according to the guidelines of Animal Ethical Committee of National Research Center (Abdel-Aal, 2013).

Z. Officinale rhizome was purchased from local commercial sources and was identified by the Herbarium of Shiraz University with 24999 Herbarium number, and shade dried at room temperature before being pulverized with an electric grinder. To prepare ginger alcoholic extract, fine powder (100 g) was homogenized in ethanol (95%; 500 mL) and left in a conical flask at room temperature for 3 days. The mixture was then filtered through filter paper (Whatman No. 1). Using the rotary evaporator (Sigma-Aldrich, USA) the extract became concentrated. Tween-20 (10%) was used to dissolve the extract in the concentrations of 500 mg/mL and 1000 mg/mL (Bardi, 2013). The extract was gavaged orally from the first day, an hour after doxorubicin (Ebewe Pharma companies) injection for four weeks. DOX was administered intraperitoneally once a week at the concentration of 3mg/kg.bw (Hou, 2005).

At the end of the treatment period, animals were ethically anesthetized by ether using cotton soaked to ether in the anesthesia jar. Rats testes were removed, washed in saline, and fixed in 10% formalin. Then, they were processed to form paraffin block and sectioned at 5 microns to prepare tissue slides, which stained with hematoxylin and eosin (H & E) and examined under a light microscope with $100 \times$. Cell counts were randomly conducted in three slides of each sample and six tubules per slide. Also, 100 seminal tubes were considered in each sample.

In this research the effects of doxorubicin and alcoholic extract of ginger were studied on the number of spermatogonia, spermatocytes, spermatides, sertoli and leydig cells.

Statistical Analysis

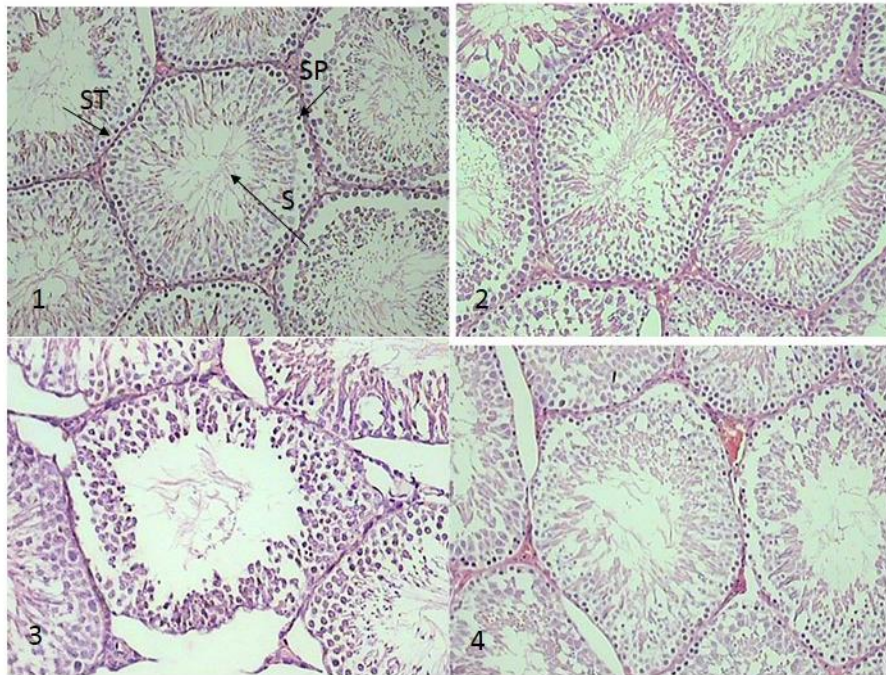
Data were analyzed using SPSS (Version 17.0) for Windows. ANOVA test was used to determine the differences between the groups. The level of statistical significance was set at $p < 0.05$.

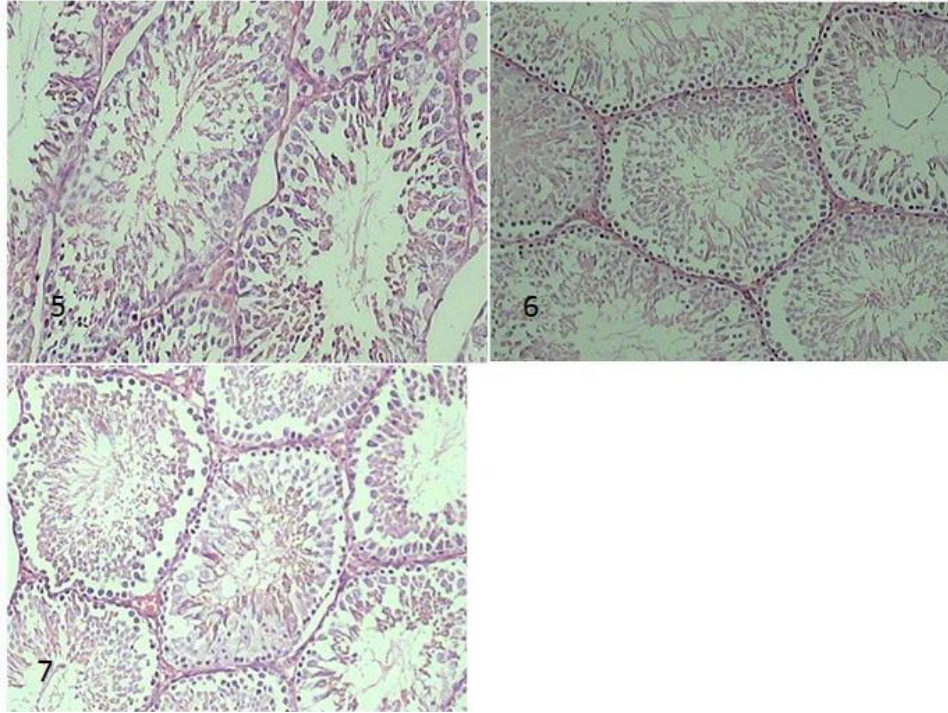
Results

Seminiferous tubules were regularly compressed and their cells were more diverse and numerous in the control, sham (Figures 1 and 2) and experimental groups 2 and 3 (recipient of ginger extract) (Figures 4 and 5). In addition, the nucleus of sertoli cells was located at the bases of seminiferous tubules. However compared to the

control group, in the group treated with DOX (experimental group 1) the space between tubules was increased, abnormalities were observed in the majority of them, and their lumen contained very few sperms (Figure 3). In the experimental group 5 (ginger extract and DOX), relative to experimental group 1 (DOX), tubular epithelium was thicker, cells were more cohesive, no empty space was observed between them, cell diversity was higher in the tubules, and lumen space contained a normal number of sperms (Figures 6 and 7).

The number of spermatogonia was also examined. Table 1 shows the changes in the number of spermatogonia, spermatocytes, and spermatids in the testes of different groups receiving ginger extract and DOX. The number of spermatids in the experimental group 1 (DOX) compared to the control group showed a significant decrease while a significant increase was observed in the experimental groups 4 and 5 relative to the experimental group 1. Moreover, administration of DOX significantly reduced leydig cells compared to the untreated control group. However, the number of leydig cells was significantly increased in the experimental groups 4 and 5 relative to the experimental group 1 (Table 1). Furthermore, no significant changes were observed in the number of sertoli cells, spermatogonia and primary spermatocytes in any of the groups.





Figures 1 and 2. The cross section of rat testes in control and sham groups showing seminiferous tubules (ST), spermatogonia (Sp), spermatozoa (S), (H&E, X 400).

Figure 3. Seminiferous tubules of a rat treated with DOX for 4 weeks showing irregular basement membrane (BM), less compact spermatogenic cells separated by vacuoles (*), cytoplasmic vacuolization in spermatogonia (arrow), degenerated tubule (DT), and degenerated inter-tubular connective tissue (IT), (H&E, X 400).

Figures 4 and 5. The cross section of a rat testis treated with ginger extract (500 and 1000mg/kg) for 4 weeks.

Figures 6 and 7. The cross section of a rat testis treated with DOX + ginger extract (500 and 1000 mg/kg) for 4 weeks showing seminiferous tubules with compact spermatogenic cells, and nearly normal Leydig cells (H&E, X 400)

Table 1. The effects of DOX and alcoholic extract of ginger on the number of spermatogonia, spermatocytes, spermatides, sertoli and leydig cells (the values are based on the \pm mean SEM)

	Number	Sertoli cells	Leydig cells	Spermatides cells	Spermatocytes cells	Spermatogonia cells
control	8	14.20 \pm 0.86	17.20 \pm 0.58	148.40 \pm 30	71.20 \pm 1.71	55.20 \pm 1.07
Sham	8	14.00 \pm 0.54	17.00 \pm 0.83	152.40 \pm 13.78	73.80 \pm 1.52	57.40 \pm 2.94
group 1: receiving 3 mg/kg.bw DOX,	8	12.50 \pm 0.71	11.83 \pm 0.48 ab	64.00 \pm 3.61 ab	61.66 \pm 1.08	47.00 \pm 2.02
groups 2: 500 mg/kg.bw ginger extract,	8	13.60 \pm 0.50	18.00 \pm 0.44	154.40 \pm 8.37	71.60 \pm 4.08	57.60 \pm 4.22
groups 2: 1000 mg/kg.bw ginger extract,	8	14.00 \pm 0.44	18.60 \pm 0.50	164.80 \pm 2.49	72.66 \pm 4.73	59.20 \pm 2.05
groups 4: 500 mg/kg extract + 3 mg/kg DOX	8	13.20 \pm 0.66	13.20 \pm 0.58 c	99.00 \pm 8.85 c	68.00 \pm 4.88	47.80 \pm 3.61
groups 5: 1000 mg/kg extract + 3 mg/kg DOX	8	13.60 \pm 0.50	15.00 \pm 0.54 c	119.40 \pm 1.43 c	70.40 \pm 3.90	48.80 \pm 5.30

a: There are significant difference among the groups compared to the control group.

b: There are significant differences among the groups compared to the sham group.

c: There are significant differences among the groups compared to the DOX group.

Discussion

DOX, a known anticancer drug, is an anthracycline antibiotic produced by the fungus streptomyces peucetius (Vendramini, 2010). Many reports have shown that DOX can cause long and short term male infertility (Manabe et al., 1997). It is also known as an apoptotic drug (Speth, 1998). It is involved in the inhibition of some nuclear proteins such as DNA and RNA polymerase as well as DNA-topoisimeras II (Shinoda, 1999).

The use of DOX causes a significant reduction in the number of spermatogonia (A and B types). Although spermatogonia are not the only sperm producing cell type under continuous division, its location at the base of epithelium makes them more vulnerable to cytotoxic drugs (Van-Keulen and de Rooij, 1975). Similarly, the results of the present study indicate that treatment of rats with DOX induces a significant reduction in the number of spermatids (Table 1). The histological findings of other researchers show that cellular toxicity of DOX causes the production of round spermatids and apoptosis of multinucleated cells (Speth, 1998). In addition, a study by Hou (2005) on the impact of anthracycline chemotherapy on the number of spermatogenic cells indicated that DOX increases the number of apoptotic sexual cells with several folds. Other studies also showed that DOX induces impairment of spermatogenesis and decreases sperm counts along with an elevation in apoptotic parameters (Yeh et al., 2007). The degenerative effect of compounds used as anti-cancer drugs is more exerted on cells that have rapid

RNA synthesis (spermatocysts) and undergo meiotic Division (Parvinen, 1989). Hence, administration of DOX can lead to the loss of immature dividing sex cells and ultimately spermatozooids (Vendramini, 2010).

Unlike the study by Shinoda (1999) that showed a reduction in the number of spermatogonia following the administration of DOX, no such decrease was observed in the present study (Table 1). In addition, some other reports indicated that exposure to high doses of this drug was unable to destroy all spermatogonia (Aich and Manna, 2001).

In a mature testis, sertoli cells make up about 3% of all cells present in seminiferous tubules; they are the only somatic cells of tubules. According to our results, administration of Dox induces atrophy and morphological changes in sertoli cells, but their numbers show no significant reduction (Table 1). This finding can be an indication of their resistance, which is in agreement with the results of other studies (Takahashi, 2011). Moreover, Hou (2005) observed that 9 weeks after the treatment of male rats with DOX, the only remaining cells in the narrow tubules were sertoli cells. Nonetheless, others in vivo and in vitro studies have shown a significant decline in the number of sertoli cells under the influence of DOX (Shinoda, 1999). Inconsistency in these findings could be the result of the differences between the factors such as drug doses and time relapse following drug administration.

Integration of DOX in the DNA of germinative cells during cell division is considered as the main cause of inducing apoptosis in the sperm producing epithelium (Brilhante, 2011).

In the present study, the use of DOX significantly reduced the number of leydig cells (Table 1). This finding is in agreement with other reports indicating that anti-cancer drugs can adversely affect leydig cells leading to a reduction in number as well as abnormal maturity (Al-hazmi, 2005). This could be another explanation for the failure of spermatogenesis under the influence of DOX, because a decline in the number of leydig cells leads to testosterone reduction. This hormonal imbalance disrupts testosterone-dependent attachment of round spermatids to sertoli cells and thus, the maturity of spermatozooids is impaired (Benahmad, 2004).

Moreover, there are reports indicating that leydig cells function as targets of various factors including vasopressin, interleukin and IGF-1 as well as sertoli cell activator. Hence, the destruction of leydig cells interferes both with secretion of testosterone (the most important sex hormone) as well as many other functions of testes (Howell, 1999).

Relative to other germinal cells of testis, leydig Cells are more resistant to toxic factors. Damage to these cells usually occurs after the destruction of germinal epithelium. The mechanism of leydig cell damage after chemotherapy is not clearly understood. It may occur directly, but there are some evidence indicating that damage to germinal epithelium, reduction in blood flow to testes and changes in paracrine control of leydig cells indirectly induce their damage (Cao, 2004).

Vendramini and his colleagues (2010) revealed that 30 and 60 day administration of DOX could reduce the percentage of tubule differentiation in rats. As a result of atrophy and a decline in the number of leydig cells, the level of testosterone secretion was decreased culminating in spermiogenesis disruption (Lindi, 2005). It appeared that oxidative effects of anti-cancer drugs impaired leydig cells (Ali, 2008),

Some studies demonstrate that ginger contains flavonoids, alkaloids, coumarins, saponins, tannin, alkaloid, and glycosides with antioxidant effects (Lin, 2010). However, according to the results of this study, ginger extract, as a powerful antioxidant, can protect cells against DOX oxidative damage and improve the histological and morphological parameters of testes.

Conclusion

Following chemotherapy, fertility disorders are clinically important. This study showed that the anti-cancer drug, DOX, reduced testicular germinal cells in male rats, and the concomitant use of ginger extract, as an antioxidant agent with high protective properties, could compensate cell reduction and improve testicular tissue parameters. Such encouraging results can inspire more comprehensive studies with different doses and time periods targeting the final treatment of infertility disorders caused by chemotherapy in men.

References

- Abdel-Aal, W.I., Ghaffar, E.A., El., Shabrawy, O. (2013). Review of the Medical Research Ethics Committee (MREC), National Research Center of Egypt, 2003-2011. *Curr Med Res Opin.*, 29:1411-7.
- Aich, S, Manna, C.K. (2001). Histophysiological changes of the testicular tissue due to busulphan administration in the wild Indian house rat. *ActaBiol Hung*, 52:105-116.
- Al-hazmi, E., Shaker, S., Al-sagaff, S., Koraium, S. (2005). Histological changes of testis in mice after administration of Doxorubicin HCL (Adriblastina) cytotoxic drug. *Proc 2 nd Saudi Siconf*, 1425: 99-117.
- Amin, A., Hamza, A.A. (2006). Effects of Roselle and Ginger on cisplatin-induced reproductive toxicity in rats. *Asian J Androl*, 8:607-12.
- Badia, R., Iborra, A., Palacio, J.R., Antich, M., Martínez, P. (2008). The effect of oxidative environment on immunosuppressive properties of human seminal plasma. *Am J Reprod Immunol*, 60:354-60.
- Bardi, D., Halabi, M., Abdullah, N., Rouhollahi, E., Hajrezaie, M. (2013). In Vivo Evaluation of Ethanolic Extract of Zingiberofficinale Rhizomes for Its Protective Effect against Liver Cirrhosis, *Biomed Research International*. Article ID 918460, doi.org/10.1155/2013/918460.
- Benahmad, M.E., Tabone, J., Zaes, J.M. (2004). Role of sertoli cells in leydig cell function. *Inserm colloqu*. 123: 363-385.
- Brilhante, O., Stumpp, T., Miraglia, S.M. (2011). Long-term testicular toxicity caused by doxorubicin treatment during pre-pubertal phase. *Int J Medicine and Medical Sciences*, 3: 52-60
- Cao, L., Leers-Sucheta, S., Azhar, S. (2004). Aging alters the functional expression of enzymatic and non-enzymatic anti-oxidant defense systems in testicular rat Leydig cells. *J Steroid biochemmol Biol*, 88: 61-7.
- Ebisch, I.M., Thomas, C.M., Peters, W.H., Braat, D.D., Steegers-Theunissen, R.P. (2007). The importance of folate, zinc and antioxidants in the pathogenesis and prevention of subfertility. *J Hum Reprod Update*, 13: 163-74.
- Feng, T., Su, J., Ding, Z.H., Zheng, Y.T., Li, Y. (2011). Chemical constituents and their bioactivities of "tongling White Ginger" (Zingiberofficinale) *Agric. Food Chem.*, 59: 11690–11695.

- Hou, M., Chrysis, D., Nurmio, M., Parvinen, M., Eksborg, S., Söder, O., Jahnukainen, K. (2005). Doxorubicin Induces Apoptosis in Germ Line Stem Cells in the Immature Rat Testis and Amifostine Cannot Protect against This Cytotoxicity. *Cancer Res.*, 65: 9999-10005.
- Howell, S.J., Radford, J.A., Ryder, W.D.J., Shalet, S.M. (1999). Testicular Function after Cytotoxic Chemotherapy: Evidence of Leydig Cell Insufficiency. *J Clinical Oncology*, 17:1493-1498.
- Iwami, M., Shiina, T., Hirayama, H., Shima, T. (2011). Inhibitory effects of zingerone, a pungent component of *Zingiber officinale* Roscoe, on colonic motility in rats. *Journal of Natural Medicines*, 65: 89-94.
- Kamtchouing, P., Mbongue-Famodio, G.Y., Dimo, T., Jasta, H.B. (2000). Evaluation of androgenic activity of *Zingiber officinale* and *Pentadiplandra brazzeana* in male. *Asian J. Androl*, 4: 299-301.
- Khaki, A., Fathiadzad, F., Nouri, M., Khaki, A.A., Ozanci, C., Ghafari-Novin, M., Hamadeh, M. (2009). The effects of Ginger on spermatogenesis and sperm parameters of rat. *Iranian Journal of Reproductive Medicine*, 7: 7-12.
- Lin, R., Chen, C., Chung, Y., Yena, C. (2010). Larvicidal activities of ginger (*Zingiber officinale*) against *Angiostrongylus cantonensis*. *Acta Tropica*, 115: 69-76.
- Lindi, L., Haolin, C., Michael, A., Trush, M.D., Show, M., Anway, M., Zirkin, B. (2005). Aging and the Brown Norway Rat Leydig Cell Antioxidant Defense System. *J Androl*, 22: 32-37.
- Manabe, F., Takeshima, H., Akaza, H. (1997). Protecting Spermatogenesis from Damage Induced by Doxorubicin Using the Luteinizing Hormone-Releasing Hormone Agonist Leuporelin: An Image Analysis Study of a Rat Experimental Model. *Cancer*, 79: 1014-21.
- Memudu, A.E., Akinrinade, I.D., Ogundele, O.M., Duru, F. (2017). Investigation of the androgenic activity of ginger (*Zingiber officinale*) on the histology of the testis of adult *sparaguedawley* rats. *Journal of Medicine and Medical Sciences*, 3: 697-702.
- Prasanna, K., Kalpagam, P., Nirmala, K. (2007). Alterations in antioxidant status of rats following intake of ginger through diet. *Foodchem*, 106:991-996.
- Rehman, R., Akram, M., Akhtar, N., Shaheen, G.H., Asif, H. (2011). *Zingiber officinale* Roscoe (pharmacological activity). *Journal of medicinal plants research*, 5: 344-348.
- Shinoda, K., Mitsumori, K., Yasuhara, K., Uneyama, C., Onodera, H., Hirose, M., Uehara, M. (1999). Doxorubicin induces male germ cell apoptosis in rats. *Arch Toxicol*, 73: 274-281.
- Speth, P.A.J., Van-Hoesel, QGCM., Haanen, C. (1988). Clinical pharmacokinetics of doxorubicin. *ClizPharmakinet*, 15: 15-31.
- Takahashi H., Tainakav, H., Umezawa, M., Takeda, K. (2011). Evaluation of testicular toxicology of doxorubicin based on microarray analysis of testicular specific gene expression. *J Toxicol sciences*, 36 : 559-567.
- Van-Keulen, C.J., de Rooij, D.G. (1975). Spermatogenic clones developing from repopulating stem cells surviving a high dose of an alkylating agent. *Cell Tissue Kinet*, 8: 543-51.
- Vayena, E. (2002). Current practices and controversies in assisted reproduction: report of a meeting on "Medical, ethical and social aspects of assisted reproduction" held at WHO headquarters in Geneva. Switzerland, World Health Organization.
- Vendramini, V., Sasso-Cerri, E., Miraglia, S.M. (2010). Amifostine reduces the seminiferous epithelium damage in doxorubicin-treated prepubertal rats without improving the fertility status. *Reprod Biol and Endocrin*, 8: 15-21

Yeh, Y., Lai, H., Ting, C., Lee, W., Wang, L.C., Wang, K.Y., Lai, H.C., Liu, T.J. (2007). Protection by doxycycline against doxorubicin-induced oxidative stress and apoptosis in mouse testes. *Biochempharmacol*, 7: 969-980.