

Radiographic evaluation of hoof parameters related to laminitis in clinically normal Dareh-shori horse

Vali, R.^{1*} and Ahmadi Rahnemon, A.²

¹Department of Clinical Sciences, School of Veterinary Medicine, Kazerun Branch, Islamic Azad University, Kazerun, Iran; ²Graduated of Faculty of Veterinary Medicine, Kazerun Branch, Islamic Azad University, Kazerun, Iran

Corresponding author: R. Vali, Department of Clinical Sciences, Faculty of Veterinary Medicine, Kazerun Branch, Islamic Azad University, Kazerun, Iran, Email: Rohamvali@gmail.com

(Received: March 29, 2017; Accepted: June 15, 2017)

Abstract

Radiography is traditionally regarded as an important part of the subjective routine foot examination in equine lameness. Laminitis is a major disease in horses due to the associated pain and debilitating nature that make it a life-threatening condition. This study was therefore conducted to estimate radiological factors which refer to anterior motor limb. Measurements were taken from 10 healthy Dareh-shori horses. After cleaning and washing the horses' hooves, metal marker placement, the hooves were marked by the contrast, then hand-made block placed under the following limb, both front feet were radiographed with the limb in vertical position. The obtained measurements and values in this study were as: Founder Distance = 5.7 ± 2.01 mm; Hoof wall thickness = 16.9 ± 1.06 mm, PCL = 59.9 ± 5.8 mm; HWT/PCL% = 28.4 ± 3.6 mm. Values for angles: Hoof axis = 49.9 ± 2.8 ; P3 axis = 48.7 ± 2.8 ; H angle = 1.58 ± 2.29 ; P2 axis = 46.3 ± 3.3 ; R angle = 1.7 ± 3.6 . Measurements of this study may be different from those reported in other breeds, so it can be used as reference values for diagnosis of laminitis and founder in front feet of Dareh-shori horses.

Key words: Radiographic Evaluation, Hoof parameters, Dareh-shori horses, Laminitis

Introduction

Darreh-shori horse is one of the indigenous Persian (Persian-Arabic) horses. This horse is recognized as one of the best races for free horse-riding and long-distance races. Many researchers have described the normal radiographic anatomy of the front feet of normal horses (Butler et al., 1993; Quick and Rendano, 1977; Rendano and Grant, 1978; Shively, 1977). Laminitis causes pathological changes to the anatomy of the foot and leads to a devastating loss of function. In the foot of the normal horse or pony, the hoof wall and the pedal (coffin) bone are joined together by a finely structured tissue called the laminae. Surprisingly, and despite being able to withstand enormous forces under normal circumstances, these laminae are relatively delicate and easily damaged. In the condition known as laminitis, the laminae become inflamed and extremely painful. The attachment between the hoof and the pedal bone fails which allows the pedal bone to be pushed down into the hoof capsule, crushing arteries, veins and other delicate structures, resulting in pain (Stashak, 2002). Laminitis can occur in all shapes and sizes of horses and ponies, though it is more commonly seen in small, overweight native ponies (Rendano and Grant, 1978).

Most frequently, laminitis will occur in both front feet which is logical given that horses bear approximately 60% of their weight on their front limbs (Baxter, 1995; Hood et al., 2002). However, it can occur in just one foot, as well as in all four feet or just both hinds (Vali and Zakipour, 2015).

Lateromedial radiographs should be taken at the first sign of acute laminitis to develop a baseline for continuous radiographic comparison. Early radiographic signs in laminitis include mild bony reaction along the dorsal aspect of the distal phalanx in addition to widening the distance between the distal phalanx and the dorsal hoof wall (Stashak, 2002). This distance should be less than 18 mm in normal horses or less than 30% of the palmar length of the distal phalanx measured from the tip of the bone to its articulation with the navicular bone (Linford et al., 1993). Palmar or plantar rotation of the distal phalanx away from the dorsal hoof wall confirms the diagnosis of laminitis (Cripps and Eustace, 1993; Redden, 2003; Stick et al., 1982). This study was an attempt to measure the distances and angles in order to establish a database of normal values in Dareh-shori horses to be compared to the results of other reports.

Materials and methods

Fifteen apparently healthy Dareh-Shori horses with the mean age 8.5 years and the mean height of 150.8 cm were used in this study. All the horses had no previous history of lameness, they were all clinically sound, and the feet showed no abnormality or distortion. The sole and wall were cleaned using a hoof pick and wire brush. The horn on the dorsal part of the hoof just below the coronary band was lightly rasped to remove rough perioplic horn. The proximo-dorsal hoof wall was palpated just below the coronary band and the point at which the wall horn began to yield to moderate digital pressure was marked with an indelible pen. A straight stiff wire marker, of known length (20 mm), was taped to the dorsal hoof wall with the proximal end at the indelible pen line. The horses' feet were radiographed standing on a flat wooden block 70 mm thick incorporating a metal ground line. Both front feet were radiographed with the limb in vertical position. Radiographs were made using a portable X- ray unit with 5MAS, 80 kVP exposure factors.

Radiographic measurements

Radiographs were fixed onto a horizontal viewing box and lines were drawn with a fine tipped pen. Following measurements were made from each latero-medial radiograph (Figure1).

- 1) Angle S: the angle between the dorsal hoof wall and the ground.
- 2) Angle T: the angle between the dorsal cortex of the distal phalanx and the ground.
- 3) Angle U: the angle between a line connecting the centers of curvature of the proximal and distal interphalangeal joints and the ground.
- 4) Angle H: Angle T minus Angle S.
- 5) Angle R: Angle T minus Angle U.

- 6) Distance between two horizontal lines through the hairline and the top of extensor process of P3 (D-founder), after correcting for magnification according to the M.C.F formula.
- 7) The thickness of hoof wall and under beneath soft tissues in place: Middle (STTM), and length of palmarcortical of p3 (PCL) after correction for magnification according to the M.C.F formula.
- 8) The thicknesses of hoof wall in the percent of length of palmarcortical of third phalanx.
- M.C.F= Actual length of marker / radiographic length of marker so the true distance = length measured radiographically x M.C.F

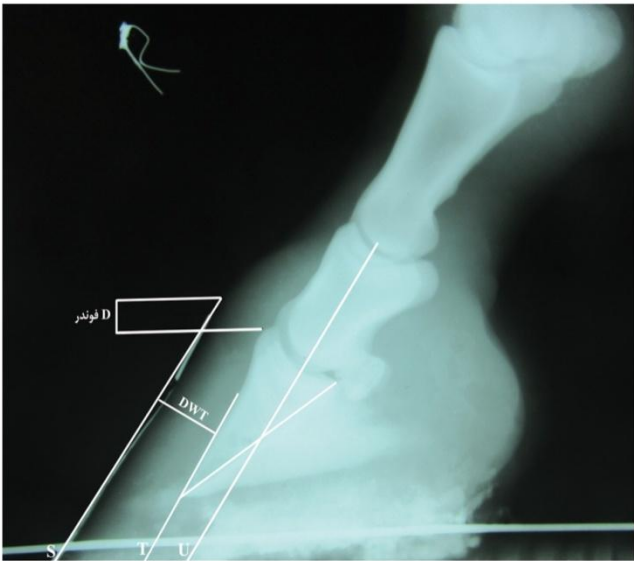


Figure 1. Lateromedial radiograph from the front feet of a normal horse, indicating the measured parameters (Angles & Distances)
Parameters: DWT = Dorsal wall thickness
FD = Founder Distance

Results

Tables 1 and 2 summarize the results of measurements including distances and angles in lateromedial radiographs from the front feet of all horses that describe the position of P3 in relation to the hoof capsule. In this study, no significant differences were found between left and right feet.

Table 1. Radiographic measurements of distances from the front feet of 10 normal Dareh-shori horses

Parameter	Mean	SD	Min	Max
DWT (mm)	16.9	1.06	13.3	19.09
PCL (mm)	59.9	5.8	50	70
DWT/PCL×100	28.2	4.2	21.7	37.2
FD (mm)	5.7	2.01	0.7	9.8

Table 2. Radiographic measurements of Angles from the front feet of 10 normal Dareh-shori horses

Parameter	Mean	SD	Min	Max
Angle S	49.9	2.8	41	56
Angle T	48.7	2.8	36	53
Angle U	46.3	3.3	37	58
Angle H(T-S)	-1.58	2.29	-8	5
Angle R(T-U)	1.7	3.6	-11	14

Table 3. compares the results of the present study to that of Cripps et al. (1999).

Table 3. Morphometric comparison between Cripps & Eustace and this study		
parameter	Cripps & Eustace 1999	This study
Angle S	48.6±3.51	49.9±2.8
Angle T	47.6±2.09	48.7±2.8
Angle U	43.8±5.86	46.3±3.3
Angle H	-1±2.72	-1.58±2.29
Angle R	3.8±6.46	1.7±3.6
Wall Thickness (mm)	16.3±1.75	16.9±1.06
FD(mm)	5.2±1.97	5.7±2.01

Discussion

Many studies have been conducted on measurement of coffin bone in front feet (Baxter, 1994; Cripps and Eustace, 1993; Eustace and Cripps, 1999; Cripps and Eustace, 1999; Kummer et al., 2006; Linford et al., 1993). Some other studies have been carried out on hind feet (Cripps and Eustace, 1999; Vali and Zakipour, 2015; Shahraki and Vali, 2015). Cripps et al. measured the angles in front feet of mix breeds. These researchers found that the mean angle S and T in the front feet of 22 thoroughbred horses were 48.6 and 47.6 degrees, respectively, while the H angle was -1 degree.

The measurement of these parameters in the present study was in close agreement with that of Cripps et al. (Cripps and Eustace, 1999). They reported that Angle U was 43.8 degree, while R angle was 3.8 degree (Cripps and Eustace, 1999). However, the findings obtained in this study were different from Cripps' results. In the present study, the value for angle U and R were 46.3 and 1.7 degrees, respectively. The variations between the two studies may be related to the breed or type of horses. Differences in measurement techniques may also have contributed to these variations as well (Cripps and Eustace, 1999; Kummer et al., 2004).

The measurement values of wall thickness in this study and those reported by Cripps et al. were in close agreement (Cripps and Eustace, 1999). According to Cripps et al. (1999), the mean wall thickness measurements from front feet of normal thoroughbred horses were 16.3 mm (Cripps and Eustace, 1999). In the current study, the mean wall thickness was 16.9 mm (STTM). Wall thickness in the normal horse is less than 30% (25-30) of PCL (Linford et al., 1993). In this study, the results were 28.2±4.2 in middle region of hoof wall. Table 3 demonstrates a morphometric comparison between the results of the present study and that of Cripps and Eustace (1999).

Founder distance is a parameter first described by Cripps and Eustace (1999). According to Cripps and Eustace method, the measurements in this study were based on a marker with the most proximal end at the point below the coronary band, where the wall horn began to yield to moderate digital pressure (Cripps and Eustace, 1999). In another study the marker was positioned with the proximal end at the hairline (Kummer et al., 2006). The different position of the marker explains the differences of measurements. Cripps et al. reported that FD values in front feet of 22 thoroughbred horses were about 5.2±1.97 mm (Cripps and Eustace, 1999). In our study founder distance was

about 5.7 ± 2.01 mm. The differences between left and right feet were not statistically significant ($P > 0.05$). Generally, the differences in FD (apart from the effect of marker placement) may be due to variations in limb loading, or as a consequence of laminitis. However, the degree of natural variation indicates that this parameter is only of limited usefulness in the early stages of laminitis (Cripps and Eustace, 1999; Linford et al., 1993).

References

Baxter G.M. Acute laminitis. *Vet Clin North Am Equine Pract*, 1994; 3: 627-642.

Butler J.A., Colles C.M., Dyson S.J., Kold S.E. & Poulos W. Foot, Pastern and Fetlock. In: *Clinical Radiology of the Horse*. Blackwell Scientific Publications, Oxford, 1993; 26-27.

Cripps, P.J. and Eustace R.A. Radiological measurements from the feet of normal horses, with relevance to Laminitis. *J Equine Vet*, 1999; 31.5: 427-433.

Eustace, R.A. and Cripps P.J. Factors involved in the prognosis of laminitis in the UK. *J Equine Vet*, 1999; 31. 5: 433-443.

Hood D.M., Taylor D. and Wagner I.P. Effects of ground surface deformability, trimming, and shoeing on quasistatic hoof loading patterns in horses. *Am Journ Vet Res*, 2001; 62: 895-900.

Kummer M, Lischer C., Vargas J. and Hugelshofer J. Evaluation of a standardised radiographic technique of the equine hoof. *Schweizer Archiv f r Tierheilkunde*, 2004; 11: 507-514.

Kummer M, Gayer H., Imboden I., Auer J. and Lischer C. The effect of hoof trimming on radiographic measurement on the front feed of normal warmblood horses. *J Vet*, 2006; 172: 58-66.

Linford, R.L, T.R. O'Brien and D.R. Trout, Qualitative and morphometric radiographic findings in the distal phalanx and digital soft tissue of sound thoroughbred racehorse. *J Am vet Res*, 1993; 54, 38-51.

Quick, C.B and V.T. Rendano, Equine radiology; the pastern and foot. *Modern Veterinary Practice*, 1977; 58, 1022-1027.

Redden, R. Hoof capsule distortion: understanding the mechanisms as a basis for rational management. *The veterinary clinics of North America Equine Practice*, 2003; 19, 443-462.

Rendano, V.T. and B. Grant, The equine third phalanx; its radiographic appearance. *J Am Vet Rad Soc*, 1978; 19, 125-135.

Shahraki, MA. and Vali, R; Hind foot measurements related to hoof balance in Dareh-Shori horses. Online Journal of Veterinary Research; 2015; 19(11): 738-743.

Shively, M.J, Normal radiographic anatomy of the equine digit. *Southwest Veterinarian*, 1977; 30, 193-199.

Stashak, T.S, Laminitis. In: Stashak TD, eds. Adam's lameness in horses. 5th ed. Baltimore, Williams and Wilkins, 2002; 645-664.

Stick, J.A and H.W. Jann, Scott EA, et al. Pedal bone rotation as a prognostic sign in laminitis of horses. *Am Vet Med Ass*, 1982; 180 (3) , 251-253.

Vali, R. and Zakipour, S; Radiographic measurements of hind distal phalanx of Dareh-shori Horses. Online Journal of Veterinary Research, 2015; 19(7): 460-464.