



Study of Relationship Between Aorta Growth and Heart Disease in Broiler and Layer Chickens in Different Ages

Fatemeh Ramezani Nowrozani*

Department of Basic Sciences, Faculty of Veterinary Medicine, Kazerun Branch, Islamic Azad University, Kazerun, Iran

Received: 28/Nov/2020

Revised: 28/Feb/2021

Accepted: 06/Apr/2021

Abstract

Background and aims: producing chickens with high weigh in a short time is the main purpose of the broiler chickens' producers. This rapid body weight gain can cause some disorders in some organs performs like cardiovascular system and it can make these chickens prone to some diseases like cardiovascular failures as well as the sudden death syndrome. So in this study, it was decided to investigate the growth of aorta and its coordination with body gain in broilers and layer chickens.

Materials and Methods: Study was performed on Cobb 500 and Ross 380 as broiler chickens and Leghorn as layer chickens and samples were separated from the descending aorta. after tissue processing and *Hematoxylin* and *eosin* (H&E) *staining*, lumen diameter and the thickness of tunica intima, media and adventitia were measured and compared.

Results: The results showed that in broiler and layer chickens, the tunica media was the thickest layer. This layer showed a decrease in thickness on day 40. On the other hand, on day 40, the broiler chickens revealed more weight compared to the layer chickens, and this weight gain happened very fast, while the growth of vessels, the thickness of the layers, and the aortic diameter in both breeds were almost equal.

Discussion: Thus it can be concluded that with the rapid growth in broiler chickens, birds with smaller cardiovascular and respiratory tracts are formed that it can make them prone to the cardiovascular diseases.

Keywords: *Broiler chickens, Layer chickens, Aorta, Heart disease*

Cite this article as: Ramezani Nowrozani F. Study of relationship between aorta growth and heart disease in broiler and layer chickens in different ages. J Altern Vet Med. 2021; 4(8): 448-458.

*Corresponding Author

Department of Basic Sciences, Faculty of Veterinary Medicine, Kazerun Branch,
Islamic Azad University, Kazerun, Iran.

E-mail: parsroz@yahoo.com , Orcid: <https://orcid.org/0000-0002-9081-9452>

Introduction

Protein is an important substance and can be obtained from animals. Protein sources in Iran are red meat (beef and sheep), white meat (chicken and fish), milk and eggs. Among these, chicken meat is the most consumed meat used by a large group of people. Broiler chickens are the most abundant species of domestic animals and have the most population compared to other species of birds. Ross 308 and Cobb 500 are two broiler strains among chickens that their favorable conversion ratio has introduced them as one of the most suitable meat chickens (Zubair & Leeson, 1996). There are some differences between Ross 308 and Cobb 500 that has mentioned in some studies. A study showed that pectoral muscles showed more growth in Cobb broiler strain while thigh muscles revealed much more growth in Ross (Rahaman *et al.*, 2010).

In a study conducted on the embryo of these two broiler breeders it was seen that embryonic development in the Cobb was faster than Ross and the weight loss up to day 18 in incubation stage in the Cobb was less than Ross (Tona *et al.*, 2010). In another comparison between these two broiler breeders it has been reported that the length, thickness and weight of the pectoral muscles and some other muscles was more in Cobb strain than Ross (Rahman, 2014).

Nowadays companies compete for the production of broiler chickens and in order to attract customers and to sell more products resort to a variation in genetic structure of produced chickens, improving the primary growth rate, food conversion ratio and the quality of broiler carcass. This genetic selection, though leads to an increase in meat production, it can cause some problems such as disorders in cardiovascular system (Olkowski, 2007), the skeletal system (Julian, 2005), and immune system (Parmentier *et al.*, 2010). Unlike considering the traits that are related to the rapid growth, and high efficiency of broiler chicks' breast and thigh meat, the organs as heart and lungs are ignored and due to the lack of conformity of heart and lungs with physiological requirements of other organs, broiler chicks are prone to metabolic and cardiovascular failure (Mansourbahmany *et al.*, 2011). The existence of heart failure in broiler chicks is much more than other groups. Ascites and sudden death syndrome are

also the most prevalent cases in broiler chicks (Olkowski & Classen, 1998; Korte *et al.*, 1999).

Broiler chicks, raised with rapid growth, show more cardiac diseases, revealing much more acute and chronic cardiac failure (Olkowski *et al.*, 1997; Scheele, 1997). A vast number of studies have been carried out on cardiac diseases and the causes of these disorders in broiler chickens (Korte *et al.*, 1999; Martinez-Lemus, 1999; Olkowski *et al.*, 2003; Wu *et al.*, 2003; Wideman, 2001). Also the comparison of broilers and laying chickens has always been considered by scientists. Comparing the broiler and layer chickens has been recognized that the differences between these two strains are in the yolk sac, hormones, fat metabolism and body weight (Buzala *et al.*, 2015). Also it has reported that muscle development and fat tissue is vary in broilers and layer chickens and it is because of differences in the amount of food consumed and the use of the nutrients in these two strains (Buzala & Janicki, 2016).

According to the studies cardiac failure are more in meat chickens than other breeds, and these disorders might be because of the rapid growth of the muscles and insufficient growth of heart arteries. Thus, in the present study, we decided to compare the diameter of the lumen, the thickness of tunica intima, media and adventitia in aorta of broiler and leghorn chickens on days 8, 15, 30 and 40 and investigate the coordination or non-coordination between the growth of the aortic wall with weight gain in these two strains.

Materials and methods

In this study, 96 specimens were selected from three strains, Cobb 500, Ross 380 as broiler chickens and leghorn as layer chickens. Each strain in group of eight on days 8, 15, 30, and 40 were randomly selected from poultry farms in Shiraz. After weighing the chickens, they were euthanized with an overdose of propofol (10 mg/kg). The hearts and aorta were exposed via thoracotomy and heart with the attaching vascular organs was isolated and the samples were separated from the descending aorta. After washing with normal saline, the samples were transferred in 10% formalin solution for

fixation. After tissue processing, Serial transverse sections of 5 μm thickness were cut along the aorta and all sections were stained with *Hematoxylin* and *eosin* (H&E).

In this study, the lumen diameter, and thickness of tunica intima, media and adventitia were measured using a special digital microscope for calculating the histological sections. The image was transferred from microscope on a computer monitor screen through Dyno kitcher software.

The collected data was examined by SPSS statistical package (Version 24.0, SPSS Inc., Chicago, IL, USA) for Windows, and was statistically described in terms of mean \pm standard deviation (\pm SD). To confirm the normality of the data, the Kolmogorov-Smirnov test was used, and to compare the means of the groups, the ANOVA and Kruskal-Wallis variance analysis were used.

Results

According to the Table 1, the process of gaining weight in layer breeds takes place slowly. As it is seen an 8-day chick has a weight is 99.5 g which this value will be 655.9 g for a 40-day chick. In comparison, Cobb 500 and Ross 380, compared to layer chickens show more weight gain in a shorter period of time. On days 8, Cobb 500 has 170 ± 0.06 g weight and it becomes 1920.2 ± 95.01 g on day 40. While from day 8 to 40 weight of Ross 380 changes from 146.5 ± 0.06 into 1712.3 ± 87.09 . In fact, the broiler breeds have gain much weight in a short period of time which this increase has been observed even much more in Cobb 500 in comparison with Ross 380. Thickness of the tunica intima, media and adventitia and lumen diameter of aorta in the leghorn, Cobb 500 and Ross 380 are presented in Tables 2 to 5.

	8 days (gr)	15 days (gr)	30 days (gr)	40 days (gr)
Layer chicken	$99.5 \pm 0.04^*$	$256 \pm 16.87^*$	$486.69 \pm 28.8^*$	$655.9 \pm 26.87^*$
Cobb chickens	$170 \pm 0.06^*$	$643.57 \pm 31.4^*$	$1267.3 \pm 70.3^*$	$1920.2 \pm 95.01^*$
Ross chickens	$146.5 \pm 0.06^*$	$598.72 \pm 28.9^*$	$1165.6 \pm 68.9^*$	$1712.3 \pm 87.09^*$

Table 1. Means and standard deviation of body weight in Layer, Cobb 500 and Ross 380 chicken. *: significant difference between Layer chicken with Cobb chickens and Ross chickens ($P \leq 0.05$).

	8 days (gr)	15 days (gr)	30 days (gr)	40 days (gr)
Layer chicken	$7.91 \pm 1.9^*$	$30.23 \pm 13.66^*$	$26.82 \pm 12.42^*$	$21.60 \pm 14.09^*$
Cobb chickens	$7.49 \pm 2.05^*$	$28.60 \pm 12.70^*$	$21.73 \pm 19.16^*$	$20.86 \pm 13.43^*$
Ross chickens	$8.31 \pm 2.7^*$	$27.94 \pm 12.76^*$	$24.82 \pm 13.42^*$	$20.60 \pm 14.09^*$

Table 2. Means and standard deviation of tunica intima in Layer, Cobb 500 and Ross 380 chickens. *: significant difference of tunica intima in 8 days with 15, 30 and 40 days in layer, Cobb 500 and Ross 380 chickens ($P \leq 0.05$).

	8 days	15 days	30 days	40 days
Layer chickens	417.23± 31.17 [•]	840.3±69.16 [•]	867.13± 72.69 [•]	830.91±16.01 ^{•*}
Cobb 500 chickens	410.36±28.14 [•]	768.21±67.48 ^{•*}	832.16±80.79 [•]	789.20± 15.71 ^{•*}
Ross 380 chickens	420.15±35.20 [•]	837.26±70.15 ^{•*}	854.23± 71.69 [•]	826.90±15.61 [•]

Table 3. means and standard deviation of tunica media in Layer, Cobb 500 and ross 380 chickens. [•]: significant difference of tunica media between 8 days with 15, 30 and 40 days in layer, Cobb 500 and Ross 380 chickens ($P \leq 0.05$). ^{*}: significant differences between different breeds in the same days ($P \leq 0.05$).

According to the tables, the tunica intima in three strains, Cobb 500, Ross 380 and leghorn on day 8 has the lowest value, but on days 15, 30 and 40 shows a considerable increase, which the changes from day 8 to 15, 30, and 40 reveals significant differences ($p \leq 0.5$). However, the difference in this layer from day 15 to 30 and 40 does not show any statistical significant difference. The thickness of this layer on days 8 and 15 among layer chickens are less than Cobb 500 and Ross 380 while on days 30 and 40, the tunica intima thickness in layer chickens is more than Cobb 500 and Ross 380. Moreover, in different ages this layer in Cobb 500 has much more diameter compared to Ross 380. However, this was a small difference and does not depict any statistical significant difference (Table 2 and Figure 1).

The thickness of the tunica media in the layer chickens, Cobb 500 and Ross 380 shows a significant

increase from day 8 to days 15 and 30 but on day 40 the thickness of this layer is less than the one on day 30. These changes from day 8 to days 15, 30 and 40 reveals a significant difference ($P \leq 0.5$) but an increase in this layer on day 15 in comparison to day 30 and a decrease in this layer on day 40 is not significant. Comparing the thickness of this layer in these three breeds, it can be seen that the thickness of tunica media on days 8 and 15 in layer chickens is less than the ones in Cobb 500 and Ross 380, but on days 30 and 40 thickness of this layer in layer chickens is more than Cobb 500 and Ross 380. But this difference is small and insignificant. However only Cobb 500 and Ross 380 on day 15 and the layer chicken and Cobb 500 on day 40 reveal statistical significant differences ($p \leq 0.5$) (Table 3 and Figure 2).

	8 days	15 days	30 days	40 days
Layer chickens	20.19 ± 6.64 [•]	64.94 ± 12.06 [•]	76.39 ± 13.97 [•]	79.15 ± 29.12 [•]
Cobb 500 chickens	17.44 ± 5.52 [•]	67.19 ± 4.37 [•]	67.04 ± 8.65 [•]	69.86 ± 11.11 [•]
Ross 380 chickens	19.65 ± 6.15 [•]	65.34 ± 11.20 [•]	73.54 ± 13.27 [•]	77.28 ± 28.32 [•]

Table 4. Means and standard deviation of tunica adventitia in Layer, Cobb 500 and ross 380 chickens. [•]: significant difference of tunica adventitia in 8 days with 15, 30 and 40 days in layer, Cobb 500 and Ross 380 chickens ($P < 0.05$).

According to Table 4 and Figure 3, the thickness of the tunica adventitia in the leghorn, Cobb 500, and Ross 380 is less on day 8 than on days 15, 30, and 40.

However, a significant different on day 8 is observed compare to the days 15, 30 and 40. ($p \leq 0.5$).

	8 days	15 days	30 days	40 days
Layer chickens	20.19 ± 6.64*	64.94 ± 12.06*	76.39 ± 13.97*	79.15 ± 29.12*
Cobb 500 chickens	17.44 ± 5.52*	67.19 ± 4.37*	67.04 ± 8.65*	69.86 ± 11.11*
Ross 380 chickens	19.65 ± 6.15*	65.34 ± 11.20*	73.54 ± 13.27*	77.28 ± 28.32*

Table 5. Means and standard deviation of lumen in Layer, Cobb 500 and Ross 380 chickens. *: significant difference of lumen in 8 days with 15, 30 and 40 days in layer, Cobb 500 and Ross 380 chickens ($P < 0.05$). *: significant differences between different breeds in the same days ($P < 0.05$).

Comparing the thickness of this layer among these three strains, it can be observed that the thickness of this layer on day 8 in layer chickens is less than those in Cobb 500 and Ross 380 but on days 15, 30, and 40 the diameter of the tunica adventitia in layer chickens is much more than those observed in Cobb 500 and Ross 380. Moreover, this layer in different ages in Cobb 500 has much more diameter compared to Ross 380. However, the observed variations do not reveal any statistically significant differences.

Table 5 and Figure 4 illustrate the diameter of the aorta lumen in layer breeds, Cobb 500 and Ross 380. On days 8, 15, 30 and 40. The diameter of the lumen in the three strains is more on days 15, 30 and 40 than on day 8 and a statistical significant difference can be seen. Comparing the diameter of lumen in these three breeds, it is revealed that the diameter of the lumen in different days in layer chickens has been much more than Cobb 500 and Ross 380. However, these variations are trivial and insignificant. The statistically significant differences are observed only in layer chickens and Ross 380 on days 15 and 40.

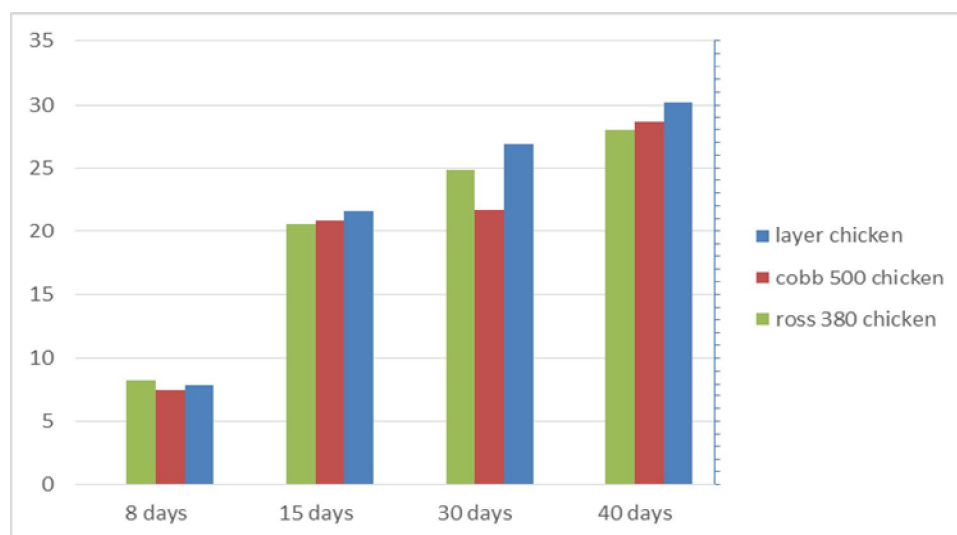


Figure 1. Comparison of tunica intima in layer, Cobb500 and Ross 380 chicken in different days.

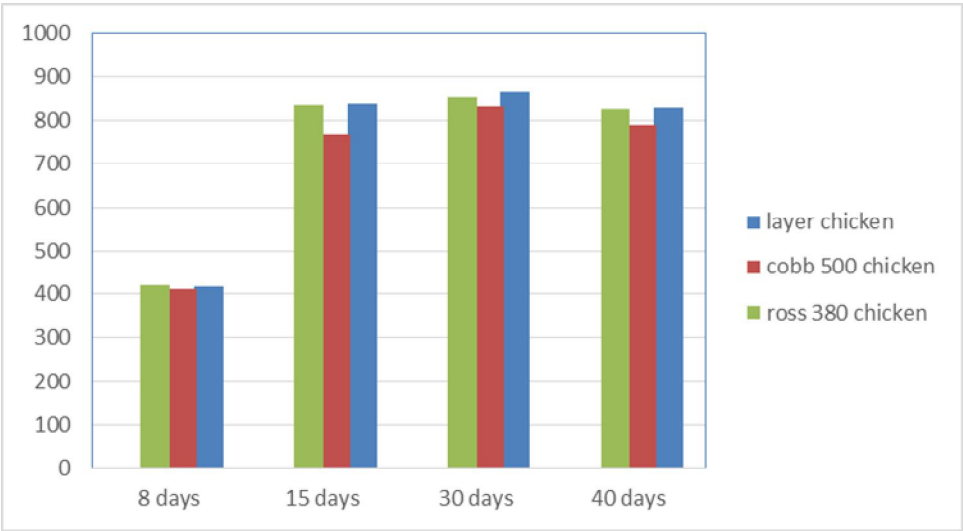


Figure 2. Comparison of tunica media in layer, Cobb500 and Ross 380 chicken in different days.

As depicted in Tables 2 to 4, in different days in all chickens the tunica media has revealed the most

thickness compared to the other layers and the least thickness has been observed in the tunica intima.

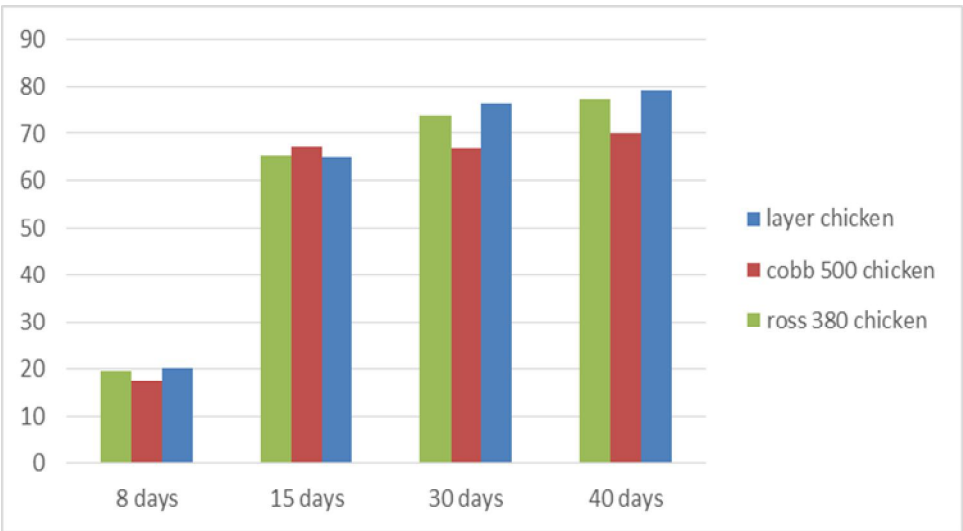


Figure 3. Comparison of tunica adventitia in layer, Cobb500 and Ross 380 chicken in different days.

Discussion

The three arteries wall layers consist of tunica intima, media and adventitia. It is reported these three layers in different arteries in various species like renal artery in pigs, humans aorta, paca, and

Brachiocephalic artery in chicken (Popescu *et al.*, 2013; Popescu *et al.*, 2013; Garcia Filho *et al.*, 2012; Vodenicharov & Cirnuchanov, 1995; Rahmanifar *et al.*, 2012). Aorta in leghorn chickens, Cobb 500 and Ross 380 also show the existence of these three layers.

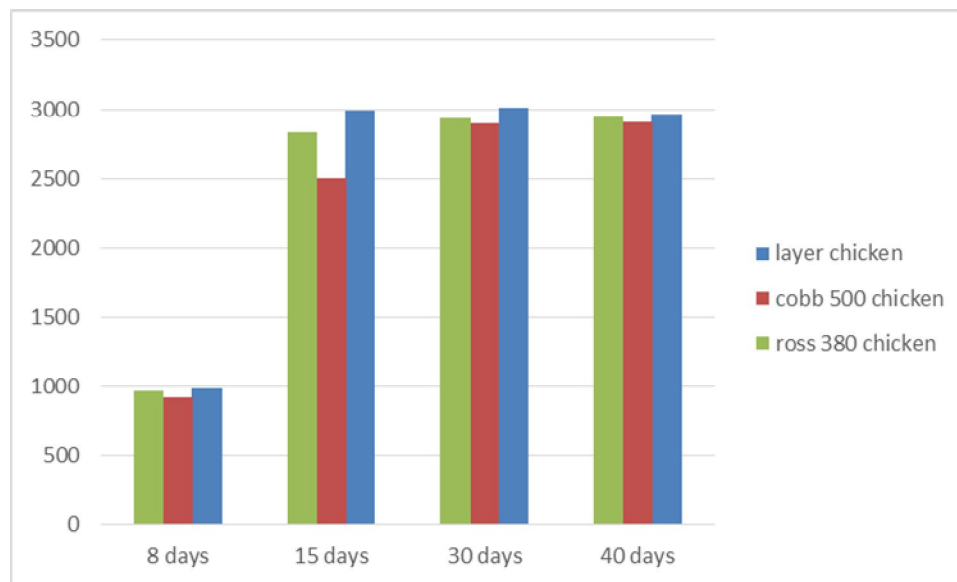


Figure 4. Comparison of lumen in layer, Cobb500 and Ross 380 chicken in different days.

The present research revealed that in Cobb 500, Ross 380 and leghorn tunica intima, media and adventitia had the least thickness on day 8. These three layers showed a considerable increase on days 15, 30, and 40 compared to day 8. This increase can be due to the growth of chicks and increased food requirements and blood volume in adult compared with neonate. Thus with weight gain from day 8 to 15, 30, and 40, the aorta showed growth in both broiler and leghorn chickens but these changes in the aortic wall thickness are less compared to weight gain in broiler chickens than layer chickens. In Cobb 500 and Ross 380 as broiler chickens on days 15, 30 and 40 a significant weight gain can be seen but the aorta growth and the thickness of various layers and aorta lumen was not match weight gain. Whilst this lack of coordination between the growth of aorta and the weight gain in layer chicks is less and it can be because the weight gain is slower in layer chickens than broiler chickens.

In broiler and layer chickens, the tunica media represents the thickest one which is composed of the smooth muscle cells and a large amount of elastic fibers. On the other hand, these fibers and smooth muscle cells play an important role in the consistency of blood pressure and the flow of blood in the aorta.

It is known that during systole the blood enters the large elastic arteries with considerable force and that these arteries distend. They are able to do so

because of the large amount of elastic tissue in their walls. During diastole the arteries return to their original size because of the elastic recoil of the walls. The smooth muscle cells control the blood flow towards the body organs through their contraction and expansion (Junqueira *et al.*, 2005). The thickness of this layer in leghorne, Cobb 500 and Ross 380 increase from the days 8 to 30, but on day 40 it shows less thickness compared to day 30. This reduction in the thickness of tunica media in day 40 can be attributed to a decrease in the elastic fibers caused by aging. In some studies it has been reported that the stiffness of the large arteries at high ages is due to the degradation of the collagen fibers and a decrease in elastic fibers in these vessels (Jerome, 2012). Measuring the thickness of the layers in these three groups, it can be seen that though broiler chickens show much more rapid growth compared to the layer chickens, but the thickness of the layers and the vessel lumen in broiler chickens do not show any significant differences with layer chickens. The tunica intima in layer chicks is thicker than broiler chicks on days 15, 30 and 40 but this difference is not significant. In layer breeds, the tunica media is also less than what seen in Cobb 500 and Ross 380 on days 8 and 15 but on days 30 and 40, the diameter of the tunica media in layer chickens is more than Cobb 500 and Ross 380. As it can be seen, in this age the tunica media of aorta in layer chicks shows greater

thickness compared to what observed in broiler ones. Previous studies have also revealed that the diameter of the left ventricle and the aorta and the thickness of the myocardium in chicks with rapid growth are less (Martinez-Lemus, 1998).

Like the other animals, the sudden death syndrome causes a sudden death in the broiler chickens without any previous signs in the poultries, and the main reason for the occurrence of this syndrome is the heart attack. Researchers and scientists believe that the heart attack happens due to the high stress (Olkowski, 2007; Martinez-Lemus, 1998). Thus the rapid growth in broiler breeds can enhance the chance of heart attack (Nain *et al.*, 2008).

The anatomy and physiology of the cardiovascular and respiratory system of birds may have an important role in the sensitivity of these organs to diseases (Decuypere *et al.*, 2000). It is reported that because of rapid growth in broiler chickens, anatomic and functional changes of the cardiopulmonary system have occurred, making broiler chickens highly susceptible to some diseases (Martinez-Lemus *et al.*, 1999). Acute heart attack is among the main reasons of death in broiler chickens. It is seen that the broiler chickens even in good physical conditions are involved in sudden deaths without any obvious reasons (Olkowski, 2007). One of the reasons for the sudden death syndrome is due to the rapid growth (Greenlees *et al.*, 1989, Korte *et al.*, 1999). Moreover, the rapid growth is a factor that may lead to lack of oxygen (Olkowski *et al.*, 2005) which in turn it can be attributed to the abnormal and fast growth of the body and the growth disorders in the cardiovascular system. It is because the changes in growth in broiler chickens to gain more weight and bigger muscle mass may result in the birds with smaller cardiovascular and respiratory organs (Hassanzadeh *et al.*, 2005). Thus, these defects in the development of heart and cardiac vessels may result in cardiac diseases.

In general, it can be concluded from the findings of this present research that the cardiac failures and diseases in broiler chicks is more than those observed in layer chicks which can be attributed to the rapid growth of the broiler chickens compared to the layer chickens. Compared to the layer chickens, broiler chickens gain more weight in a shorter period of time while the growth and thickness of the tunica intima, media, adventitia and lumen of aorta in both breeds

occur in the same rate. It indicates the disorders in the growth of cardiovascular system which is a factor of cardiac failure in broiler chickens.

References

- Buzala M. and Janicki B. Effects of different growth rates in broiler breeder and layer hens on some productive traits. *Poult Sci*, 2016; 95(9): 2151-2159. doi.org/10.3382/ps/pew173.
- Buzala M., Janicki B. and Czarnecki R. Consequences of different growth rates in broiler breeder and layer hens on embryogenesis, metabolism and metabolic rate: a review. *Poult Sci*, 2015; 94(4): 728-733. doi:10.3382/ps/pev015.
- Decuypere E., Buyse J. and Buys N. Ascites in broiler chickens: exogenous and endogenous structural and functional causal factors. *Worlds Poult Sci J*, 2000; 56(4): 367-376. doi:org/10.1079/WPS20000025.
- Garcia Filho SP., Martins LL., Reis ACG., Pacheco MR. and Machado MRF. Structure, ultrastructure and morphometry of the aorta in the paca (*Cuniculus paca*, Linnaeus, 1766) raised in captivity. *Arq Bras Med Vet Zootec*, 2012; 64(3): 599-605. doi.org/10.1590/S0102-09352012000300011.
- Greenlees KJ., Eyre O., Lee JC. and Larsen TC. Effect of age and growth rate on myocardial irritability in broiler chickens (42861). *Proc Soc Exp Biol Med*, 1989; 190(3): 282-285.
- Hassanzadeh M., Gilanpour H., Charkhkar S., Buyse J. and Decuypere E. Anatomical parameters of cardiopulmonary system in three different lines of chickens: further evidence for involvement in ascites syndrome. *Avian Pathol*, 2005; 34(3): 188-193. doi: 10.1080/03079450500096372.
- Jerome L. Age-associated changes in cardiovascular structure and function: a fertile milieu for future disease. *Heart Fail Rev*, 2012; 17(4-5): 545-554. doi: 10.1007/s10741-011-9270-2.
- Julian RJ. Production and growth related disorders and other metabolic diseases of poultry-A review. *Vet J*, 2005; 169(3): 350-369. doi: 10.1016/j.tvjl.2004.04.015.

- Junqueira LC., Carneiro J. and Kelly RO. Basic histology (text and atlas). 11th ed., McGraw-Hill Medical Pub, New York; 2005.
- Korte SM., Sgoifo A., Ruesink W., Kwakernaak C., van Voorst S., Scheele CW. and Blokhuis HL. High carbon dioxide tension (PCO₂) and the incidence of cardiac arrhythmias in rapidly growing broiler chickens. *Vet Rec*, 1999; 145(2): 40-43.
- Mansourbahmany M., Moravej H., Zaghary M. and Shivazad M. Study of Ascite and Performance in Five Strains of Commercial Broiler. *J animal sci*, 2011; 21(3): 9-20.
- Martinez-Lemus LA., Heste RK., Becker EJ., Jeffrey JS. and Odom TW. Pulmonary artery endothelium-dependent vasodilation is impaired in a chicken model of pulmonary hypertension. *Am J Physiol*, 1999; 277 (1 Pt 2): 190-197.
- Martinez-Lemus LA., Miller MW., Jeffrey JS. and Odom TW. Echocardiographic evaluation of cardiac structure and function in broiler and Leghorn chickens. *Poult Sci*, 1998; 77(7): 1045-1050. doi: 10.1093/ps/77.7.1045.
- Nain S., Ling B., Bandy B., Alcorn J., Wojnarowicz C., Laarveld B, et al. The role of oxidative stress in the development of congestive heart failure in a chicken genotype selected for rapid growth. *Avian Pathol*, 2008; 37(4): 367-73. doi: 10.1080/03079450802179850.
- Olkowski AA. and Classen HL. High incidence of cardiac arrhythmias in broiler chickens. *J Vet Med A*, 1998; 45: 83-91.
- Olkowski AA. Pathophysiology of Heart Failure in Broiler Chickens: Structural, Biochemical, and Molecular Characteristics. *Poult Sci*, 2007; 86(5): 999-1005. doi.org/10.1093/ps/86.5.999.
- Olkowski AA., Abbott J. and Classen HL. Pathogenesis of ascites in broilers raised at low altitude: Etiologic considerations based on echocardiographic findings. *J Vet Med A*, 2005; 52: 166-171. doi: 10.1111/j1439-0442.2005.00706.x.
- Olkowski AA., Classen HL., Riddell C. and Bennett CD. A study of electrocardiographic patterns in a population of commercial broiler chickens. *Vet Res Commun*, 1997; 21: 51-62.
- Olkowski AA., Wojnarowicz C., Rathgeber BM., Abbott JA. and Classen HL. Lesions of the pericardium and their significance in the aetiology of heart failure in broiler chickens. *Res Vet Sci*, 2003; 74(3): 203-211.
- Parmentier HK., de Vries Reilingh G., Freke P., Koopman- schap RE. and Lammers A. Immunological and physiologi- cal differences between layer- and broiler chickens after concur- rent intratracheal administration of lipopolysaccharide and hu- man serum albumin. *Int J Poult Sci*, 2010; 9(6): 574-583. doi: 10.3923/ijps.2010.574.583.
- Popescu MR., Zugun FE., Cojocaru E., Tocan L., Folescu R. and Zamfir CL. Morphometric study of aortic wall parameters evolution in newborn and child. *Rom J Morphol Embryol*, 2013; 54(2): 399-404.
- Rahaman MT., Rahman MS., Hoque MF. and Parvez NH. Age related muscle texture variation between Cobb-500 and Ross broiler strain. *J Bangladesh*, 2010; 8(2): 265-269. doi: 10.3329/jbau.v8i2.7936.
- Rahman MS. Morphological analysis of breast and thigh muscle in different ages of broiler chickens and its carcass characteristics. *Bangl J Vet Med*, 2014; 12(2): 115-120. doi: http://dx.doi.org/10.3329/bjvm.v12i2.21265.
- Rahmanifar F., Firouzi S., Sharafi M., Habibi H. and Gorjizadeh S. Histomorphometric study of the left and right brachiocephalic arteries in different ages of chicken (*Gallus domesticus*). *Comp Clin Pathol*, 2012; 23(2): 393-396. doi: 10.1007/s00580-012-1631-2.
- Scheele CW. Pathological changes in metabolism of poultry related to increasing production levels. *Vet Q*, 1997; 19(3): 127-130. doi.org/10.1080/01652176.1997.9694756.
- Tona K., Onagbesan OM., Kamers B., Everaert N., Bruggeman V. and Decuyper E. Comparison of Cobb and Ross strains in embryo physiology and chick juvenile growth. *Poult Sci*, 2010; 89(8): 1677-1683. doi: https://doi.org/10.3382/ps.2009-00386.
- Vodenicharov A. and Cernuchanov P. Microscopical and ultrastructural studies of the renal artery in domestic swine. *Anat Histol Embryo*, 1995; 24(4): 237-40.
- Wideman RF. Pathophysiology of heart/lung disorders: Pulmonary hypertension syndrome

in broilers. World's Poult Sci, 2001; 57(3): 289-307.
doi: org/10.1079/WPS20010021.

Wu DJ., Lin JA., Chiu YT., Cheng CC., Shyu CL.,
Ueng KC. and Huang CY. Pathological and
biochemical analysis of dilated
cardiomyopathy of broiler chickens-An
Animal mode. Chinese J, 2003; 46(1): 19-26.

Zubair AK. and Leeson S. Compensatory growth in
the broiler chicken: A review. Worlds. Poult
Sci, 1996; 52(2): 189-201.
doi.org/10.1079/WPS19960015.



مطالعه ارتباط بین رشد آئورت و بیماری های قلبی در جوجه های گوشتی و تخم گذار در سنین مختلف

فاطمه رضانی نوروزانی*

گروه علوم پایه، دانشکده دامپزشکی، واحد کازرون، دانشگاه آزاد اسلامی، کازرون، ایران

تاریخ دریافت: ۱۳۹۹/۰۹/۰۸ اصلاح نهایی: ۱۳۹۹/۱۲/۱۰ تاریخ پذیرش: ۱۴۰۰/۰۱/۱۷

چکیده

زمینه و هدف: هدف از تولید جوجه های گوشتی، ایجاد گوشت بیشتر بدون در نظر گرفتن وضعیت سیستم قلبی عروقی می باشد. این ناهماهنگی بین عملکرد قلب و ریه ها با نیازهای فیزیولوژیکی برخی از اندام های دیگر، این جوجه ها را مستعد نارسایی قلبی عروقی و سندرم مرگ ناگهانی می کند. در تحقیق حاضر، آئورت در جوجه های گوشتی و تخم گذار مورد مطالعه قرار گرفت.

مواد و روش ها: نمونه ها از آئورت پایین رونده جدا شده و پس از تهیه اسلاید های بافتی و رنگ آمیزی هماتوکسیلین و اتوزین، قطر لومن و ضخامت لایه داخلی، میانی و خارجی اندازه گیری و مورد مقایسه قرار گرفت.

یافته ها: نتایج نشان داد که در هر دو نژاد، لایه میانی ضخیم ترین لایه را تشکیل می دهد و ضخامت این لایه از روز ۴۰ به بعد کاهش پیدا می کند. در روز ۴۰، جوجه های گوشتی نسبت به جوجه های تخم گذار وزن بیشتری را نشان دادند و این افزایش وزن بسیار سریع اتفاق افتاد، در حالی که رشد عروق، ضخامت لایه ها و قطر آئورت در هر دو نژاد تقریباً برابر بود.

نتیجه گیری: بنابراین می توان نتیجه گرفت که با رشد سریع جوجه های گوشتی، پرندگانی با دستگاه تنفسی و قلبی عروقی کوچکتر شکل می گیرند که می تواند آنها را بیماری های قلبی عروقی مستعد کند.

واژه های کلیدی: جوجه های گوشتی، جوجه های تخم گذار، آئورت، بیماری های قلبی

فاطمه رضانی نوروزانی. مطالعه ارتباط بین رشد آئورت و بیماری های قلبی در جوجه های گوشتی و تخم گذار در سنین مختلف. مجله طب دامپزشکی جایگزین. ۱۴۰۰؛ ۴(۸): ۴۴۸-۴۵۸.