JOAVM
Journal of Alternative Veterinary Medicine
joavm.kazerun.iau.ir

Research Article

Islamic Azad University
Kazerun Branch
Fars, Iran

Protective Effect of Vitamin D3 on Changes of Liver Tissue and Blood Biochemical Parameters in Adult Male Rats Treated with Thioacetamide

Nasrin Pahlavani[1], Arash Payehdar[1], Mehrdad Shariati[1*], Ahmad Mozafar[2]

[1]Department of Biology, Kazerun Branch, Islamic Azad University, Kazerun, Iran
[2]Department of Biology, Shiraz Branch, Islamic Azad University, Shiraz, Iran

Received: 06/Aug/2021 Revised: 01/Nov/2021 Accepted: 16/Nov/2021

Abstract

Background and aim: Vitamin D has recently been shown to not only participate in calcium metabolism but also has antioxidant and anti-inflammatory properties. The aim of this study was to evaluate the protective effect of vitamin D3 on changes of liver tissue, liver transaminases and some blood biochemical parameters in adult male rats treated with thioacetamide.
Materials and Methods: Forty-eight adult male Wistar rats were grouped into 6 groups of 8. The control group did not receive any treatment, but the sham group 0.2 ml of distilled water as the drug solvent, the experimental group 1 (Exp1) 1000 IU/kg vitamin D3, the Exp2 50 mg/kg thioacetamide, the Exp3 500 IU/kg Vitamin D3 and 50 mg/kg thioacetamide and Exp4 1000 IU/kg Vitamin D3 and 50 mg/kg thioacetamide received by orally gavage for 25 days. At the end of the study, body weight, liver weight, serum levels of liver transaminases (ALT, AST and GGT) and blood biochemical parameters (ALP, total protein and albumin) were measured. Also, liver tissues were evaluated histopathologically.
Results: Thioacetamide did not cause significant changes in liver weight and ALP serum levels but caused significant changes in body weight, serum levels of ALT, AST, GGT, albumin and total protein in Exp2, 3 and 4. In Exp3 and 4 degrees of improvement in body weight and serum levels were observed in a dose-dependent manner. In the Exp2 necrosis and severe destruction of liver tissue were observed, but in the Exp3 and 4, improvement in necrosis and cell damage was observed in a dose-dependent manner.
Conclusion: Vitamin D3 at maximum dose (1000 IU/kg) has protective effects on liver tissue and improves liver tissue, serum levels of liver transaminases and blood biochemical parameters and in thioacetamide-treated rats.

Keywords: *Thioacetamide, Vitamin D3, Transaminase, Liver necrosis, Rat*

Cite this article as: Nasrin Pahlavani, Arash Payehdar, Mehrdad Shariati, Ahmad Mozafar. Protective effect of vitamin D3 on changes of liver tissue and blood biochemical parameters in adult male rats treated with thioacetamide. J Altern Vet Med. 2021; 4(10): 560-569.

[Downloaded from joavm.kazerun.iau.ir on 2025-10-17]

[DOR: 20.1001.1.2717378.2021.4.10.2.1]

**** Corresponding Author***
Department of Biology, Kazerun Branch, Islamic Azad University, Kazerun, Iran.
E-mail: mehrdadshariati@hotmail.com, Orcid: https://orcid.org/0000-0001-7360-0208

Introduction

Different chemical compounds are made by humans that exist in the living environment. Most of these compounds are metabolized and detoxified by the liver in the human body. One of these compounds that is widely used in industry is thioacetamide. Thioacetamide with the chemical formula C2H5NS is used as a chemical and organic solvent in the leather, rubber, textile, paper industries and as a fuel stabilizer for the engine (Staňková *et al.,* 2010; Chilakapati *et al.,* 2007). Thioacetamide is a white or colorless powder with a mild odor of mercaptan. It is soluble in water and ethanol and slightly soluble in ether. When thioacetamide is heated, it releases toxic gases, nitrogen oxides and sulfur oxides. Thioacetamide contamination is caused by skin-to-skin contact or by inhalation (PubChem, 2004). It is predictable that thioacetamide can be a carcinogenic compound in humans. Studies show that Thioacetamide can destroy liver cells and induce cirrhosis. Thioacetamide is used to induce cirrhosis and liver fibrosis in animal (rats and mice) model experiments. It is a toxic compound that affects the synthesis of DNA, RNA, protein and glutathione content and ultimately induces intrahepatic changes (Chang *et al.,* 2021).

Thioacetamide is a potent oxidant that is converted by the enzyme CytP4502B in liver cell microsomes to its toxic and active metabolite, thioacetamide-S which attacks membrane proteins and lipids, breaking down proteins and lipid peroxidation, eventually producing free radicals and oxidative stress (Hajovsky *et al.,* 2012). In recent decades, increasing use of drugs, chemicals, and pollution from urban life has put the liver, a vital organ, at serious risk. Currently, cirrhosis and liver fibrosis are global problems and common chemical drugs used to treat these diseases have many side effects (Suh, 2020; Manisalidis *et al.,* 2020).

Vitamin D is a type of fat-soluble vitamin that can be stored in body. Vitamin D is either synthesized in the skin (vitamin D3 (cholecalciferol)) or obtained from food sources (vitamin D3 or vitamin D2 (ergocalciferol)). Vitamins D3 and D2 have no biological activity. Both forms are metabolized in the liver to 25-hydroxyvitamin D (calcidiol) and in the kidneys to the biologically active form known as 1,25-dihydroxyvitamin D (calcitriol), which acts as a steroid-like hormone. The effects of 1,25-dihydroxyvitamin D are mediated by its binding to vitamin D receptors in cells. Renal production of dihydroxyvitamin D is regulated by parathyroid hormone, serum calcium and phosphorus levels, and by fibroblast growth factor-23 (Bjelakovic *et al.,* 2017). New evidence shows that vitamin D has anti-inflammatory, antioxidant and anti-fibrotic effects. Vitamin D has been reported to have beneficial effects on serum levels of oxidative stress and inflammatory factors such as malondialdehyde (Sadat Miryaghobi *et al.,* 2019). Therefore, this study was performed to evaluate the protective effect of vitamin D on liver tissue changes, liver transaminases and some blood biochemical parameters in adult male rats treated with Thioastamide.

Materials and Methods

Animals

In this study, 48 adult, male Wistar rats weighing approximately 190±10 g and approximately 70 to 80 days old were obtained from the animal house of the Kazerun Islamic Azad University and kept in the same center. Before the start of the study, the animals were kept for one week in standard conditions at 22 to 24 ° C, 12 hours of light and 12 hours of darkness and were maintained in these conditions until the end of the study. The animals were kept in polycarbonate cages with a steel mesh roof. Animals' food was a compact food for rats prepared by Pars Livestock and Poultry (Pars Animal Feed Co, Iran) Company. The study period was 25 days and the animals received the same amount of water and food throughout the entire study period without any restrictions. The ethical protocol of this study on working with laboratory animals was approved by the Ethics Committee of the Islamic Azad University, Kazerun Branch.

Animal grouping and protocol

For grouping, the animals were first weighed with a restraint device and using a digital scale with an accuracy of 0.001 g. Rats were divided into 6 groups of 8 randomly as below:

1. Control group: did not receive any medication or solvent for 25 days.
2. Sham group: received 2 ml of distilled water as a drug solvent every day for 25 days by oral gavage.

[Downloaded from joavm.kazerun.iau.ir on 2025-10-17]

[DOR: 20.1001.1.2717378.2021.4.10.2.1]

3. Experimental group 1 (Exp1): received 1000 IU/kg of vitamin D3 every day for 25 days by oral gavage.
4. Experimental group 2 (Exp2): received 50 mg/kg of thioacetamide daily for 25 days by oral gavage.
5. Experimental group 3 (Exp3): received 500 IU/kg of vitamin D3 daily at 9:00 AM and 50 mg/kg of thioacetamide at 5:00 PM for 25 days by oral gavage.
6. Experimental group 4 (Exp4): They received 1000 IU/kg of vitamin D3 daily at 9:00 AM and 50 mg/kg of thioacetamide at 5:00 PM for 25 days by oral gavage (Nourozi & Shariati, 2020).

At the end of the study, the animals were weighed again, then they were anesthetized with ether (Kimia Commercial, Iran) to draw blood and remove liver tissues. By opening the chest, blood samples were taken directly from the left ventricle of the heart using a 2.5 cc syringe. The agglutination process of blood samples was performed at 37 ° C for half an hour. Blood samples were then centrifuged at 5000 rpm for 15 minutes to isolate serum. Serums were kept at -20 ° C until blood parameters were measured. Serum levels of AST, ALT, ALP, GGT, Alb and TP were measured by RA-1000 model auto-analyzer (Technicon, USA) according to the manufacturer's instructions (Pars Azmoun Co, Iran). For histopathological study, liver tissue of all animals was removed and weighed. Tissues were fixed in 10% formalin buffer solution and molded in paraffin after conventional tissue processes. Serial sections of 5 microns were prepared using a microtome device and stained with hematoxylin-eosin (Merck, Germany). Tissue samples were evaluated histo-pathologically using light microscope (Nikon, Japan).

Thioacetamide

Thioacetamide (Merck, Germany) was prepared as a powder and distilled water was used as its solvent. The dose of the drug was selected based on previous studies of 50 mg/kg (Nourozi & Shariati, 2020).

Vitamin D

Vitamin D3 (Banner Pharmacaps, Netherlands) was prepared in the form of tablets and after pulverizing, distilled water was used as a solvent. Vitamin D3 doses of 500 and 1000 IU/kg were selected as minimum and maximum doses, respectively, based on previous studies (Nourozi & Shariati, 2020).

Statistical Analysis

Using SPSS software version 20 (SPSS Inc, Chicago, IL, USA) and by ANOVA test and Tukey post hoc test, data obtained from serum levels of liver transaminases and blood biochemical parameters were compared between control, sham and experimental groups. Data was defined as Mean±SEM and $P<0.05$ was considered as a significant level. The charts were drawn by Ghraphpad software version 5 (GraphPad Prism, Inc., San Diego, CA, USA).

Results

Body weight and liver weight

Graph 1 shows a comparison of mean body weight and liver weight. Body weight (Graph 1A) in Exp2, 3 and 4 showed a significant decrease compared to the control and sham groups ($P<0.05$) but in contrast, in Exp3 and 4 showed a significant increase compared to Exp2 ($p<0.05$). Liver weight (Graph 1B) in Exp1, 2, 3 and 4 were not significantly different compared to control and sham groups ($p <0.05$).

Hepatic transaminases and blood biochemical parameters

Graph 2 shows a comparison of mean serum levels of ALT, AST, GGT, ALP, Alb and TP. Serum levels of ALT, AST and GGT (Charts 2A, 2B, 2C) in Exp2, 3 and 4 showed a significant increase compared to control and sham groups, ($P<0.05$) but in Exp3 and 4 showed a significant decrease compared to Exp2 ($p<0.05$). Serum ALP levels (Graph 2D) in Exp1, 2, 3 and 4 were not significantly different from control and sham groups ($0.05<p$). Serum Alb level (Graph 2E) in Exp2 and 3 showed a significant decrease compared to control and sham groups ($P<0.05$) but in Exp3 and 4 showed a significant increase compared to Exp2 ($p<0.05$). Serum TP level (Graph 2F) in Exp2, 3 and 4 showed a significant decrease compared to control and sham groups ($P<0.05$) but in contrast to Exp3 and 4 showed a significant decrease compared to Exp2 ($p<0.05$).

[Downloaded from joavm.kazerun.iau.ir on 2025-10-17]

[DOR: 20.1001.1.2717378.2021.4.10.2.1]

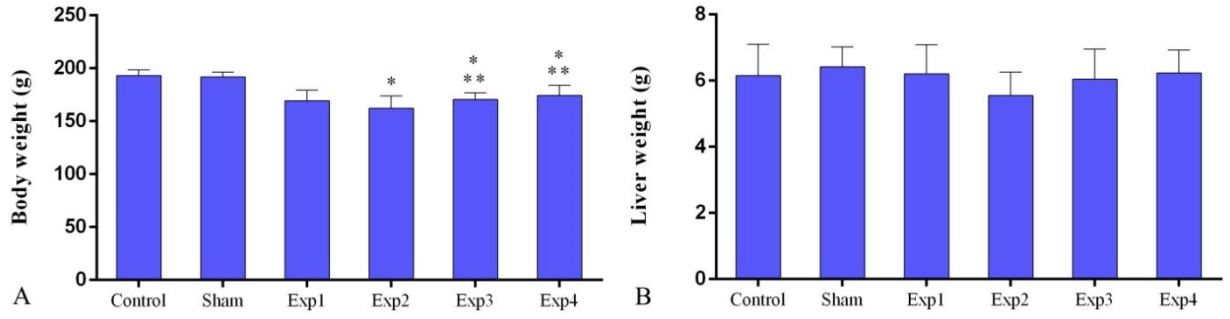

Graph 1. Comparison of mean body weight (A) and liver weight (B) in control, sham and Exp groups. *(p<0.05): Compared with control and sham groups. **(p<0.05): Compared with Exp2.

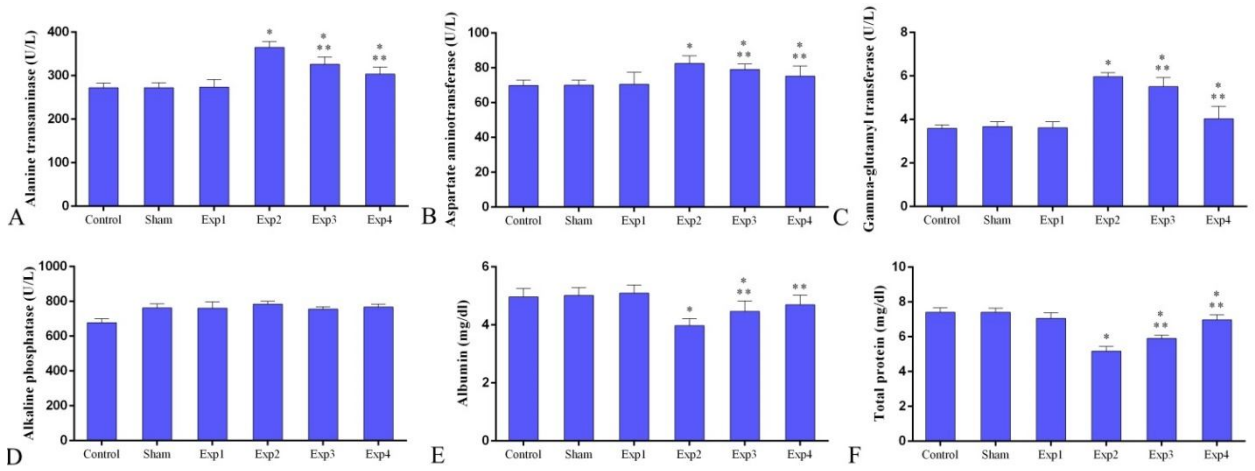

Graph 2. Comparison of mean serum levels of ALT (A), AST (B), GGT (C), ALP (D), Alb (E) and TP (F) in control, sham and experimental groups. *(p<0.05): Compared with control and sham groups. **(p<0.05): Compared with Exp2.

Histopathological findings

The comparison of histopathological findings of the liver between control, sham and Exp groups is shown in Figure 1. In the control group (Figure 1A), sham (Figure 1B) and Exp1 (Figure 1C), liver tissue was normal and no cell damage was observed. In Exp2, compared with the control and sham groups, severe necrosis, local inflammation and cell damage were observed. Liver tissue was disrupted in this group (Figure 1D). In Exp3, local inflammation, acute necrosis and cell damage were observed in comparison with the control and sham groups, and liver tissue was observed abnormally (Figure 1E). In Exp4, compared with control and sham groups, liver tissue destruction, local inflammation and necrosis were mild. Liver tissue appeared somewhat normal (Figure 1F).

[Downloaded from joavm.kazerun.iau.ir on 2025-10-17]

[DOR: 20.1001.1.2717378.2021.4.10.2.1]

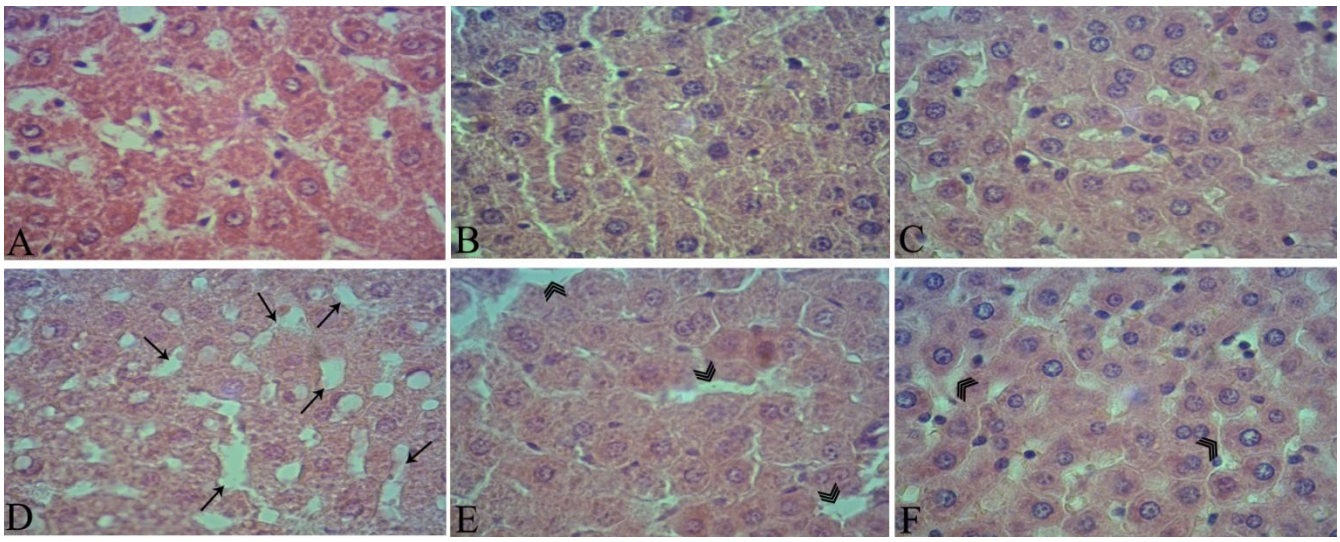

Figure 1. Histopathological comparison of liver between control, sham and experimental groups. In control groups (A), sham (B) and experimental 1 (C) liver tissue is normal and no cell damage is observed. In Exp2 (C) compared to control and sham groups, necrosis (arrows), local inflammation and severe cell damage are observed. Liver tissue damage is severe. Exp3 (E) shows acute necrosis (arrowheads), local inflammation, and cell damage. Liver tissue is abnormal but less damaged than Exp2. In Exp4, compared to Exp2, necrosis (arrowheads), local inflammation and cell damage are mild, and structural changes in liver tissue are minor. Liver tissue is repairing (E&H staining, 40X).

[Downloaded from joavm.kazerun.iau.ir on 2025-10-17]

[DOR: 20.1001.1.2717378.2021.4.10.2.1]

Discussion

In this study, the effects of vitamin D on body weight, liver weight, liver levels of serum ALT, AST, GGT, ALP, Alb and TP as well as histopathological changes of liver in thioacetamide-treated rats were investigated. According to the results of this study, thioacetamide reduced body weight in animals but did not change liver weight. Thioacetamide has been reported to interfere with the biological activity of cells, resulting in disruption of protein synthesis, impaired metabolism of lipids, carbohydrates, and amino acids (Koen *et al.,* 2013; Youniset *et al.,* 2021). Also, thioacetamide reduces the amount of total protein and albumin, so it can explain the reason for the decrease in body weight (Hamad Shareef et al., 2022). Thioacetamide attacks membrane proteins and lipids, causing protein breakdown, lipid peroxidation, and consequently oxidative stress. Among biomolecules, fats are the most damaged by oxidative stress (Sun *et al.,* 2000). Studies show that vitamin D can reduce the expression of genes associated with lipogenesis, which reduces fat synthesis in the liver, suppresses adipose tissue deposition, and ultimately reduces body weight in rats (Kang *et al.,* 2015). Nourozi and Shariati showed that the administration of vitamin D3 at doses of 500 and 1000 IU/kg in male rats treated with thioacetamide had no effect on testicular weight, however, it causes weight loss, which is consistent with the results of this study (Nourozi & Shariati, 2020). Also, Shafei *et al.,* by examining the protective effect of vitamin D3 in male rats treated with lead nitrate, showed that the doses of vitamin D had no effect on testicular weight, which is consistent with the results of this study (Shafiee *et al.,* 2018).

The results of this study showed that vitamin D3 has protective effects on serum levels of ALT, AST, GGT, ALP, Alb and TP as well as liver tissue in thioacetamide-treated rats. Acute doses of toxins and some drugs or long-term use of some substances can produce high amounts of free radicals that overwhelm the antioxidant defense system and cause liver damage (Sepehrinezhad *et al.,* 2021; Sharifi-Rad et al., 2020).

Thioacetamide is metabolized by enzymes in the cytochrome detoxification system upon entry into the body. Metabolism of thioacetamide produces thioacetamide-S oxide and other metabolites. Finally, thioacetamide-S oxide is an intermediate compound in the oxidation steps of thioacetamide by monooxygenases with different functions that cause oxidative stress in liver cells. Also, thioacetamide in high doses causes necrosis and apoptosis of liver cells. On the other hand, thioacetamide free radicals

attack the membrane of liver cells and cause lipid peroxidation, which reduces the fluidity of the membrane and thus changes its permeability, releasing substances and proteins such as albumin entering the plasma from inside the cell (Hajovsky *et al.,* 2012; Türkmen *et al.,* 2022; El-Baz *et al.,* 2019; Zaragoza et al., 2000).

Vitamin D3 is classically recognized as a hormone with important functions to maintain mineral metabolism and musculoskeletal health. It also has antioxidant properties that are as much as or even stronger than the classic antioxidant Vitamin E (Javanbakht *et al.,* 2010; Lee *et al.,* 2018).

In addition, vitamin D3 has been reported to be a potent hormone with important biological functions such as inducing cell differentiation, reducing inflammation, and modulating immunity (Wacker & Holick, 2013).

Studies show that powerful antioxidants such as vitamin D3 improve cell and tissue function by destroying free radicals. The hydroxyl (OH) group of vitaminD3 increases the regenerative power and thus increases the antioxidant power of this substance and protects cells from damage caused by chemical and toxic substances (Souri *et al.,* 2003). Lee et al. report that vitamin D3 increases levels of antioxidant enzymes and suppresses lipid peroxidation, thereby reducing oxidative stress (Lee *et al.,* 2018). Liver damage and inflammation is the first step in liver fibrogenesis. After the activation of fibrogenic cytokines, mainly TGF-β1, liver stellate cells become active myofibroblast-like cells; the accumulation of secreted components of these cells causes fibrosis and progressive cirrhosis. Vitamin D3 has been shown to inhibit fibrogenesis without hypercalcemic properties (Calcipotriol) in a rat model of liver fibrosis. In rats with fibrosis and cirrhosis with CCl4, vitamin D3 supplementation prevented the progression of fibrosis or cirrhosis, suppressed TGF-β1 expression, and increased MMP9 levels in liver tissue (Komolmit *et al.,* 2017).

Nrf2 (Nuclear Factor Erythroid 2-related Factor 2) is one of the regulators of cellular resistance against oxidative stress, which is activated as a defense mechanism against stress-induced damage and activates transcription of various antioxidant elements (Nakai *et al.,* 2014). Vitamin D3 is considered as an activator of Nrf2 and has a regulatory effect against oxidative stress, causing the antioxidant activity of vitamin D in various diseases (Browning and Horton, 2004; Abo El-Magd & Eraky, 2020; Zhang et al., 2020).

Vitamin D3 has been shown to reduce the expression of α-SMA (α-smooth muscle actin) (a functional marker of liver stellate cells) and collagen levels, and to prevent cirrhosis by thioacetamide (Kitson & Roberts, 2012). In addition, vitamin D3 inhibits the expression of inflammatory cytokines such as interleukin-6, TNF-α and interleukin-1 beta by inhibiting adipogenesis and inhibiting NF-κB (Nuclear factor-κB) and increases adiponectin secretion from adipocytes (Miryaghobi *et al.,* 2019). It has been shown that vitamin D3 can be a direct membrane antioxidant by stabilizing and protecting membranes against lipid peroxidation through relationships with their hydrophobic components (Wiseman, 1993; Paprocki *et al.,* 2021; Adelani *et al.,* 2020). Evidence shows that vitamin D3 prevents chronic diseases by regulating oxidative stress in the following ways. It induces the expression of several molecules involved in the antioxidant defense system, including GSH, GSH peroxidase, and SOD, and suppresses the expression of NADPH oxidase. Vitamin D3 can also be similar to a direct membrane antioxidant (Mokhtari *et al.,* 2017).

The limitations of this study include the short duration of the study, the lack of measurement of oxidative and inflammatory factors, the small number of animals studied and the lack of vitamin D3 administration in higher doses.

Conclusion

The results of this study showed that thioacetamide at a dose of 50 mg/kg can alter the serum levels of liver transaminases and blood biochemical parameters in adult male rats by destroying the liver. However, administration of vitamin D3 at the maximum dose (1000 IU/kg) can have protective effects on liver tissue in thioacetamide-treated rats and improve liver tissue, serum levels of liver transaminases and blood biochemical parameters. Therefore, it is recommended that people who are exposed to thioacetamide poisoning use vitamin D3 supplements to reduce the toxic effects of thioacetamide while monitoring their vitamin D levels.

[Downloaded from joavm.kazerun.iau.ir on 2025-10-17]

[DOR: 20.1001.1.2717378.2021.4.10.2.1]

Acknowledgments

The authors would like to thank all the people who helped during this study.

Conflict of interest

There is no conflict.

References

Abo El-Magd NF. and Eraky SM. The molecular mechanism underlining the preventive effect of vitamin D against hepatic and renal acute toxicity through the NrF2/BACH1/HO-1 pathway. Life Sci, 2020; 244: 117331. doi: 10.1016/j.lfs.2020.117331.

Adelani IB., Ogadi EO., Onuzulu C., Rotimi OA., Maduagwu EN. and Rotimi SO. Dietary vitamin D ameliorates hepatic oxidative stress and inflammatory effects of diethylnitrosamine in rats. Heliyon, 2020; 6(9): e04842. doi: 10.1016/j.heliyon.2020.e04842.

Bjelakovic G., Nikolova D., Bjelakovic M. and Gluud C. Vitamin D supplementation for chronic liver diseases in adults. Cochrane Database Syst Rev, 2017;11(11):CD011564. doi: 10.1002/14651858.CD011564.pub2. Update in: Cochrane Database Syst Rev. 2021; 8: CD011564.

Browning JD. and Horton JD. Molecular mediators of hepatic steatosis and liver injury. J Clin Invest, 2004;114(2):147-52.

Chang GR., Lin WL., Lin TC., Liao HJ. and Lu YW. The Ameliorative Effects of Saikosaponin in Thioacetamide-Induced Liver Injury and Non-Alcoholic Fatty Liver Disease in Mice. Int J Mol Sci, 2021; 22(21): 11383. doi: 10.3390/ijms222111383.

Chilakapati J., Korrapati MC., Hill RA., Warbritton A., Latendresse JR. and Mehendale HM. Toxicokinetics and toxicity of thioacetamide sulfoxide: a metabolite of thioacetamide. Toxicology, 2007; 230(2-3): 105-16. doi: 10.1016/j.tox.2006.11.050.

El-Baz FK., Salama AAA. and Hussein RA. Dunaliella salina microalgae oppose thioacetamide-induced hepatic fibrosis in rats. Toxicol Rep, 2019; 7: 36-45. doi: 10.1016/j.toxrep.2019.10.017.

Hajovsky H., Hu G., Koen Y., Sarma D., Cui W., Moore DS., et al. Metabolism and toxicity of thioacetamide and thioacetamide S-oxide in rat hepatocytes. Chem Res Toxicol, 2012; 25(9): 1955-63. doi: 10.1021/tx3002719.

Hamad Shareef S., Abdel Aziz Ibrahim I., Alzahrani AR., Al-Medhtiy MH. and Ameen Abdulla M. Hepatoprotective effects of methanolic extract of green tea against Thioacetamide-Induced liver injury in Sprague Dawley rats. Saudi J Biol Sci, 2022; 29(1): 564-573. doi: 10.1016/j.sjbs.2021.09.023.

Javanbakht M., Keshavarz S., Mirshafiey A., Djalali M., Siassi F., Eshraghian M., et al. The effects of vitamins E and D supplementation on erythrocyte superoxide dismutase and catalase in atopic dermatitis. Iran J Public Health, 2010; 39: 57-63.

Kang EJ., Lee JE., An SM., Lee JH., Kwon HS., Kim BC., et al. The effects of vitamin D3 on lipogenesis in the liver and adipose tissue of pregnant rats. Int J Mol Med, 2015; 36(4): 1151-8. doi: 10.3892/ijmm.2015.2300.

Kitson MT. and Roberts SK. D-livering the message: the importance of vitamin D status in chronic liver disease. J Hepatol, 2012; 57(4): 897-909. doi: 10.1016/j.jhep.2012.04.033.

Koen YM., Sarma D., Hajovsky H., Galeva NA., Williams TD., Staudinger JL., et al. Protein targets of thioacetamide metabolites in rat hepatocytes. Chem Res Toxicol. 2013; 26(4): 564-74. doi: 10.1021/tx400001x.

Komolmit P., Kimtrakool S., Suksawatamnuay S., Thanapirom K., Chattrasophon K., Thaimai P.,et al. Vitamin D supplementation improves serum markers associated with hepatic fibrogenesis in chronic hepatitis C patients: A randomized, double-blind, placebo-controlled study. Sci Rep, 2017; 7(1): 8905. doi: 10.1038/s41598-017-09512-7.

Lee WC., Mokhtar SS., Munisamy S., Yahaya S. and Rasool HGA. Vitamin D status and oxidative

[Downloaded from joavm.kazerun.iau.ir on 2025-10-17]

[DOR: 20.1001.1.2717378.2021.4.10.2.1]

stress in diabetes mellitus. Cell Mol Biol (Noisy le Grand), 2018; 64: 60-69.

Manisalidis I., Stavropoulou E., Stavropoulos A. and Bezirtzoglou E. Environmental and Health Impacts of Air Pollution: A Review. Front Public Health. 2020; 8: 14. doi: 10.3389/fpubh.2020.00014.

Mokhtari Z., Hekmatdoost A. and Nourian M. Antioxidant efficacy of vitamin D. Journal of Parathyroid Disease, 2017; 5(1): 11-16.

Nakai K., Fujii H., Kono K., Goto S., Kitazawa R., Kitazawa S., et al. Vitamin D activates the Nrf2-Keap1 antioxidant pathway and ameliorates nephropathy in diabetic rats. Am J Hypertens, 2014; 27(4): 586-95.

Nourozi A. and Shariati M. Protective Effect of Vitamin D on Spermatogenesis and Testicular Tissue Changes in Adult Rats Treated with Thioacetamide. Aumj, 2020; 9(2): 107-122.

Paprocki J., Sutkowy P., Piechocki J. and Woźniak A. Association between vitamin D supplements, oxidative stress biomarkers, and hyperbaric therapy in patients with sudden sensorineural hearing loss. Oxid Med Cell Longev, 2021; 2021: 8895323. doi: 10.1155/2021/8895323.

PubChem [Internet]. Bethesda (MD): National Library of Medicine (US), National Center for Biotechnology Information; 2004-. PubChem Compound Summary for CID 2723949, Thioacetamide;. Available from: https://pubchem.ncbi.nlm.nih.gov/compound/Thioacetamide

Sadat Miryaghobi F., Nouri M. and Askari G. Effect of Vitamin D Supplement on Nonalcoholic Fatty Liver: A Systematic Review on Randomized Clinical Trials. J Health Syst Res, 2019; 15(3):169-176.

Sepehrinezhad A., Shahbazi A., Sahab Negah S., Joghataei MT. and Larsen FS. Drug-induced-acute liver failure: A critical appraisal of the thioacetamide model for the study of hepatic encephalopathy. Toxicol Rep, 2021; 8: 962-970. doi: 10.1016/j.toxrep.2021.04.011.

Shafiee Sh., Mamhmoodi M. and Shahidi S. Protective effect of vitamin D on spermatogenesis in male rats treated with lead nitrate. Journal of Ardabil University of Medical Sciences, 2018; 17(4): 402-416.

Sharifi-Rad M., Anil Kumar NV., Zucca P., Varoni EM., Dini L., Panzarini E., et al. Lifestyle, Oxidative Stress, and Antioxidants: Back and Forth in the Pathophysiology of Chronic Diseases. Front Physiol, 2020; 11: 694. doi: 10.3389/fphys.2020.00694.

Souri E., Farsam H., Hasani M. and Azimi kheirabadi Z. Evaluation of antioxidant activity of 25 plant seeds used in Iranian folk medicine. JMP, 2003; 4(8): 27-34.

Staňková P., Kučera O., Lotková H., Roušar T., Endlicher R. and Cervinková Z. The toxic effect of thioacetamide on rat liver in vitro. Toxicol In Vitro. 2010; 24(8): 2097-103. doi: 10.1016/j.tiv.2010.06.011.

Suh JI. Drug-induced liver injury. Yeungnam Univ J Med, 2020; 37(1): 2-12. doi: 10.12701/yujm.2019.00297.

Sun F., Hayami S., Ogiri Y., Haruna S., Tanaka K., Yamada Y., et al. Evaluation of oxidative stress basedon lipid hydroperoxide, vitamin C and vitamin E duringapoptosis and necrosis caused by thioacetamide in rat liver. BBA, 2000; 1500(2): 181-185.

Türkmen NB., Yüce H., Taşlıdere A., Şahin Y. and Çiftçi O. The Ameliorate Effects of Nerolidol on Thioacetamide-induced Oxidative Damage in Heart and Kidney Tissue. Turk J Pharm Sci, 2022; 19(1): 1-8. doi: 10.4274/tjps.galenos.2021.30806.

Wacker M. and Holick MF. Vitamin D effects on skeletal and extraskeletal health and the need for supplementation. Nutrients, 2013;5:111-148.

Wiseman H. Vitamin D is a membrane antioxidant. Ability to inhibit iron-dependent lipid peroxidation in liposomes compared to cholesterol, ergosterol and tamoxifen and relevance to anticancer action. FEBS Lett, 1993; 326: 285-8.

[Downloaded from joavm.kazerun.iau.ir on 2025-10-17]

[DOR: 20.1001.1.2717378.2021.4.10.2.1]

Younis NS., Ghanim AMH., Elmorsy MA. and Metwaly HA. Taurine ameliorates thioacetamide induced liver fibrosis in rats via modulation of toll like receptor 4/nuclear factor kappa B signaling pathway. Sci Rep, 2021; 11(1): 12296. doi: 10.1038/s41598-021-91666-6.

Zaragoza A., Andrés D., Sarrión D. and Cascales M. Potentiation of thioacetamide hepatotoxicity by phenobarbital pretreatment in rats. Inducibility of FAD monooxygenase system and age effect. Chem Biol Interact, 2000; 124(2): 87-101. doi: 10.1016/s0009-2797(99)00147-7.

Zhang H., Deng W., Yang Y., Wei .S, Xue L. and Tao S. Pharmaceutic application of vitamin D3 on particle-induced fibrotic effects through induction of Nrf2 signals. Toxicol Res (Camb), 2020; 9(1): 55-66. doi: 10.1093/toxres/tfaa003.

[Downloaded from joavm.kazerun.iau.ir on 2025-10-17]

[DOR: 20.1001.1.2717378.2021.4.10.2.1]

مجله طب دامپزشکی جایگزین | پاییز ۱۴۰۰ |دوره ۴ | شماره ۱۰

مقاله پژوهشی

JOAVM
Journal of
Alternative Veterinary Medicine
joavm.kazerun.iau.ir

Islamic Azad University
Kazerun Branch
Fars, Iran

بررسی تاثیر حفاظتی ویتامین D3 بر تغییرات بافت کبد و برخی پارامترهای بیوشیمیایی خون در موشهای صحرایی نر بالغ تیمار شده با تیواستامید

نسرین پهلوانی[۱]، آرش پایه دار[۱]، مهرداد شریعتی[۱*]، احمد مظفر[۲]

[۱]گروه زیست شناسی، واحد کازرون، دانشگاه آزاد اسلامی، کازرون، ایران

[۲]گروه زیست شناسی، واحد شیراز، دانشگاه آزاد اسلامی، شیراز، ایران

تاریخ دریافت: ۱۴۰۰/۰۵/۱۵ اصلاح نهایی: ۱۴۰۰/۰۸/۱۰ تاریخ پذیرش: ۱۴۰۰/۰۸/۲۵

چکیده

زمینه و هدف: اخیرا مشخص شده است که ویتامین دی نه تنها در متابولیسم کلسیم شرکت می‌کند بلکه دارای ویژگیهای آنتی اکسیدانی و ضدالتهابی نیز می‌باشد. بنابراین این پژوهش با هدف بررسی تاثیر حفاظتی ویتامین D3 بر تغییرات بافت کبد، ترانس آمینازهای کبدی و برخی پارامترهای بیوشیمیایی خون در موشهای صحرایی نر بالغ تیمار شده با تیواستامید انجام گرفت.

مواد و روش‌ها: ۴۸ موش صحرایی نر بالغ از نژاد ویستار به۶ گروه ۸تایی گروه‌بندی شدند. گروه کنترل هیچگونه تیماری دریافت نکرد اما گروه شم ۰/۲ میلی‌لیتر آب مقطر بعنوان حلال دارو، گروه تجربی ۱ IU/kg ۱۰۰۰ ویتامین D3، گروه تجربی ۲ ۵۰mg/kg تیواستامید، گروه تجربی ۳ IU/kg ۵۰۰ ویتامین-D3 و ۵۰ mg/kg تیواستامید، گروه تجربی ۴ IU/kg ۱۰۰۰ ویتامین D3 و ۵۰ mg/kg تیواستامید بصورت گاواژ دهانی به مدت ۲۵ روز دریافت نمودند. در انتهای مطالعه وزن بدن، وزن کبد، سطوح سرمی ترانس آمینازهای کبدی (ALT،AST و GGT) و پارامترهای بیوشیمیایی خون (ALP، پروتیین تام و آلبومین) اندازه‌گیری شدند. همچنین، بافتهای کبدی مورد بررسی هیستوپاتولوژیک قرار گرفتند.

یافته‌ها: تیواستامید تغییر معناداری در وزن کبد و سطح سرمی ALP ایجاد نکرد اما موجب تغییرات معنادار در وزن بدن، سطوح سرمی ALT، AST، GGT، آلبومین و پروتیین تام در گروه‌های تجربی ۲، ۳ و ۴ گردید با این حال در گروه‌های تجربی ۳ و ۴ درجاتی از بهبودی در وزن بدن و سطوح سرمی بصورت وابسته به دوز مشاهده گردید. در گروه تجربی ۲ نکروز و تخریب شدید بافت کبدی مشاهده گردید اما در گروه‌های تجربی ۳ و ۴ بهبود در نکروز و آسیب سلولی بصورت وابسته به دوز مشاهده گردید.

نتیجه‌گیری: ویتامین D3 در دوز حداکثر (IU/kg ۱۰۰۰) دارای اثرات حفاظتی بر بافت کبد است و موجب بهبود بافت کبد، سطوح سرمی ترانس آمینازهای کبدی و پارامترهای بیوشیمیایی خون و در موشهای تیمار شده با تیواستامید می‌شود.

واژه‌های کلیدی: *تیواستامید، ویتامین D3، ترانس آمیناز، نکروز کبدی، موش صحرایی*

نسرین پهلوان، آرش پایه دار، مهرداد شریعتی، احمد مظفر. بررسی تاثیر حفاظتی ویتامین D3 بر تغییرات بافت کبد و برخی پارامترهای بیوشیمیایی خون در موشهای صحرایی نر بالغ تیمار شده با تیواستامید. مجله طب دامپزشکی جایگزین. ۱۴۰۰؛ ۴(۱۰): ۵۶۰-۵۶۹.

[Downloaded from joavm.kazerun.iau.ir on 2025-10-17]

[DOR: 20.1001.1.2717378.2021.4.10.2.1]

* *نویسنده مسئول: گروه زیست شناسی، واحد کازرون، دانشگاه آزاد اسلامی، کازرون، ایران.*

Orcid: https://orcid.org/0000-0001-7360-0208 ،Email: merdadshariati@hotmail.com